



Arthrex® Presents: NEW TECHNOLOGY UPDATE IN HAND & WRIST SURGERY SUMMER 2015

2015 was another exciting year for Hand & Wrist as we've continued to expand our product portfolio and build on our previous year's successful launch of the Distal Radius Plating System, Compression FT screws, and the CMC Mini TightRope® Implant. This year is marked by continued growth of our portfolio with the soon to be released Fragment Specific plating module housed within the Distal Radius system as well as the new DX SwiveLock SL. Using this new anchor, we developed an exciting new option for treating scapholunate instabilities. Many of these innovative products offer solutions to treat the difficult pathologies seen in Hand & Wrist orthopedics today.

Our Hand & Wrist Medical Education programs continue to expand. With multiple hands-on lab opportunities to learn cutting edge techniques throughout the United States, Arthrex® is training more Hand surgeons than ever before. Surgeon thought leaders instruct courses at our labs in Naples, FL; Miami, FL; Manhattan, NY; Vail, CO; Phoenix, AZ; Los Angeles, CA; and Irvine, CA throughout the year.

With continued focus and expansion our Hand & Wrist portfolio is growing rapidly and will continue to do so for many years to come. We look forward to continuous innovation and growth in this exciting market and hope you will join us to learn more about the highlights of what is happening at Arthrex. Stay tuned for more updates or visit us on our website at www.arthrex.com

RJ Choinski
Senior Product Manager
Arthrex Inc.
Ronald.Choinski@Arthrex.com

Pete Denove
Director, Distal Extremities
Product Management
Arthrex Inc.
Pdenove@arthrex.com



Pictured (left to right): Carolyn Brunner, Michelle Morar, Scott Peterson, Karen Gallen, Todd Earhart, Abigail Freigang, RJ Choinski, Stephanie Bare, Chris Powell, Lindsey Hall, Jerome Gulvas, Michael Karnes, Zachary Day, Adam Garlock and Pete Denove.
Not Pictured: Albert Valdivia, Brittany Foslien and Jake Charles

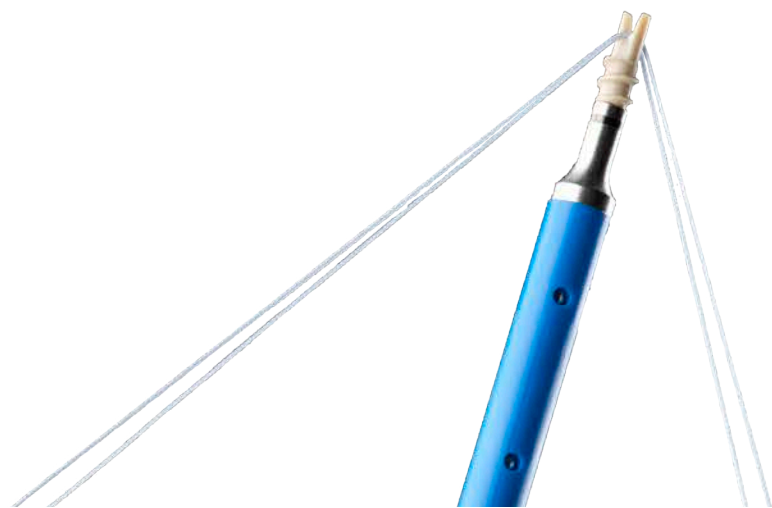3.5 mm SwiveLock® SL

Arthrex is pleased to announce that we are expanding our Hand & Wrist portfolio to include a new knotless suture anchor. The screw-in, knotless SwiveLock offers multiple advantages, such as low profile construct, quick graft insertion through a forked-tipped eyelet, and high pull-out strength. The anchor is available in radiolucent PEEK material.

**Featured
Product**

Among many indications envisioned for this anchor, the 3.5 SwiveLock SL will be a great answer for scapholunate dorsal and interosseous ligament reconstruction. The dorsal reconstruction is simpler than a traditional reconstruction, with an all-knotless, ECRB or Palmaris graft technique. The interosseous procedure uses a Palmaris graft to reassociate the scaphoid and the lunate both in the central and the dorsal portions of the ligament, ensuring solid, anatomic fixation.

The DX SwiveLock SL is 3.5 mm in diameter and 8.5 mm in length and comes with a forked tipped eyelet to facilitate insertion of the graft into a blind tunnel.



IN THIS ISSUE

Scientific Article Spotlight	2 – 3
Anchor Spotlight.	4
What's In My Bag?.	5 – 7
New Products	8 – 9
Surgical Tips and Pearls.	10
Distal Extremities Education.	11



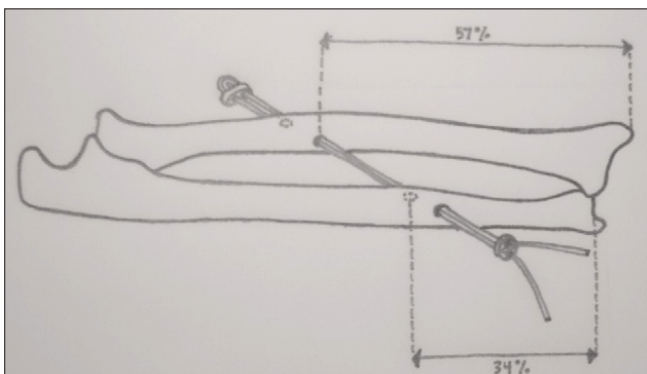
SCIENTIFIC ARTICLE SPOTLIGHT: CMC MINI TIGHTROPE

Mini TightRope® Implant for IOLC Reconstructions

- This study investigated the use of the Mini TightRope to reconstruct the central band of the IOLC in a minimally invasive manner. The goal was to recreate the anatomic position and biomechanical properties of the native central band.
- The rationale for IOLC reconstruction is to recreate the normal loading patterns in the forearm. The IOLC has been shown to transfer some of the radial load at the wrist to the proximal ulna and also maintain transverse stability to prevent splaying of the radius and ulna during forearm compression.

CONCLUSION: "In this cadaveric study, Mini-TightRope IOLC reconstruction with or without a radial head prosthesis significantly reduced distal ulnar impaction forces to that of the native forearm, while limiting radioulnar displacement to near-anatomic levels."


Kam C, Jones C, Fennema J, Latta L, Ouellette A, Evans P. Suture-Button Construct for Interosseous Ligament Reconstruction in Longitudinal Radioulnar Dissociations : A Biomechanical Study. *J Hand Surg.* 2010;35A:1626–1632.



Mini TightRope for CMC Laxity

- "The Mini TightRope technique for CMC laxity without arthritis is a comparatively safer, less invasive, and less aggressive procedure."
- "Minimally invasive technique has smaller wounds and a minimal amount of scar tissue without a donor site."
- "The technique does not burn any bridges in undertaking further surgeries in case the clinical situation worsens or fails to show satisfactory improvement."

Kristo K, Pivato G, Pozzi A, Susini F, Pegoli L. Minimally Invasive Procedure for the Stabilization of the Painful "Prearthritic" Carpometacarpal Joint of the Thumb. *Tech Hand Surg.* 2014 Dec;18(4):194-8. doi: 10.1097



Mini TightRope® Implant and Maintenance of Posttrapeziectomy Space Height

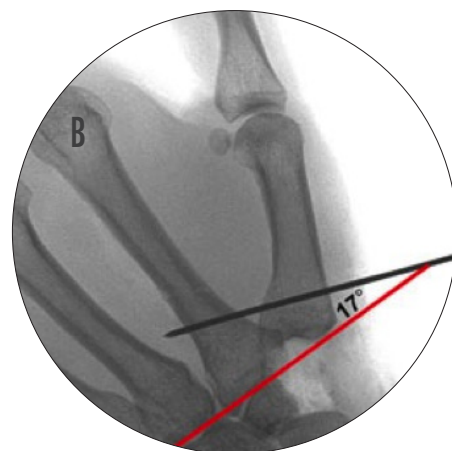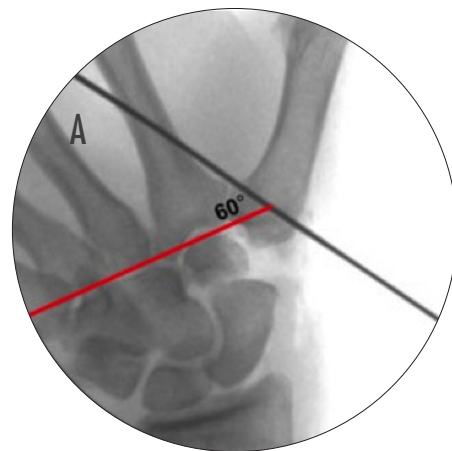
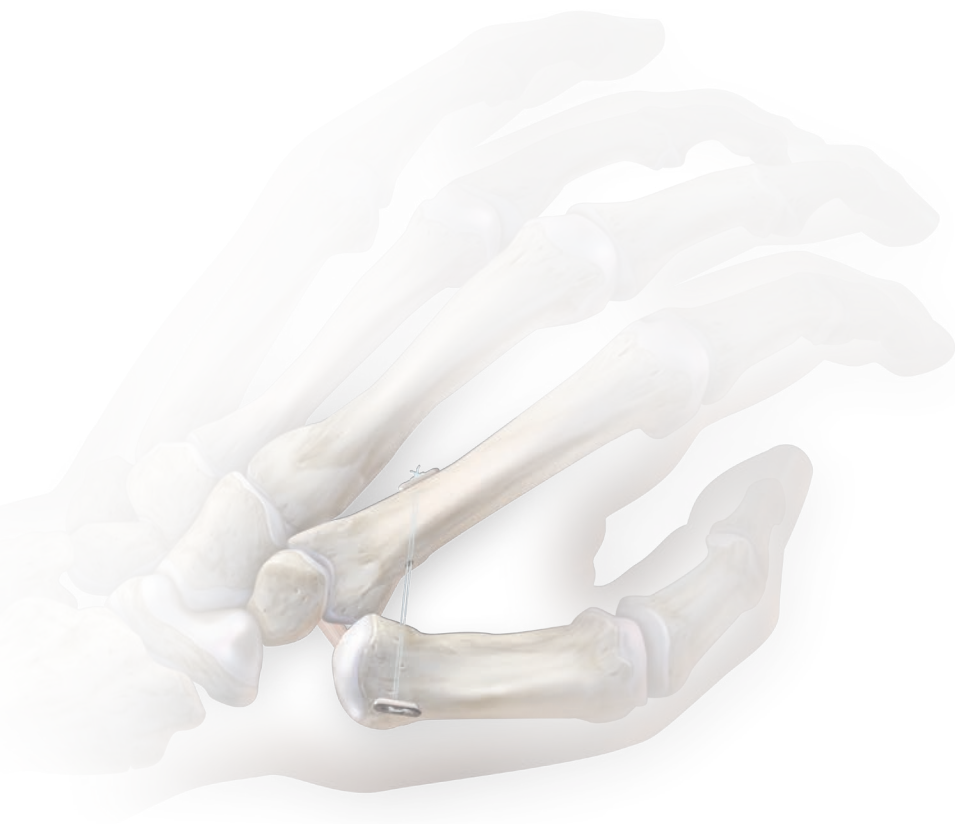- Suture button fixation maintains similar posttrapeziectomy space height and prevents subsidence of the thumb metacarpal when compared to K-wire fixation
- The TightRope may allow for earlier range of motion after the hematoma distraction arthroplasty

Yao J, Zlotolow DA, Murdock R, Christian M. Suture button compared with K-wire fixation for maintenance of posttrapeziectomy space height in a cadaver model of lateral pinch. *J Hand Surg Am.* 2010 Dec;35(12):2061-5.

Trajectory of the Mini TightRope

- Proximal or distal trajectory (defined as either less than 60 degrees from the horizontal or more than 60 from the horizontal, respectively) will yield similar outcomes in range of motion and trapeziectomy space height in a cadaver model
- QuickDASH scores show pinch and grip strength reached 90% of the contralateral limb

Song Y, Cox CA, Yao J. Suture button suspension following trapeziectomy in a cadaver model. *Hand (N Y).* 2013 Jun;8(2):195-200.



ANCHOR SPOTLIGHT

Hand & Wrist Anchors

*Innovation in strength, suture and knotless technology**

- Higher pull-out strength compared to competitors*
- Loaded with 4-0 or 2-0 FiberWire®
- Knotless repair with the Mini PushLock® or SwiveLock® SL
- Titanium, PEEK, or BioComposite™

2.2 x 4 mm Micro Corkscrew FT

2.7 x 7 mm Mini Corkscrew FT

2.4 x 6.5 mm Micro SutureTak®

2.5 x 8 mm Bio-PushLock™

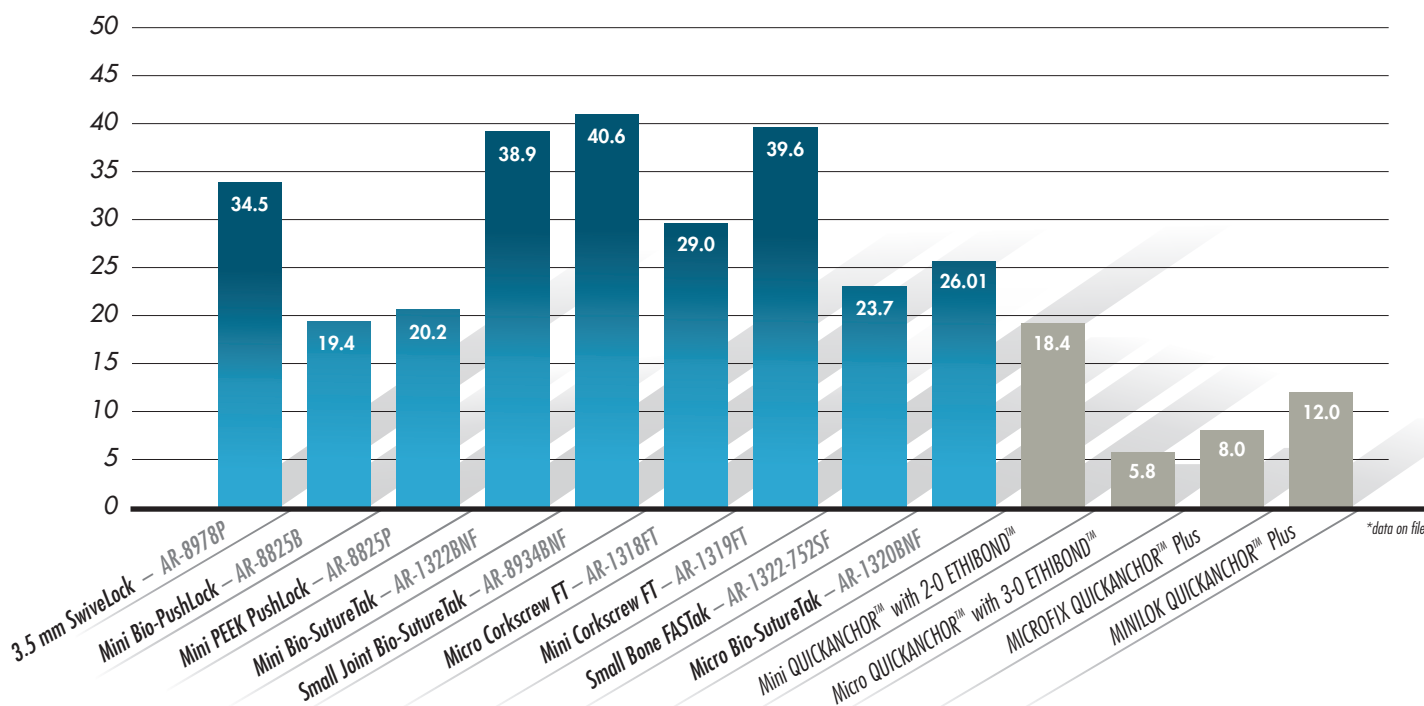
2.5 x 8 mm Mini PEEK PushLock®

3.5 x 8.5 mm DX SwiveLock SL

Pull-out Strength in 30 lb/ft³ (lbf) Ultimate Load*

Arthrex®

Competitor



WHAT'S IN MY BAG?

Small Joint OATS® System



Mohab Food, MD

Q. Can you describe your operating technique for a proximal row carpectomy?

A. Perform a proximal row carpectomy in the standard manner via a dorsal approach taking care to protect the proximal lunate cartilage while removing it. I typically do this under regional anesthesia with an upper arm tourniquet. Dorsal longitudinal incision, transpose EPL, PIN neurectomy. Distally based capsular flap elevated from the radius following the contour of the styloid and splitting the radio-triquetral ligament on the ulnar side. Surgeons choice regarding capsular incision. Remove scaphoid, McGlamory elevator and Arthrex® trapezial removal tool are helpful, remove the lunate taking care to mark the native orientation for later OATS harvest, remove the triquetrum. Evaluate the surface of the capitate to decide if an OATS is required. Proceed with OATS if the proximal pole of the capitate is significantly diseased. Measure the width of the capitate surface that needs to be addressed to help decide on the size of OATS needed. On the back table, hold the lunate with bone forceps, and harvest OATS plug from the lunate with appropriate size harvester. Take care to be perpendicular to the proximal surface of the lunate so that the plug will sit appropriately. Once the plug is harvested, determine the depth of the plug reading on the side of the harvester. Place the guide pin down the axis of the capitate with the wrist in flexion and ream with the matching OATS reamer, stopping at the predetermined depth based on the harvested plug. If the socket is too deep, you can place bone graft in the bottom of the socket harvested from the scaphoid remnants. Trim the plug if needed to make it flush, then deliver it into the capitate noting the orientation of the plug such that the lunate cartilage will sit in the lunate fossa as anatomically as possible. Tap the plug down with the impactor to make it as flush as possible with the remaining capitate edges. Test that the capitate is well reduced in the lunate fossa, and check xray. Check ROM, radial styloidectomy if needed, and debride any dorsal osteophytes from the dorsal rim of the radius if needed. Irrigate, loose capsular closure, retinacular repair, and skin closure per preference. Bulky bandage with short arm splint.

Q. What made you decide to use the OATS system for your proximal row carpectomies?

A. PRC and 4 corner fusion have been shown in study after study to have very similar outcomes. My preference has been to do a PRC in most patients because it is an easier surgery for me, and for them. No hardware, no long immobilization, no non-union risk, hardware irritation etc...I couldn't do a PRC on patients with significant midcarpal disease and would have to do a 4 corner fusion on those patients. Doing the PRC with OATS has allowed me to broaden the indications for PRC to include patients with capitate chondral wear, even when it is quite severe as the lunate fossa and the proximal lunate are almost always preserved. The procedure doesn't take much longer than a standard PRC, is not technically demanding, and still offers the benefits that I like about PRC over 4 corner fusion. Arthrex already had a small joint OATS system that is well designed and easy to use. The sizes are appropriate, and the instrumentation very user friendly. I like to borrow techniques from other fields in orthopaedics and apply them to hand and upper extremity surgery.

Q. Why do you take one larger plug versus the previously described mosaicplasty for resurfacing the capitate?

A. The patients I am using this procedure on do not have a small area of chondral damage on their capitate, it is often the entire proximal surface of the capitate that is sclerotic and eburnated. Using a single plug is technically easier than trying to piece together several small ones. By using one single plug, I can resurface the entire proximal capitate with the cartilage that was made to articulate with the lunate fossa. Some opponents of PRC argue that the capitate doesn't match the lunate fossa, hence it is an inferior option, but doing an OATS from the lunate to the capitate eliminates that argument, as the cartilage perfectly matches the lunate fossa as it did when it was on the lunate itself.

Q. What is your post-op protocol for this procedure?

A. Patients go home in a bulky dressing and short splint. Cryotherapy can be used in the surgical dressing using any one of the available devices on the market if the patient is willing to spend the extra money to have it. I usually have them see hand therapy in 3-5 days to remove their bandages, fit an edema glove, make a wrist splint, and initiate digital range of motion, and limited gentle wrist motion, 20 degree arc is reasonable. They may bathe and remove their splint as desired, but wear it most of the time. They see me in the office at 10-14 days to have their incisions checked, and have initial xrays. At 4 weeks I encourage them to wean use of their brace and progress range of motion, but avoid strenuous use of the wrist until 8-12 weeks depending on comfort level. Improvement continues until about one year post op. This is very similar to what I have seen with PRC without OATS.

*Post op Protocol is patient and surgeon dependent



The views expressed in this handout reflect the experience and the opinions of the presenting surgeons and do not necessarily reflect those of Arthrex, Inc. This is not medical advice and Arthrex recommends that surgeons be trained in the use of any particular product before using it in surgery. A surgeon must always rely on his or her own professional clinical judgment when deciding whether to use a particular product when treating a particular patient. A surgeon must always refer to the package insert, product label and instructions for use before using any Arthrex product. Products may not be available in all markets because product availability is subject to the regulatory approvals and medical practices in individual markets. Please contact your Arthrex representative if you have questions about availability of products in your area.

WHAT'S IN MY BAG?

CMC Mini TightRope® Implant



Mark Dehaan, MD

Q. How long have you been using the Mini TightRope for CMC arthritis?

A. I have been using the Mini TightRope for CMC arthritis since 2011. I have been practicing hand and upper extremity surgery for over 20 years. During that time I have treated numerous patients with basilar thumb joint pain. The procedure of choice over these many years has been ligament reconstruction and tendon interposition with complete trapeziectomy. Over these couple decades many techniques have come and gone as well as implants. The LRTI surgical management for thumb CMC joint pain has given good outcomes. Unfortunately, the concerns of patients have been the protracted recovery time of several months. They have been immobilized after surgery for six weeks, and they have noted residual weakness and some instability. I have searched for an alternative technique to improve their outcome and provide an earlier option for recovery. The Mini TightRope provides these answers for this particular problem from my surgical perspective.

Q. Why do you like using the Mini TightRope for CMC arthritis?

A. It has been my experience with this technique that the recovery time is significantly shorter. Patients are delighted to have the use of their thumb back within 7-10 days for activities of daily living which include writing, eating, using the computer, and light activities. It has also been my experience doing this technique that there is more predictable outcomes with regards to strength and stability of the repair.

Q. What type of patient is the TightRope indicated for?

A. I have used the Mini TightRope for CMC arthritis in all types of patients. This is regardless of age. Our series of patients include ages from 42 to 82 years of age. Both male and female as well as mechanics and factory workers have benefited using this method of surgical management.

Q. How has this changed your post-op protocol?

A. My protocol regarding postop care has not significantly changed over the years I have been doing this procedure. We allow the patients to remove their dressings at 7 to 10 days. We convert them to a thumb-spica forearm splint to be used for comfort. We suggest they use a neoprene thumb wrap for support and protection approximately 4 weeks following the surgical procedure. The thumb-spica forearm splint is only necessary for the first 4 weeks. It is my opinion that this gives time for the joint capsule scar tissue to mature. This also slows down patients because they are anxious to use their thumb and the technique provides significant stability that they tend to actually overuse it because they just do not have the pain they had preoperatively.

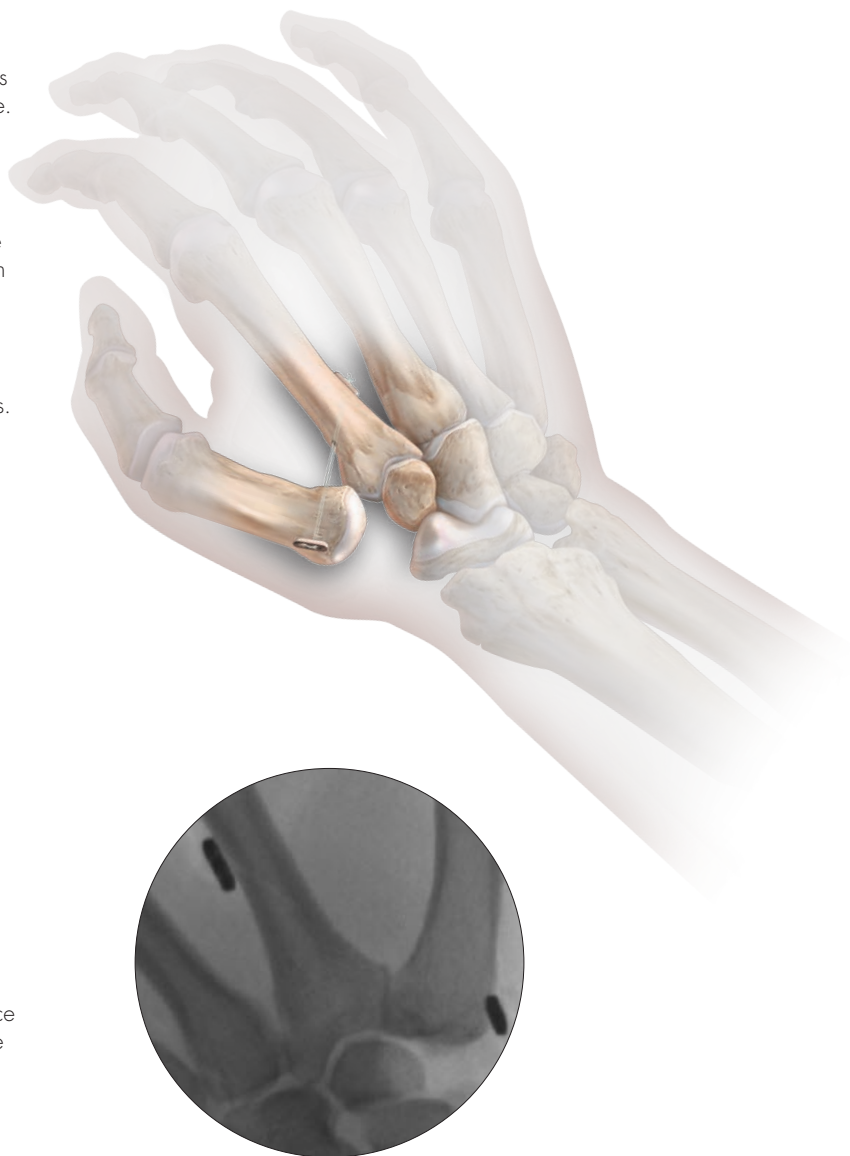Q. How many patients have you performed this procedure on?

A. At this time we have performed approximately 300 CMC arthroplasties using the Mini TightRope procedure. This has been since 2011. There have been very few revisions, and I will continue to use this technique in the future.

Q. Any last comments?

A. The Mini TightRope CMC fixation has become my procedure of choice for symptomatic CMC joint arthritis. The evolution of this procedure over the past 4 years has included adjustments of the incision sites. The tightrope positioning is essential to provide a satisfactory suspension and the need for appropriate tightening and testing using fluoroscopy during the procedure.

It is our impression that the Mini TightRope CMC fixation offers a more predictable surgical outcome with earlier return to activities when compared to the traditional LRTI technique I used in the past.



WHAT'S IN MY BAG?

Dorsal Distal Radius Plate



Chris Martin, MD

Q. What are the advantages of dorsal versus volar plating of the distal radius in your opinion?

A. The dorsal approach allows direct access to and reduction of the articular surface, which is important especially in cases of articular comminution. Direct visualization also prevents the placement of screws into the joint.

Q. For what percentage of distal radius fractures do you use a dorsal plate?

A. The vast majority of distal radius fractures are dorsally displaced and comminuted, and I prefer to approach the radius at the site of maximal displacement and comminution. I use a dorsal plate in roughly 95% of operative distal radius fractures. Additionally I use a dorsal plate for osteotomies because this allows direct access to graft a dorsal opening wedge osteotomy.

Q. Dorsal plating became less popular after early studies demonstrated a risk of extensor tendon rupture. Are you worried about extensor tendon rupture with the use of dorsal distal radius plates?

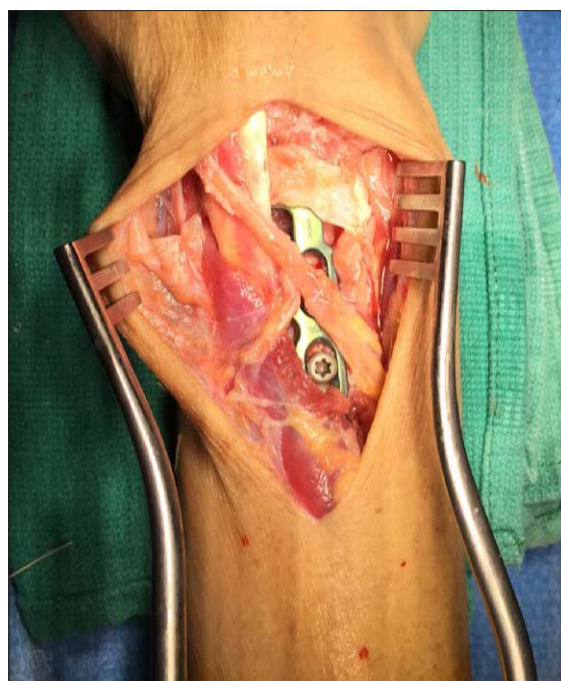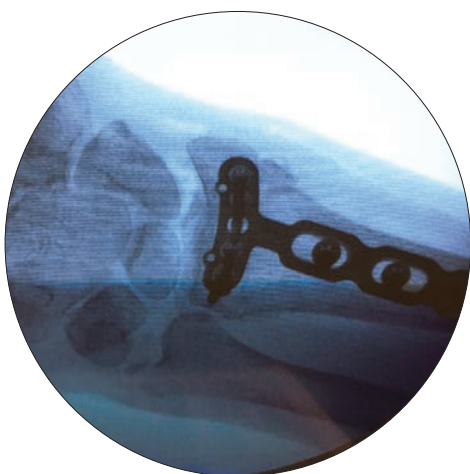

A. Several studies have documented equivalent hardware complications between newer generation dorsal plates and volar plates. For example, Yu et al. (JHandSurg Am 2011, July (36)7, 1135-41) demonstrated no differences between dorsal and volar plating with regard to tendon irritation but reported increased nerve related complications with volar plates. Lower profile plates and surgical techniques utilizing portions of the extensor retinaculum have resulted in very low incidences of tendon difficulties (Beredjikian et al).

Q. Are there any particular advantages of the Arthrex® dorsal plate?

A. The distal contour of the low profile Arthrex plate fits the articular surface and allows placement of parallel screws into the subchondral bone forming a scaffold just beneath the articular surface. This is useful in very distal fractures or in cases of articular comminution. The narrow distal transverse portion of the plate allows for complete covering of the plate with a 1 cm strip of extensor retinaculum, which is useful in minimizing tendon irritation.

Q. What surgical or postoperative techniques have you found useful?

A. I routinely remove Lister's tubercle and leave the EPL superficial to the retinaculum at closure. This facilitates the use of a strip of extensor retinaculum to cover the transverse portion of the plate beneath the extensor tendons. I also splint the wrist at 30 degrees of extension to avoid stretching the extensor tendons against the plate postoperatively.



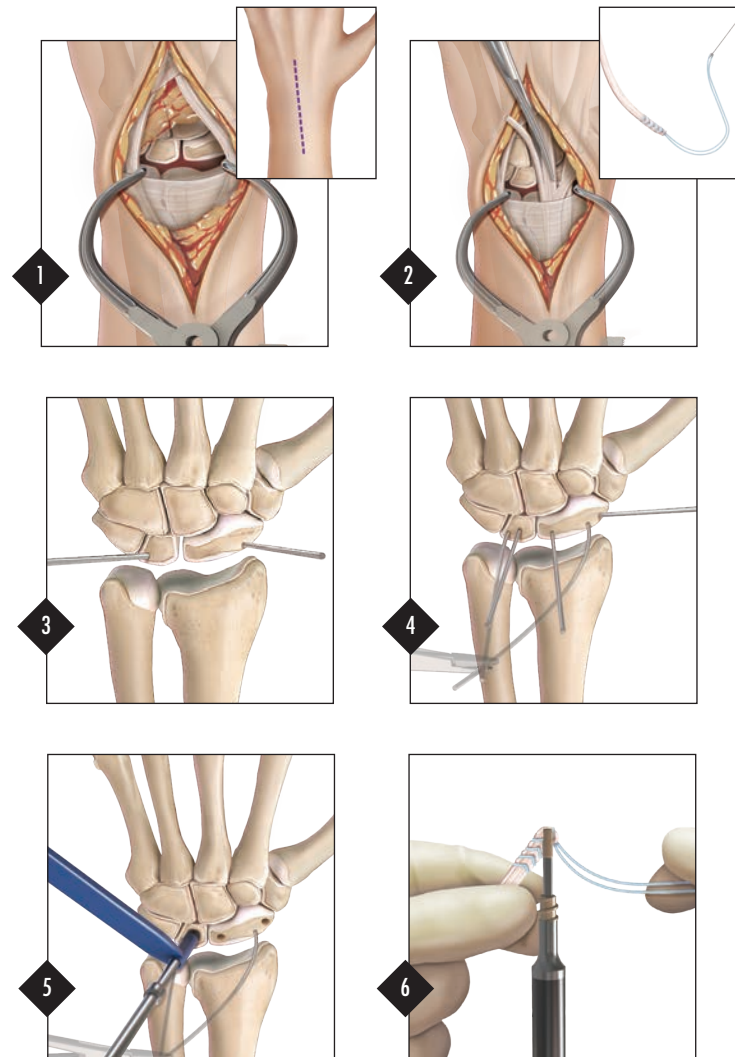
NEW PRODUCTS

3.5 mm SwiveLock® SL

The 3.5 mm Swivelock SL reconstruction is achieved by utilizing an anchor construct that incorporates a combination of a biologic tendon graft reconstruction with static suture reinforcement. Together, this construct supports the connection of and between the bones so that graft incorporation can take place. This reconstruction is best suited for dorsal tears of the SL interosseous ligament.

Abbreviated Surgical Technique

- Step 1:** Make a 4 inch longitudinal incision starting between the bases of the 2nd and 3rd metacarpals and extending proximally between the 3rd and 4th compartments. Expose the scapholunate interval via a dorsal approach with an inverted T capsulotomy. Incise enough capsule to adequately visualize the entire dorsal surface of the lunate and scaphoid bones.
- Step 2:** Harvest a 2-3 mm wide slip of the extensor carpi radialis brevis (ECRB) tendon at its insertion on the base of the 3rd metacarpal. Alternatively, a slip of ECRL can be used. Whipstitch the end of the graft with 2-0 FiberLoop®. This secures the tendon as well as acts as static reinforcement for the repair.
- Step 3:** Place one K-wire into the waist of the scaphoid and one into the ulnar side of the lunate to act as joysticks. A third K-wire can be placed across the scaphocapitate joint at this point or once the reconstruction is complete. This will remain in place for six weeks to allow for healing.
- Step 4:** Place three 0.054 K-wires into the proximal pole of the scaphoid, the distal pole of the scaphoid, and central on the lunate.
- Step 5:** Drill the proximal pole of the scaphoid, the distal pole of the scaphoid, and the central portion of the lunate with the appropriate cannulated drill bit.
- Step 6:** Place the forked eyelet of the Swivelock® SL onto the tendon graft about 3 mm from the end of the graft and secure both limbs of the FiberLoop® into the notch on the Swivelock Tab.



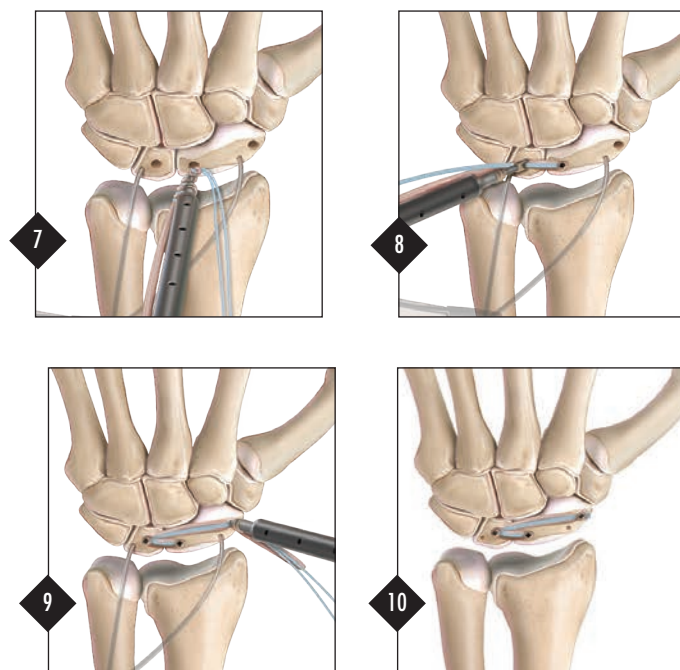
Disposable Kit
SwiveLock SL—AR-8978DS



3.5 mm SwiveLock SL
AR-8978P



- Step 7:** Insert the SwiveLock® SL into the proximal pole of the scaphoid until the leading end of the threaded anchor body is flush to the bone. Apply minimal tension on the graft in the direction of the lunate to keep the graft from spinning while screwing in the SwiveLock. Hold the square tab steady while turning the knob clockwise until the laser line is just below the level of the bone.
- Step 8:** The second SwiveLock SL is used to capture the tendon graft and both limbs of the FiberLoop® in the lunate drill hole.
- Step 9:** Follow the same procedure as in Step 8 for the distal pole of the scaphoid. Cut off any excess tendon graft and FiberLoop. If you haven't previously placed a scaphocapitate K-wire, do so now prior to removing the joystick K-wires. Close the capsule and dorsal incision.
- Step 10:** Final Construct.
- Post-Op:** A forearm-based thumb spica splint is worn for 6-8 weeks. Any supplemental K-wires can be removed and hand therapy is started at this time. The splint is worn for an additional six weeks.



Fragment Specific Plating

In addition to the volar distal radius plate that was launched in 2014, Arthrex® is adding a Fragment Specific Plate module that will drop-in to the existing Wrist Plating set. These plates are a limited availability beta release. Additional plating options include dorsal plates, radial styloid plates, L-plates, and a dorsal spanning plate. This comprehensive offering ensures that the right plate is always available for more complex fractures.



SURGICAL TIPS AND PEARLS


1. Distal Radius Plate Elevator

Designed for malunions or corrective osteotomies, the Plate Elevator allows the surgeon to dial in exactly how many degrees of volar correction he wants to achieve. The Plate Elevator combines the following features:

Cannulated – Keeps the plate from skiving off the bone

Laser marked – Shows how many degrees of correction will be achieved when the shaft of the plate is brought back down to the bone

All-in-one design – All degrees of correction are possible with one elevator



2. Distal Radius Drill Sleeves


Measuring through Drill Sleeves (nubbins) – The standard depth guide can be used to measure through the nubbins. Subtract 8 mm from the length measured to account for the length of the Drill Sleeve.



3. PEEK Aiming Guide

Drill through the attachment screw on the PEEK Aiming Guide –

The attachment screw that secures the PEEK Aiming Guide to the volar Distal Radius Plate is cannulated to accept the 1.7 mm drill used for the distal 2.4 mm screws. This eliminates the step of taking off the Aiming Guide, screwing in the Locking Tower, and drilling. The standard depth guide can then be used through the PEEK Aiming Guide (and subtract 6 mm) or the Guide can be removed and the length read through the plate.



DISTAL EXTREMITIES EDUCATION

We have had significant changes in our Medical Education Department and Distal Extremities Division this past year. Christopher Adams, M.D., our new Director of Medical Education, joined Arthrex in August of 2014. Dr. Adams trained as an orthopaedic surgeon at the Mayo Clinic in Rochester, MN. He then completed a Shoulder Fellowship at the San Antonio Orthopaedic Group under Stephen Burkhart, M.D. He built a very successful private practice in shoulder surgery for 8 years in Jupiter, FL before coming on board to steer the educational team for Arthrex. Jamie Bradshaw, PA-C got promoted to a managerial level. Jamie is now in charge of our Technology Consultant educational programs. He had a great four and a half year ride with DEX MedEd. We also hired Michelle Charget, M.D. as an Associate Clinical Specialist to further drive additional DEX educational offerings. Lorena Reyes, our DEX MedEd coordinator, relocated after doing a fantastic job for the last four years.

As part of our large courses, we had a Hand & Wrist symposium in Seattle. We assembled a great Faculty group with renowned surgeons to instruct around 30 Hand & Wrist surgeons. We had to increase our number of Hand & Wrist courses in the past year due to the high demand from across the country. We have assigned a good number of the courses to our headquarters in Naples, and at our off-site training locations (NYC, Miami, Phoenix, Vail, Los Angeles, and Irvine) to fulfill this demand. Similarly, we have noticed an increase in the number of single-day surgeon visits to Naples to get trained on the safe and effective use of our techniques by our Medical Education experts.

We will have an instructed workshop at the upcoming ASSH Annual Meeting in Seattle with the opportunity to practice some of the latest cutting edge techniques on sawbones. We also are going to hold advanced hand, wrist and elbow courses in Los Angeles on September 19 and in Naples on October 16 and 17. Our North American Hand & Wrist Fellows course on May 15 and 16 of 2015 in Naples, FL had almost 60 Fellows in attendance. This same event will be held in Naples on May 13 and 14 of 2016.

ArthroParis, one of the ArthroSeries events (Arthrex's largest international educational events), was held with tremendous success at the CNIT on June 27 and 28 of 2014. The Distal Extremities program was planned and executed to showcase all of our open and arthroscopic techniques for Hand & Wrist and Foot & Ankle to almost 200 surgeons in attendance. We had a total of 21 live cadaveric demonstrations during the Distal Extremities sessions.

We want to take this opportunity again to extend our gratitude to all of our DEX Consultants and Surgeon Instructors from our Educational Force for such an amazing job during 2013 and 2014.

Felix Riano, M.D.
Medical Education Manager
Distal Extremities, Orthopaedic Trauma and OrthoBiologics

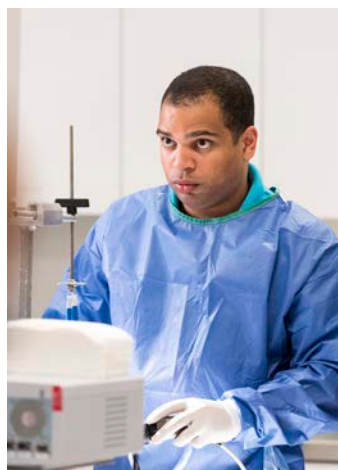Christopher Adams, M.D.
Director of Medical Education
Diplomate of the ABOS

Remainder of 2015 Course Schedule

ASSH Scapholunate Workshop	09/10	Seattle, WA
Hand & Wrist Course	09/19	Los Angeles, CA
Advanced Hand & Wrist Symposium	10/16 - 10/17	Naples, FL
Advanced Hand, Wrist & Elbow Course	12-11 - 12/12	Naples, FL



Hand & Wrist Fellows Forum 2015



National Sales Meeting 2013

Product Development Team

Pete Denove Director of Product Management
Karen Gallen Director of Engineering
Carolyn Brunner Senior Administrative Assistant

RJ Choinski Senior Product Manager
Abigail Freigang Product Manager
Chris Powell Senior Product Manager
Lindsey Hall Product Manager
Michael Karnes Senior Product Manager
Zack Day Product Manager
Todd Earhart Product Manager
Albert Valdivia Associate Product Manager

Michelle Morar Senior Project Engineer
Scott Peterson Senior Engineer
Brittany Foslien Project Engineer
Stephanie Bare Project Engineer
Adam Garlock Engineer
Jerome Gulvas Senior Designer
Jake Charles Designer

Wrist Plating System

The Arthrex Wrist Plating System provides a comprehensive solution for distal radius fracture management

Anatomic


Developed to anatomically reduce the distal radius and provide a low profile repair

Comprehensive

Comprehensive plate selection, multiple screw options, complete instrumentation

Options

Multiple fixed and /or variable angle fixation options tailored to surgeons preference and reduction needs.



Wrist Plating System AR-8916S

Arthrex

www.Arthrex.com

© 2014, Arthrex Inc. All rights reserved.

AD1-0066-EN_A