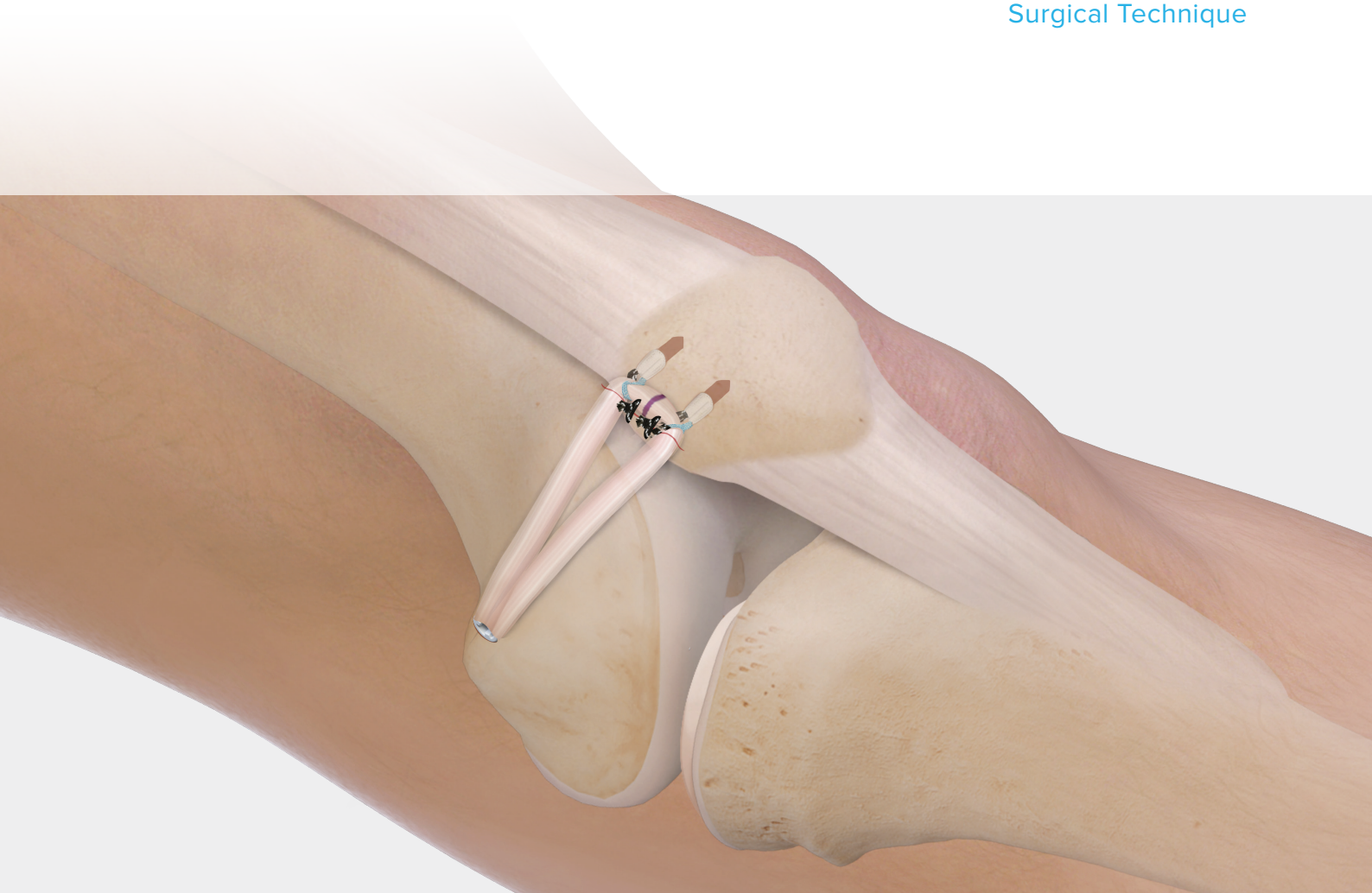

MPFL Reconstruction With Knee FiberTak[®] Anchors and a BioComposite FastThread[™] Interference Screw

Surgical Technique



The medial patellofemoral complex, consisting of the medial patellofemoral ligament (MPFL) and the medial patellotibial ligament, is the main passive stabilizer of the patellofemoral joint. Since it has been shown that MPFL rupture is the primary pathological consequence of patellar dislocation¹ and biomechanical studies have demonstrated that the MPFL is an important passive restraint against patellofemoral instability (PFI) and lateral patellar displacement, MPFL reconstruction has become a widely accepted technique for restoration of patellofemoral stability. Therefore, numerous techniques for MPFL reconstruction have been described with promising clinical results.² Because a nonanatomic MPFL reconstruction can lead to nonphysiologic patellofemoral loads and kinematics,³ the goal of surgical intervention must be an anatomic reconstruction.

Multiple studies have evaluated the femoral insertion of the MPFL. Based on these anatomic,¹ biomechanical,⁴ and radiologic⁵ findings, it is now possible to avoid the complications of increased patellofemoral pressure that are associated with nonanatomic (too anterior/proximal)³ fixation of the graft.

The anatomic double-bundle MPFL reconstruction technique replicates the native shape of the MPFL, provides outstanding flexion and extension, and effectively limits rotation throughout the range of motion (ROM), minimizing postoperative instability. The technique, if accomplished directly and anatomically, may also provide for more aggressive rehabilitation protocols and earlier return to activity.⁶

As mentioned above, an important determinant of a successful outcome of MPFL reconstruction is the proper position of the femoral fixation of the graft, and the technique incorporates the use of a femoral template to ensure proper placement of the graft in the femur. This position provides a static fixation point that equalizes the tension across the graft in flexion and extension, thus minimizing the stresses across the patellofemoral joint.

Pathomorphology of PFI Overview

The pathomorphology of PFI is dependent on different static and passive factors, such as lower-limb alignment, trochlear dysplasia, and MPFL functionality. The patella is primarily stabilized by the MPFL from full extension to approximately 20° of flexion and has no bony guidance, thus forcing the MPFL complex to bear the load of restraint against the lateralizing vector of the quadriceps muscle.

At about 20° of flexion, the patella should engage into the trochlear groove, where the lateral trochlear facet is providing the static stabilization against patellar lateralization. The trochlea provides stability up to 60° to 70° of flexion, where the patella begins engaging into the notch. In cases of trochlear dysplasia, the patella cannot be guided properly, and dislocation of the patella is more common.

Very seldom, there are cases in which the patella does not engage the notch in greater than 70° of flexion, and instability occurs. This can happen in cases of a valgus deformity or internal rotation of the distal femur where the trochlear groove and the notch are positioned medially and the patella cannot engage. Chronic patellar dislocation is often seen in these cases with the patella tracking on the lateral condyle during the entire ROM. In such cases, a realignment procedure should be considered.

Application for MPFL Reconstruction

Since most cases of patellar instability occur in extension or slight flexion with a slight underlying trochlear dysplasia, the majority can be treated with a reconstruction of the MPFL.

In almost all cases, the MPFL is ruptured after an acute patellar dislocation and is additionally weakened in cases of congenital trochlear dysplasia since the patella tracks improperly from early childhood. The additional stresses and tension on the medial soft-tissue complex from this maltracking can lead to an underdeveloped or insufficient MPFL and subsequent instability. Also, in cases with a PFI in deeper flexion, MPFL reconstruction should be considered as a concomitant procedure to provide stability in extension.

Atraumatic Tendon Harvester (AR-10300)

The atraumatic tendon harvester facilitates minimally invasive harvesting from an anterior or a posterior incision. The smooth edge bluntly dissects the tendon off the muscle to decrease the amount of muscle removed, which may lessen the time needed to prepare the graft and lead to reduced patient morbidity.



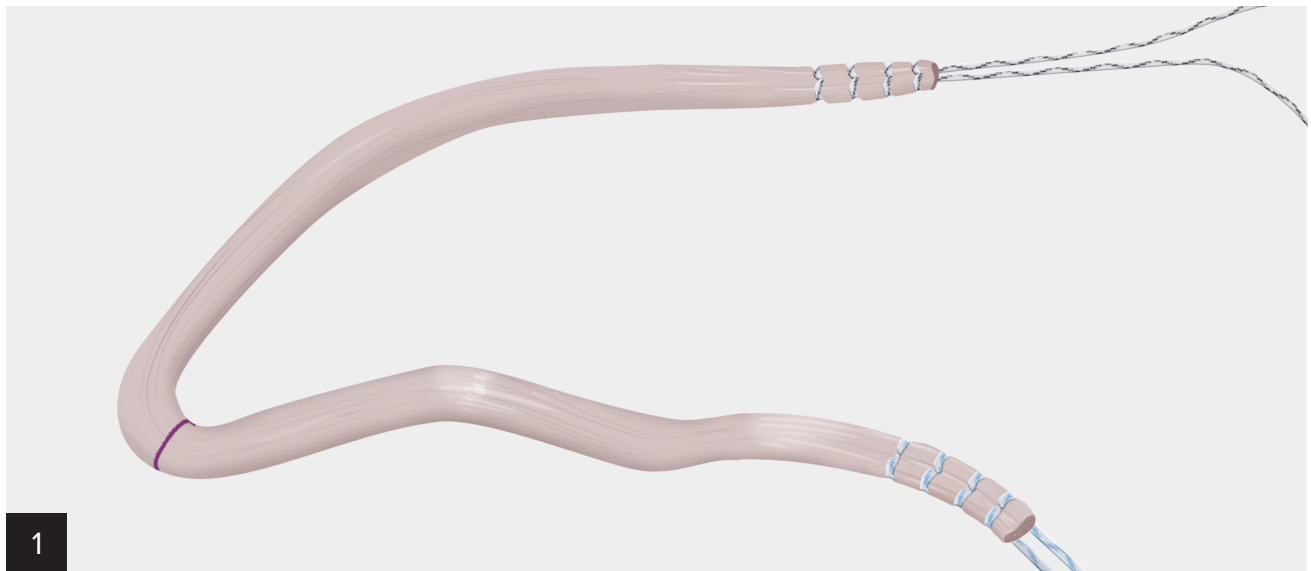
Blunt Edge:

- May reduce premature amputation
- Bluntly dissects the tendon off muscle, which decreases the amount of muscle removed and may lead to reduced morbidity compared to cutting
- Less muscle on the harvested tendon may reduce graft preparation time

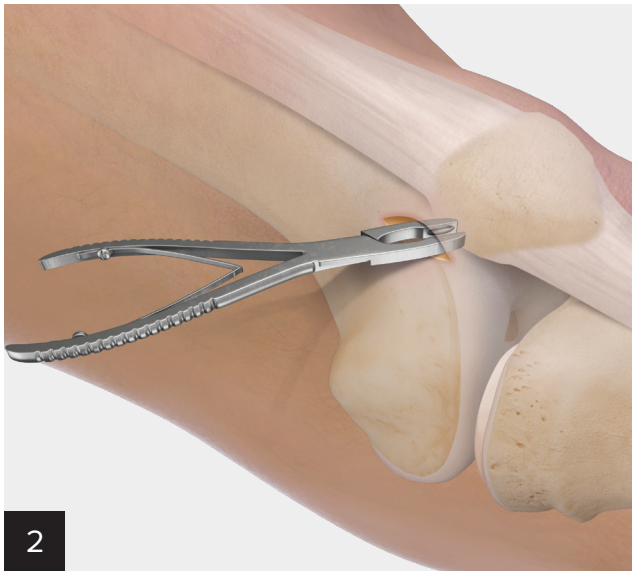Opening/Closing Tip:

- Facilitates loading of tendons into the harvester
- Secures the tendon in the closed tip
- Allows the distal hamstring to remain attached to the tibia if desired

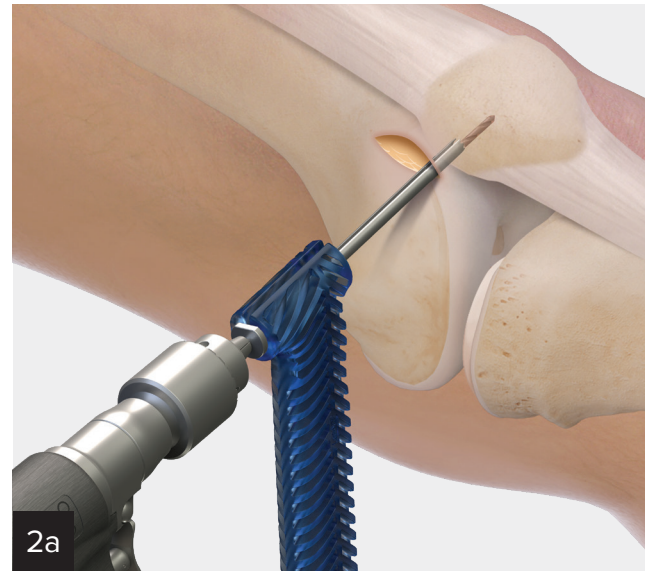
Surgical Technique



Graft Selection: A gracilis autograft is used as the size (approximately 4 mm diameter) and strength have been shown to be sufficient for MPFL reconstruction.⁶ Minimum graft length is 18 cm. Whipstitch 10 mm at each end with a SutureTape, FiberLoop®, or FiberWire® with FiberLoop suture. It can be helpful to mark the graft at the midpoint.



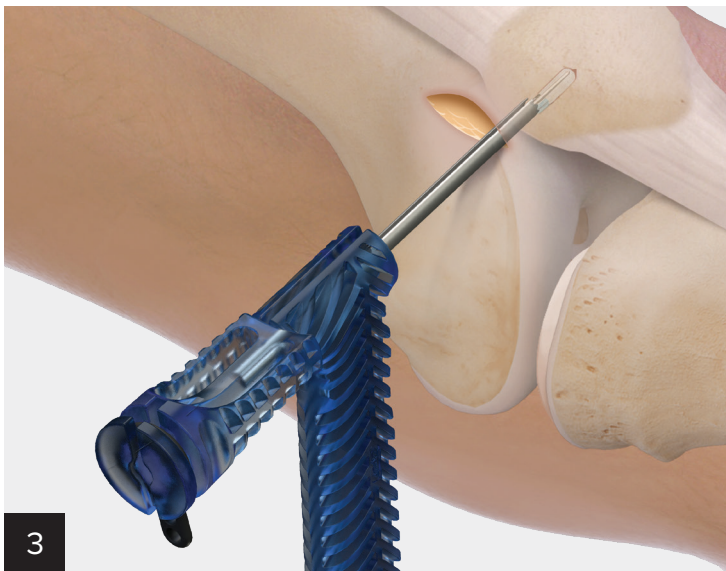2




2a

Palpate the medial patellar border and make a 2 cm skin incision from the superomedial corner, extending to the center of the medial edge of the patella. Dissect down and expose the medial edge of the patella. Create a groove on the medial patellar edge using a rongeur or powered burr. Identify and mark two points of fixation approximately at the level of the equator and 3 mm distal to the proximomedial corner of the patella.

These should be spaced roughly 15 mm to 20 mm apart. Use the Knee FiberTak® drill guide and 2.6 mm drill to create pilot hole. Drill to a depth at which the positive stop on the drill comes into contact with the back of the pistol-grip guide handle.

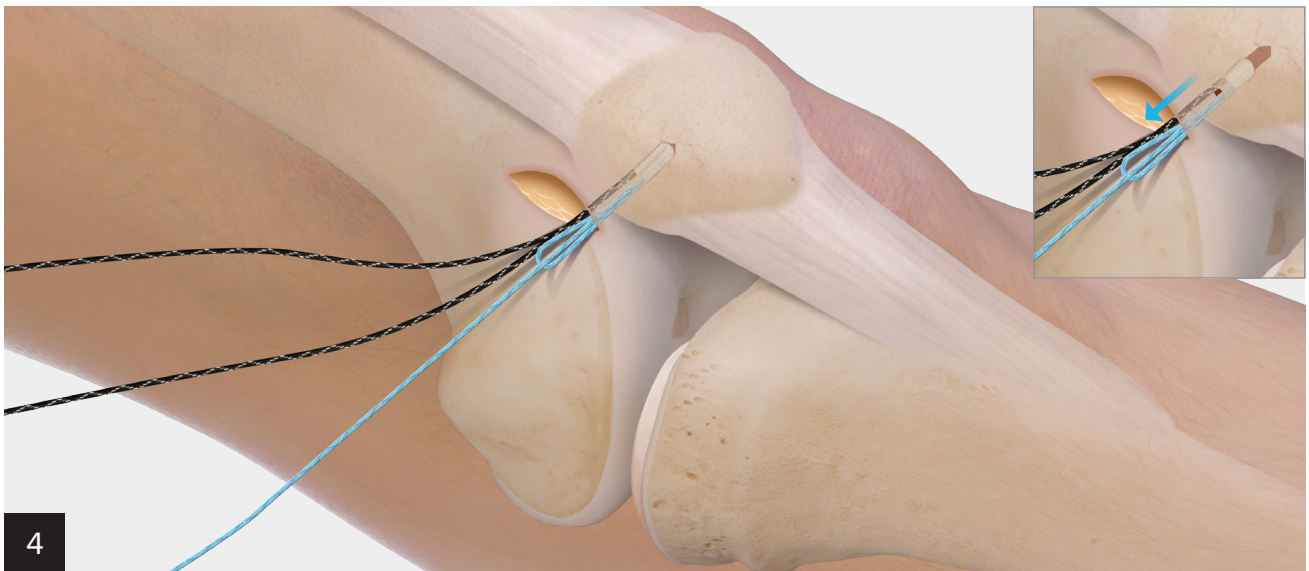


3



Use a mallet gently to impact the back of Hybrid Knee FiberTak anchor inserter handle until the blue handle comes into contact with the back of the pistol-grip guide.

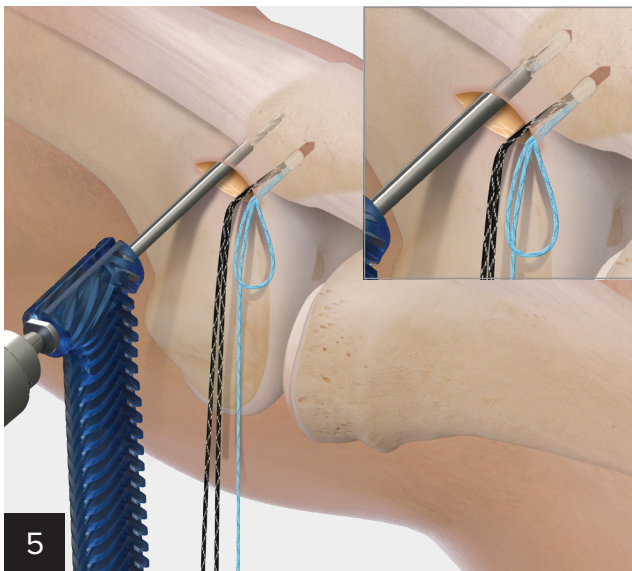
Note: Do not continue to impact the driver once the anchor inserter handle reaches the back of the guide handle. This could inadvertently advance the tip of the guide into bone, compromising the cortex and potentially impacting fixation strength.



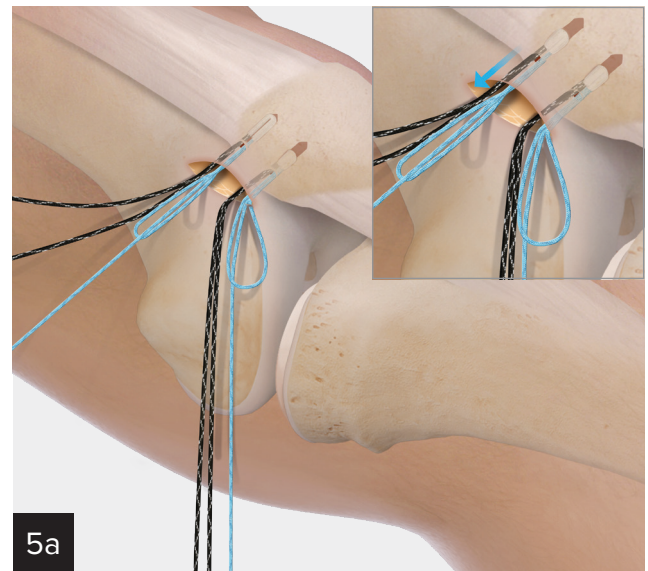
4

Remove the rubber suture-release tab and needle envelope from the driver handle, and remove the anchor inserter. Gently pull the black suture limbs to set the anchor in the patella.

Note: Do not pull on the blue tensioning suture. Doing so will reduce the knotless loop mechanism.

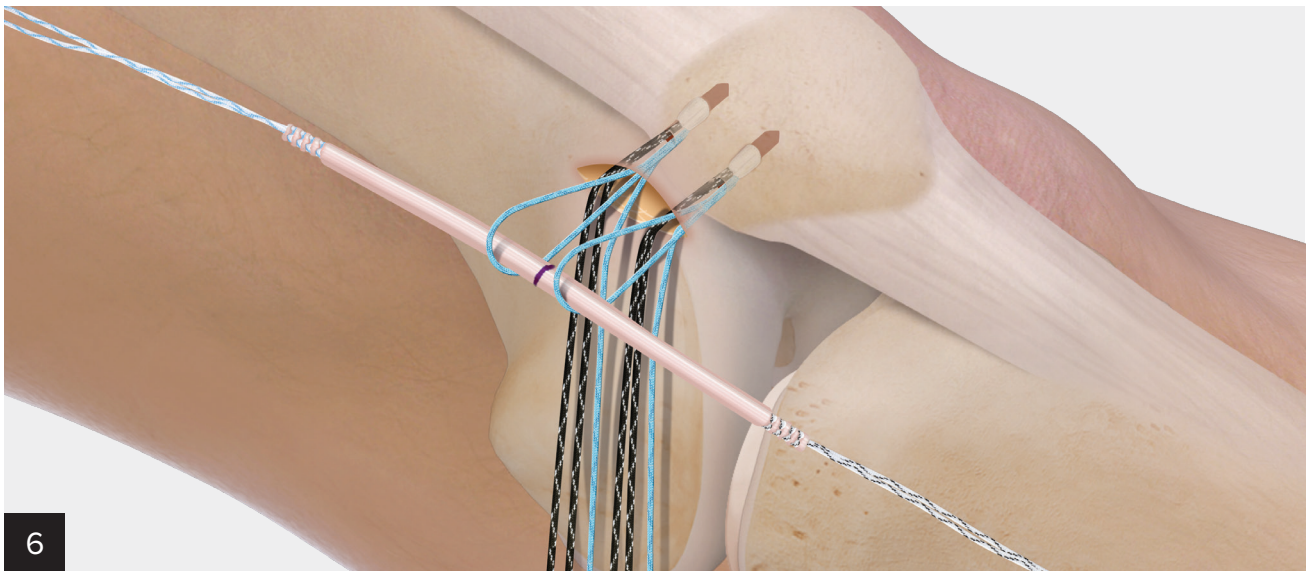


5

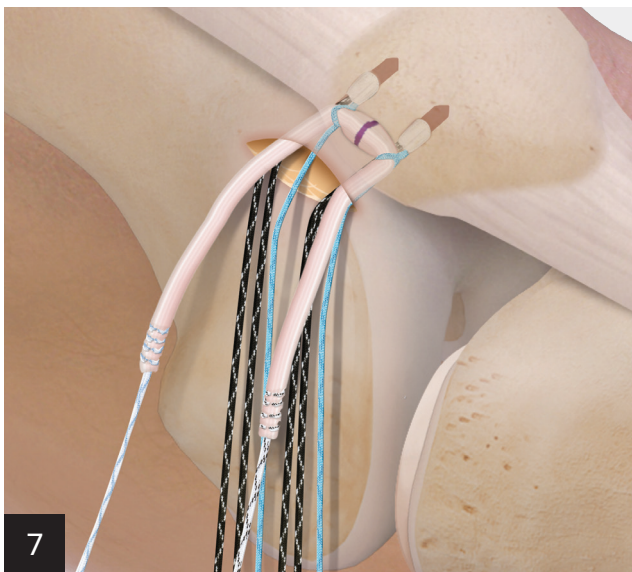

5a

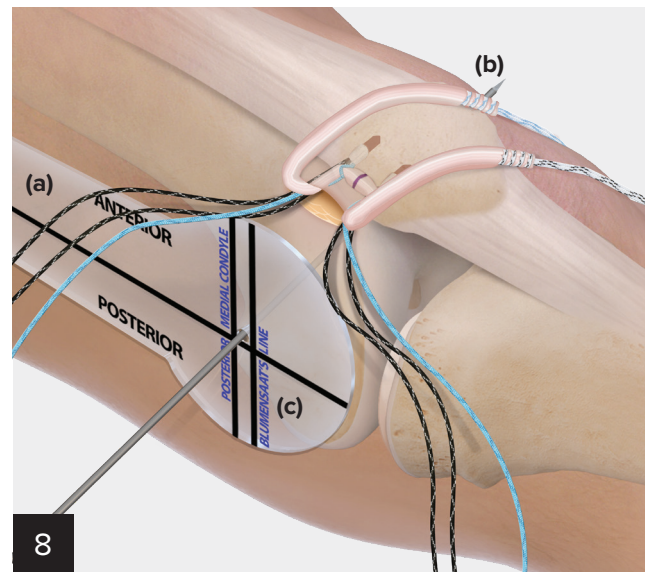
Repeat the drilling, insertion, and setting process to place a second Hybrid Knee FiberTak® anchor spaced approximately 15 mm to 20 mm from the first anchor.



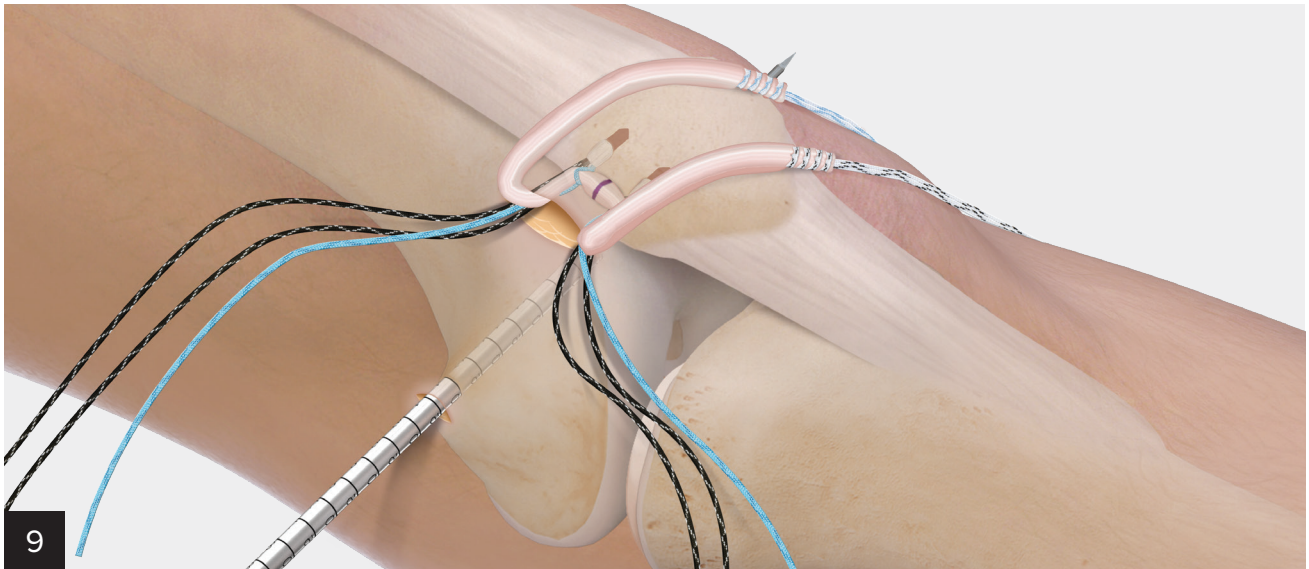
Shuttle the graft through the blue, preconverted tensionable loops, aligning the midpoint of the graft halfway between the anchors and leaving graft limbs of equal length.



With the graft stabilized, gently tension the blue limbs of the Hybrid Knotless FiberTak® anchors to reduce the knotless loops and tension the graft down to the medial patellar groove.

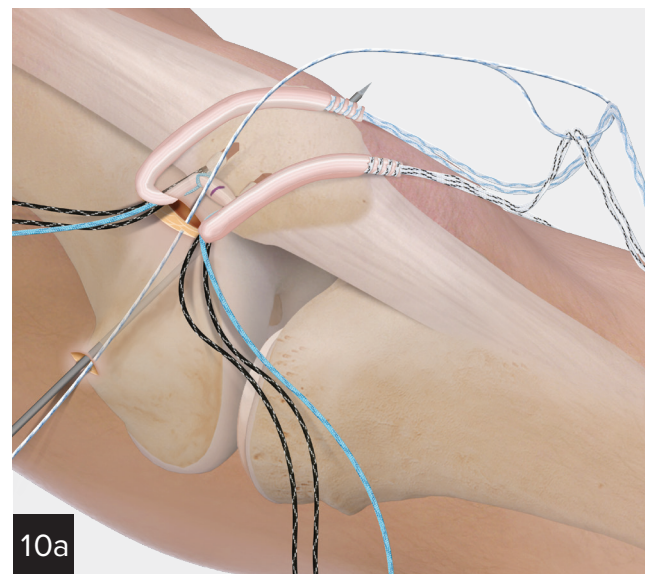
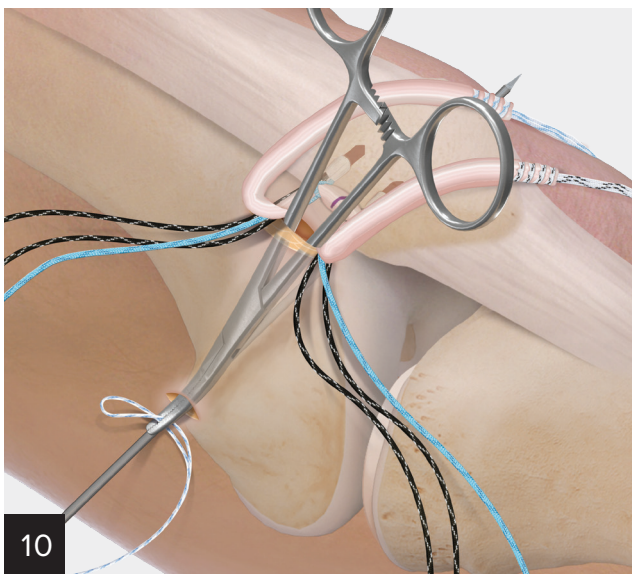


The proper position of the femoral insertion of the MPFL is very important to maintain proper biomechanics of the patellofemoral joint throughout the entire range of motion. Using the MPFL template **(a)** can help establish the position of the guide pin. The insertion point is approximately 1 mm anterior to the posterior cortex extension line, **(b)** 2.5 mm distal to the posterior articular border of the medial femoral condyle, and **(c)** proximal to the level of the posterior point of Blumensaat's line. Place the template on the area of the medial epicondyle on the distal femur and under fluoroscopic guidance, drill a 2.4 mm guide pin (AR-1297-02) across the femur and out through the lateral epicondyle.



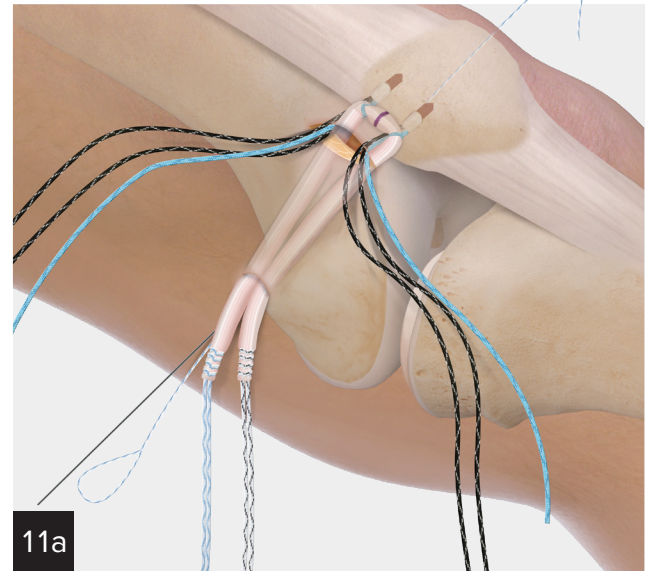
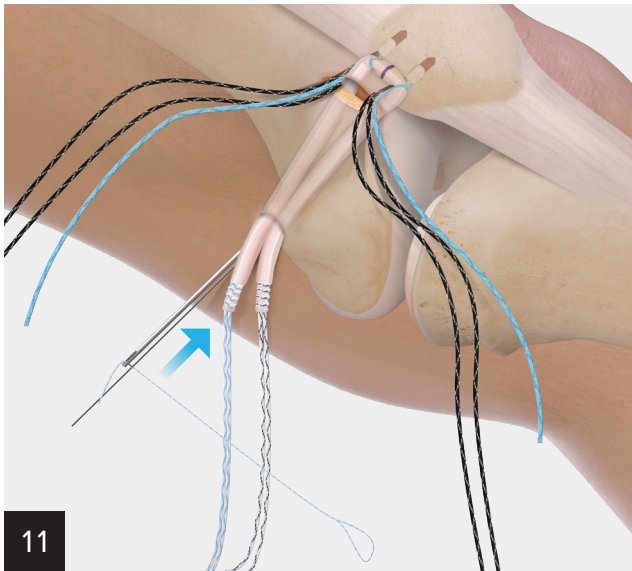
Use a 7 mm low-profile reamer to create a socket extending to the far cortex. Maintain the 2.4 mm guide pin in the femur as it will be used to pass the graft-shuttling suture through the femur.

Note: Before drilling, the isometry of the MPFL may be provisionally evaluated. Wrap the graft around the 2.4 mm guide pin with adequate tension on the graft and cycle the knee through the ROM. If isometry is not adequate, change the pin location before drilling with the 7 mm reamer.

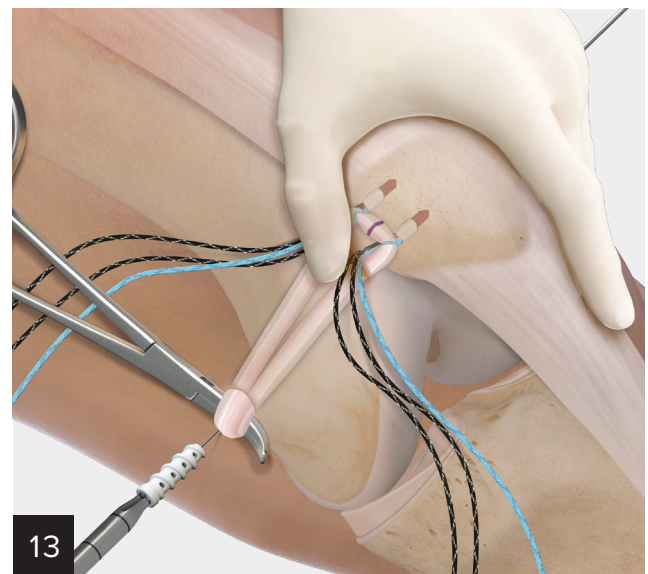
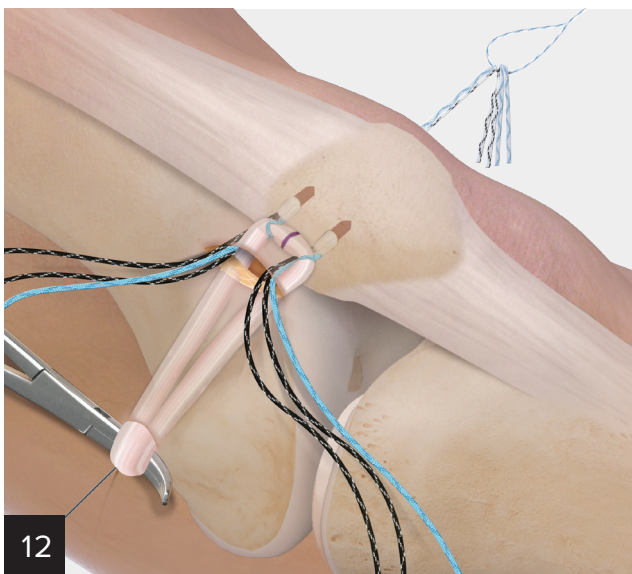


Identify space between the vastus medialis (the second layer of soft tissue) and the capsule (the third layer of soft tissue), and bluntly dissect toward the femoral insertion area with scissors, leaving the capsule intact. Insert a right-angle clamp into the prepared layer down to the medial epicondyle and turn the tip of the clamp toward the skin.

Make a 1 cm longitudinal incision and, using the clamp, pass the looped end of a FiberSnare® suture back to the patellar insertion area. Loop the whipstitched graft ends through the loop of the FiberSnare suture and pass the suture from the patellar origin to the insertion point at the medial femoral epicondyle. Deliver the sutures out of the medial incision and pull the graft down to the medial epicondyle.



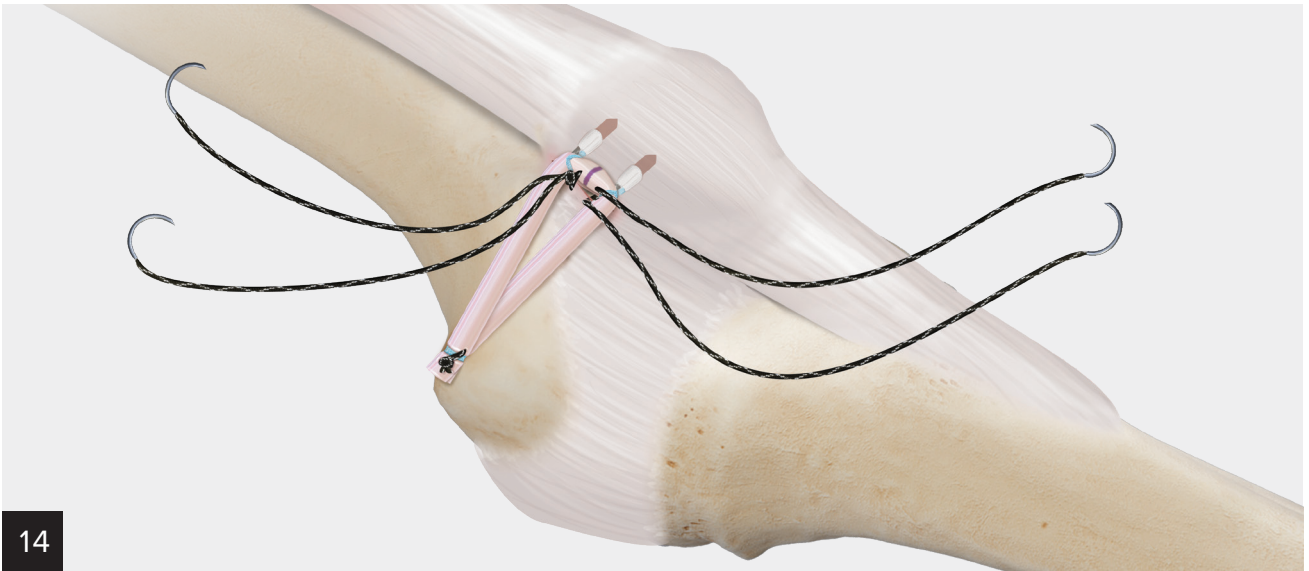
Place a 1.1 mm nitinol guide wire into the drill hole next to the femoral guide wire to facilitate insertion of the 7 mm × 20 mm BioComposite FastThread™ interference screw. Place the single end of a FiberSnare® suture onto the eyelet of the femoral drill pin and deliver out of the lateral femur.



Load whipstitch sutures from both ends of the graft into the loop of the FiberSnare suture and shuttle the suture tails out of the lateral femur prior to the graft entering the femoral socket. Using a clamp as a pulley, pretension the graft and insert it into the socket.

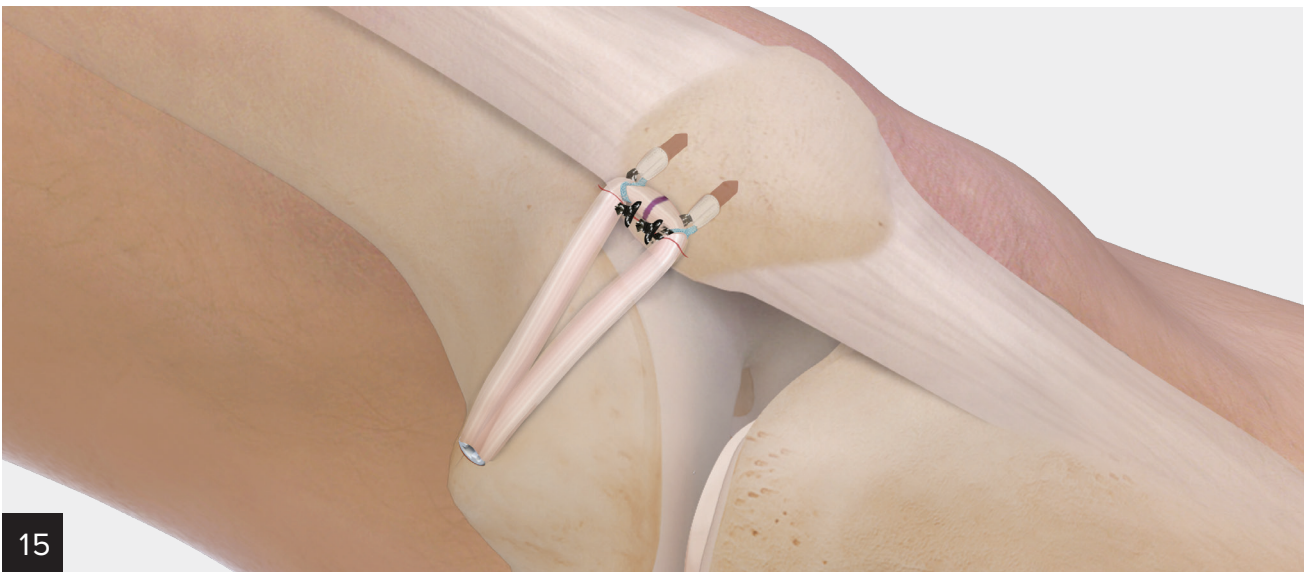With the knee at 30° of flexion, manually fixate the lateral patellar facet flush with the lateral femoral condyle. While maintaining tension on the graft, insert the 6 mm × 20 mm screw into the femur.

Note: Evaluate the tracking and laxity of the patella throughout the knee ROM. If any adjustments need to be made, back out the femoral screw, make any tension or positioning adjustments, and reinsert the screw.



14

Following final fixation, the black, sliding, 1.3 mm SutureTape limbs can be used to augment fixation or to aid in retinacular closure or imbrication as needed.



15

Final fixation.

Ordering Information

Product Description	Item Number
MPFL template	AR-13211
2.4 guide pin w/ eyelet	AR-1297-02
7 mm low-profile reamer	AR-1407LP
1.1 mm nitinol guidewire	AR-1249
6 mm × 20 mm BioComposite FastThread™ Interference Screw	AR-4020C-06
Hybrid Knee FiberTak® anchor	AR-3770SP
Knee FiberTak disposables kit	AR-3710DS
0.9 mm SutureTape loop, w/ straight needle, (white/black)	AR-7524
1.3 mm FiberLoop® SutureTape, (white/blue), looped with needle	AR-7534
1.3 mm TigerLoop™ SutureTape, (white/black), looped with needle	AR-7534T

Products may not be available in all markets because product availability is subject to the regulatory approvals and medical practices in individual markets. Please contact your Arthrex representative if you have questions about the availability of products in your area.

References

1. Desio SM, Burks RT, Bachus KN. Soft tissue restraints to lateral patellar translation in the human knee. *Am J Sports Med.* 1998;26(1):59-65. doi:10.1177/03635465980260012701
2. Nomura E, Inoue M. Surgical technique and rationale for medial patellofemoral ligament reconstruction for recurrent patellar dislocation. *Arthroscopy.* 2003;19(5):E47. doi:10.1053/jars.2003.50167
3. Amis AA, Firer P, Mountney J, Senavongse W, Thomas NP. Anatomy and biomechanics of the medial patellofemoral ligament. *Knee.* 2003;10(3):215-220. doi:10.1016/s0968-0160(03)00006-1
4. Schöttle P, Schmeling A, Romero J, Weiler A. Anatomical reconstruction of the medial patellofemoral ligament using a free gracilis autograft. *Arch Orthop Trauma Surg.* 2009;129(3):305-309. doi:10.1007/s00402-008-0712-9
5. Schöttle PB, Schmeling A, Rosenstiel N, Weiler A. Radiographic landmarks for femoral tunnel placement in medial patellofemoral ligament reconstruction. *Am J Sports Med.* 2007;35(5):801-804. doi:10.1177/0363546506296415
6. Schöttle PB, Hensler D, Imhoff AB. Anatomical double-bundle MPFL reconstruction with an aperture fixation. *Knee Surg Sports Traumatol Arthrosc.* 2010;18(2):147-151. doi:10.1007/s00167-009-0868-z



This description of technique is provided as an educational tool and clinical aid to assist properly licensed medical professionals in the usage of specific Arthrex products. As part of this professional usage, the medical professional must use their professional judgment in making any final determinations in product usage and technique. In doing so, the medical professional should rely on their own training and experience and should conduct a thorough review of pertinent medical literature and the product's directions for use. Postoperative management is patient-specific and dependent on the treating professional's assessment. Individual results will vary and not all patients will experience the same postoperative activity level or outcomes.

arthrex.com

© 2024-01 Arthrex, Inc. All rights reserved. LT1-000268-en-US_B



Arthrex manufacturer,
authorized representative,
and importer information
(Arthrex eIFUs)



US patent information