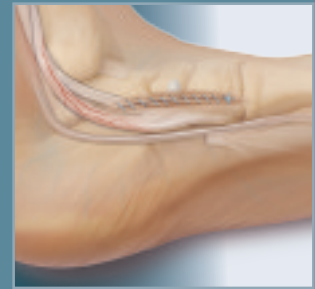
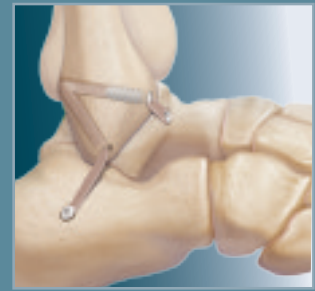


Five Comprehensive Solutions for Tendon and Ligament Reconstruction Using the Bio-Tenodesis Screw System

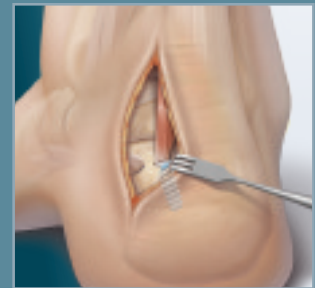


Lateral Ankle Reconstruction

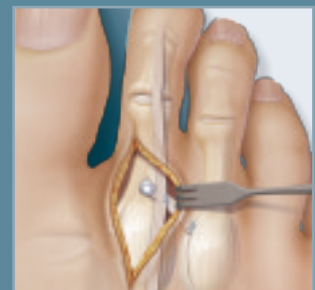
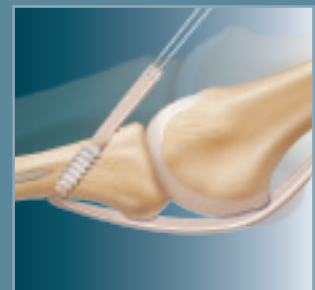
FDL Tendon Transfer

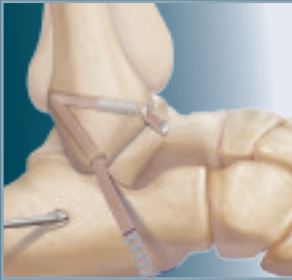
FHL Tendon Transfer

Flexor to Extensor Transfer



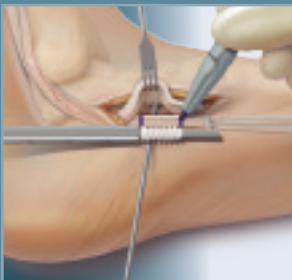
FDL/EDL Transfer Using the Plantar Approach





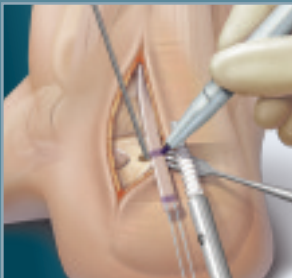
Lateral Ankle Reconstruction

This technique describes an augmented ankle reconstruction using a free tendon graft and multiple options from the Bio-Tenodesis System to achieve an anatomic reconstruction of the anterior talofibular and calcaneofibular ligaments with simple tensioning and rigid fixation.



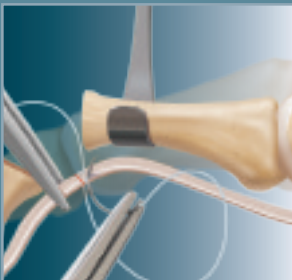
FDL Tendon Transfer

The FDL tendon transfer is indicated for patients with a dysfunction of the posterior tibialis tendon, where the tendon has become stretched beyond its function length or ruptured. As a result, the FDL tendon is transferred into a blind bone tunnel and then into the navicular with the use of the patented Bio-Tenodesis System.



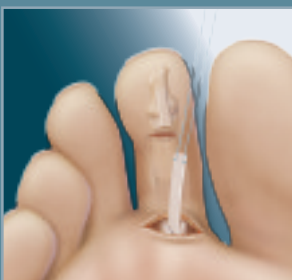FHL Tendon Transfer

FHL tendon transfers may be used in conjunction with Achilles reconstruction or for tendon balancing with peroneal tendon deficiency. A screw from the Bio-Tenodesis System is used to combine interference screw and suture anchor fixation to maximize the intrasosseous tendon fixation strength needed for these indications.



Flexor to Extensor Transfer

Hammertoe repair is performed when any fixed deformity is present, which is often the case, with a 2nd MTP joint subluxation or dislocation. A 3 mm x 8 mm screw from the Bio-Tenodesis System is reduced to a level position with respect to the metatarsal head by tensioning the flexor transfer until the bony surfaces are aligned.



FDL/EDL Transfer Using the Plantar Approach

This is a technique by Eugene Curry, M.D., Dallas, TX, of a transfer using a plantar approach for tendon harvest. When only capsular instability is present (no associated hammertoe or clawtoe deformity), the current technique cannot be used. The FDL tendon must be harvested via the plantar approach.

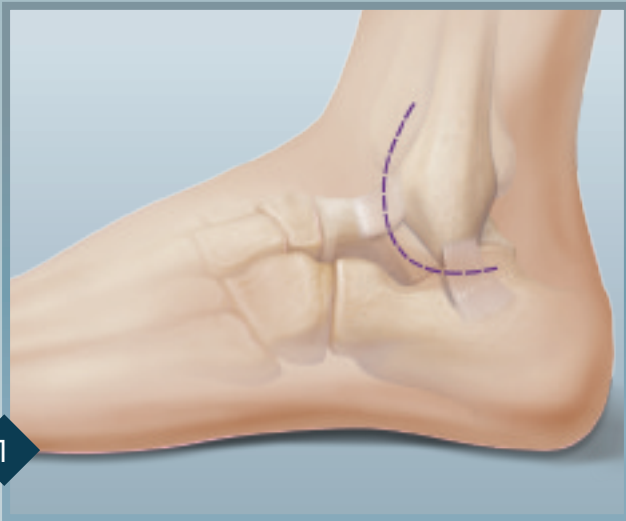
Lateral Ankle Reconstruction

This surgical technique describes an augmented ankle reconstruction using a free tendon graft and rigid interference screw fixation with the Bio-Tenodesis™ Screw System. The goal of this technique is to achieve an anatomic reconstruction of the anterior talofibular and calcaneofibular ligaments with simple tensioning and rigid fixation of the graft. Rigid fixation allows earlier postoperative motion.

A smaller incision is needed and less surgical exposure is required. In addition, the peroneal tendons are not disturbed. Tissue augmentation in ankle ligament reconstruction is usually reserved for patients with ligamentous laxity or surgical revisions. Common to these techniques is the need for wide surgical exposures, lack of rigid fixation of the graft and the recommended postoperative immobilization. Revision ankle

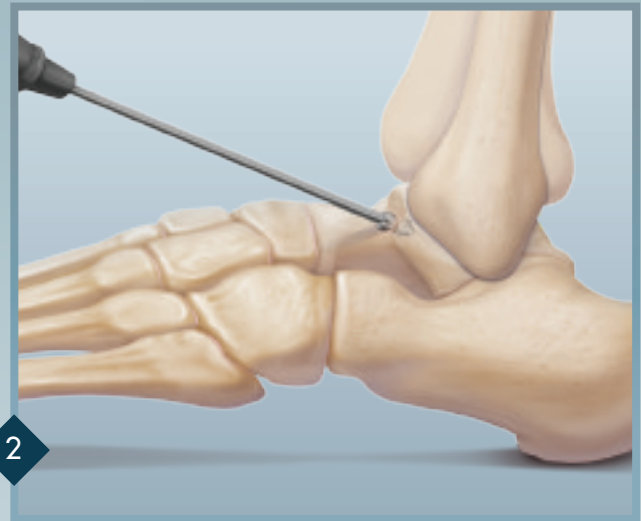ligament reconstruction is an option for the patient with recurrent instability and is usually performed with tissue augmentation. Many of these techniques, for example, Evans/Chrisman-Snook) are nonanatomic. Anatomic procedures include those described by Drs. Elmslie and Colville. Some of these techniques use the peroneus brevis tendon to augment ligamentous tissue.

Dr. Coughlin described an anatomic reconstruction using a free semitendinosus graft and stressed the importance of preserving peroneal tendon function in patients with recurrent ankle instability. The method of graft fixation is similar in all of these techniques which involves passing the tendon graft through bone tunnels and suturing it back on itself. This type of fixation is quite variable and is based on the size of the bone bridge created, the quality of bone, and the holding strength of the suture in the tendon.



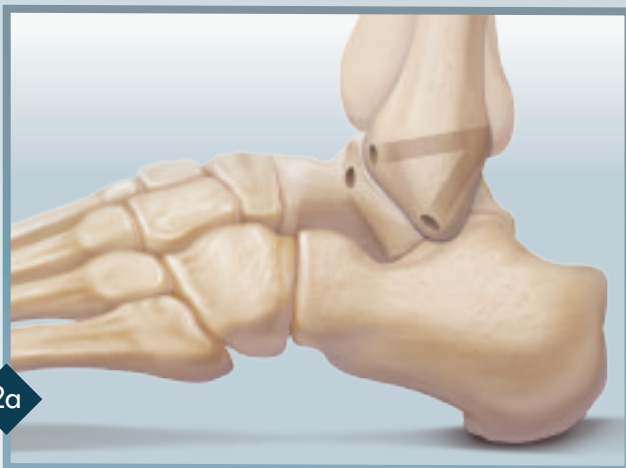1

An arthrotomy is made at the talofibular joint and is carried around the distal end of the fibula to the peroneal sheath. This sheath is opened and the peroneal tendons are retracted posteriorly. The capsule and periosteum over the distal fibula is elevated, exposing the previous insertion of the calcaneofibular and anterior talofibular ligaments.



2

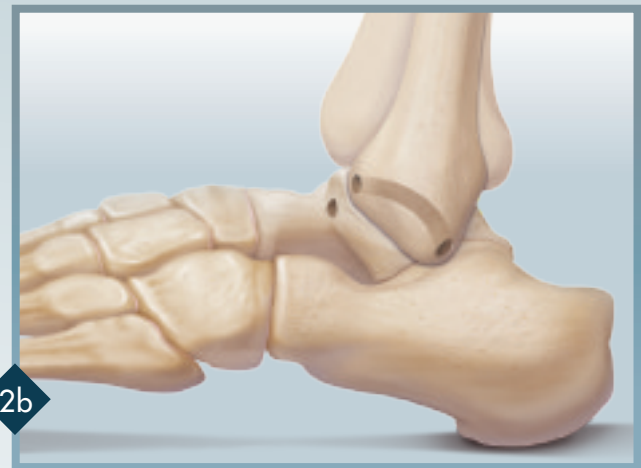A 5.5 mm diameter x 17 mm long tunnel is drilled in the talus and a 5 mm tunnel is created in the fibula for passage of the graft. *Note: On creation of bone tunnels, proper screw and pilot hole diameter depends on the exact diameter of the tendon graft. Bone tunnel diameter should be .5 mm to 1 mm larger than the size of the tendon (ex. 4.5 mm graft requires 5 – 5.5 mm diameter hole).*



2a

After anatomic attachment sites are determined, pilot holes are drilled with a 2.4 mm guide pin in the talar neck and calcaneus. Two options are described for reaming the fibular sockets.

Drill Technique Option A: The fibular socket (ATFL arm) should start anterior to posterior, angling slightly proximal and exiting the posterior fibula. The CFL arm is drilled from the anatomic attachment site of the CFL on the tip of the fibula to the posterior fibula. This approach will increase the bone bridge between the ATFL arm and CFL arm of this construct.



2b

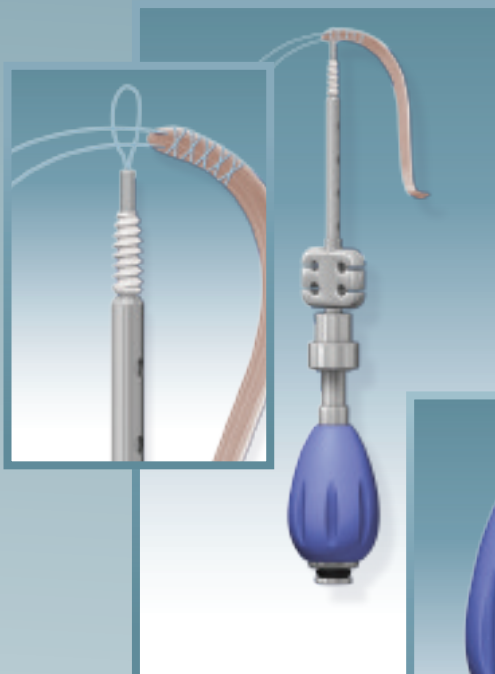
Drill Technique Option B: Using a 5 mm Cannulated Headed Reamer, drill from the anterior and distal fibula at the insertion point of the anterior talofibular and calcaneal fibular ligaments. These tunnels are connected using a curved curette.

Lateral Ankle Reconstruction

Graft Harvesting & Preparation

Harvest the semitendinosus tendon from the ipsilateral knee (an allograft soft tissue tendon may also be used). The graft length should be 14 cm for most patients. It is suggested that a locking whipstitch, using 2-0 or #2 FiberWire®, be created at the end of the graft to be placed into the talar attachment site. The whipstitch should extend no more than 15 mm from the tip of the tendon, as this resembles the length of the 4.75 and 5.5 mm x 15 mm screws suggested for this procedure.

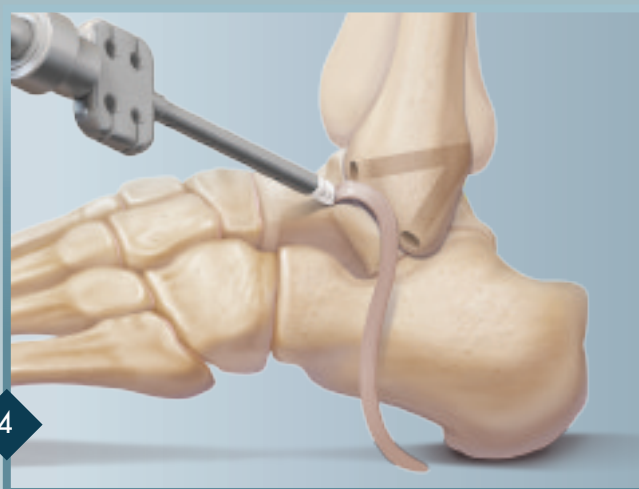
Using the sizing holes on the Bio-Tenodesis Driver's thumbpad, take an accurate diameter measurement of the tendon. Selection of the appropriate Bio-Tenodesis Screw should be based on the diameter of the tendon, from the tip of the tendon to approximately 15 mm along the graft at both ends.



Creation of FiberWire Suture Loop

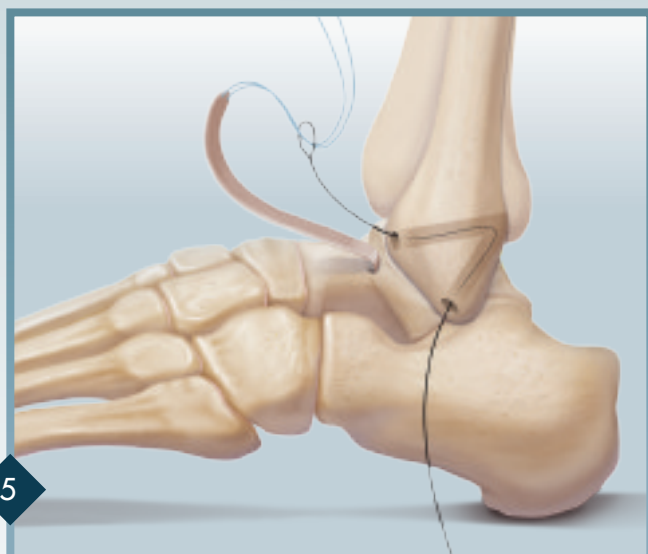
Prior to placement of the talar screw or calcaneal screw, use the Nitinol wire and #2 FiberWire to create a suture loop at the tip of the Bio-Tenodesis Driver. Snare the tip of the whipstitched tendon 2 mm from the end of the graft. Place tension on the sutures exiting the back of the Tear Drop Handle and wrap them once around the O-ring inside the cleat. It is important to maintain maximum tension between the driver tip and the tendon during initial placement of the tendon in the tunnel.

3



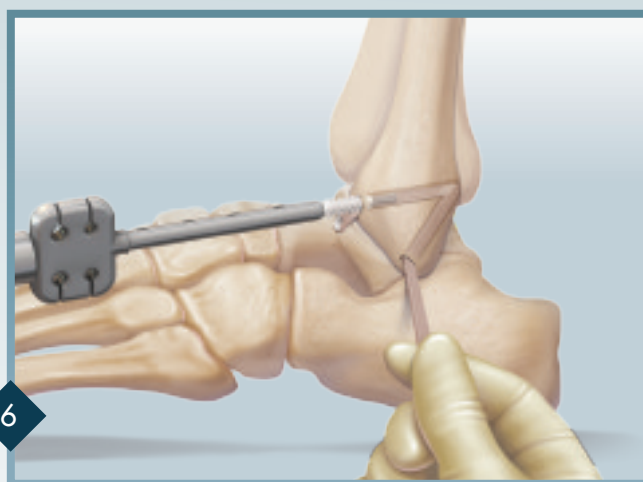
4

Place the driver tip with tendon into the bone socket. It is important that the tip of the driver with tendon attached be placed in the tunnel until the proximal screw threads are in contact with the anterior cortex. Prior to turning the Tear Drop Handle, make sure the tendon is seated properly in the tunnel. Turn the blue handle clockwise while holding the metal thumbpad stationary. The screw is seated properly when it is flush with the cortical bone. Remove the driver and tie the suture tails over the top of the screw. Cut the remaining suture.



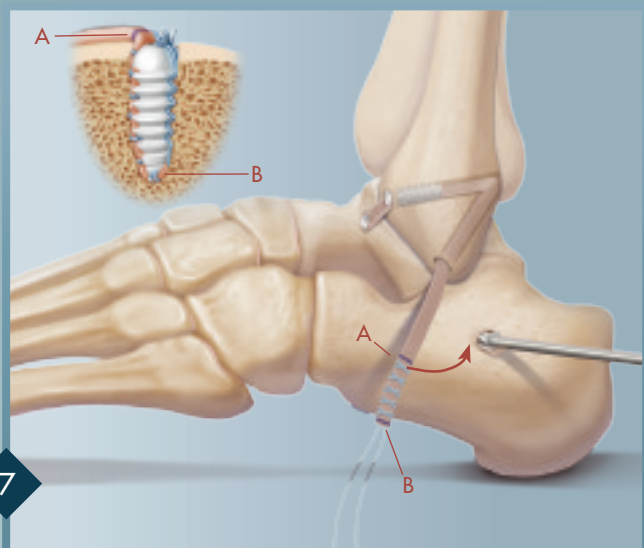
5

To pass the ATFL arm of the graft through the fibula, insert the nonlooped end of the Nitinol Suture Passing Wire through the anterior fibular drill hole and distally through the tunnel exiting the hole on the bottom of the fibula. With the Nitinol loop exposed, insert both tails of the traction stitch one inch from the tip. Pull the Nitinol loop through the fibular tunnel, passing the graft from proximal to distal. The tendon graft is now ready for proper anatomic tensioning and calcaneal screw placement.



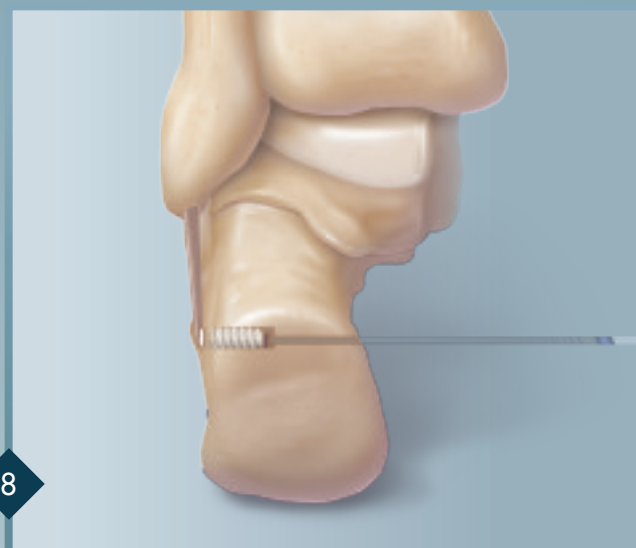
6

An optional screw can be placed in to the anterior fibular tunnel to recreate the ATF ligament and to limit motion throughout the entire construct.



7

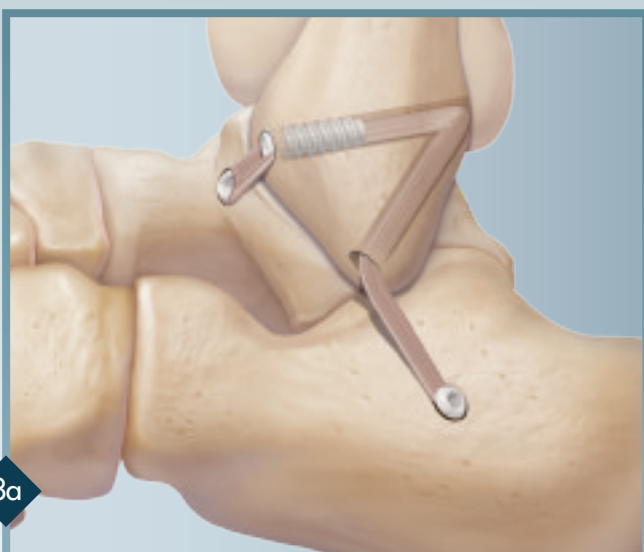Tension the CFL arm with neutral ankle flexion and slight heel eversion and mark a blue line across the tendon where the graft should enter the calcaneal bone tunnel (A). Measure 17 mm down (2 mm more than length of a 5.5 mm x 15 mm screw) on the remaining tendon graft and place another blue mark (B). Whipstitch the portion of the tendon between the two blue lines and remove any excess tendon. Place the heel in slight eversion and the ankle in a neutral position prior to screw insertion. To insert the screw, hold thumbpad and turn the blue Tear Drop Handle. Insert the screw until it is flush with the lateral cortex.



8

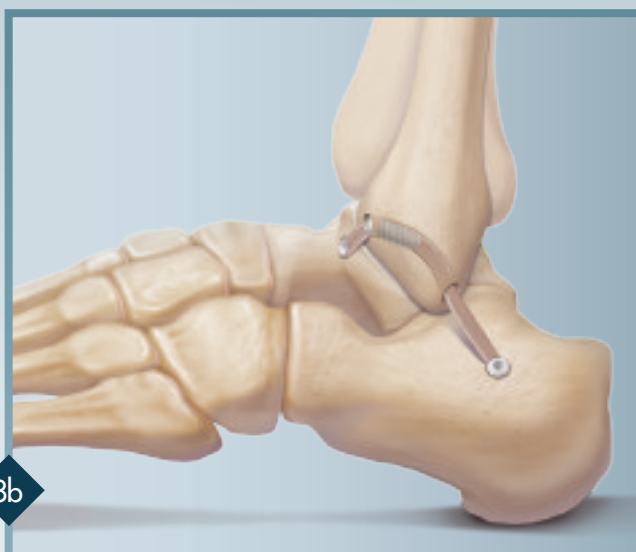Alternative Fixation Method in Calcaneus

Using a 2.4 mm Beath Pin (w/eyelet), drill a pilot hole from the insertion point (CFL) posteromedially, exiting the medial cortex of the calcaneus. Overdrill the pilot hole with a 5.5 mm reamer to a depth of 17 mm. The suture on the end of the tendon is passed through the tunnel with the aid of the Beath Pin. This suture is tensioned, pulling the graft into the tunnel. The driver with a screw attached is placed over the graft and inserted, while tension is applied to the traction suture. The remaining traction suture is cut. Reference 8a for close-up of the complete construct using this alternative fixation method.



8a

The construct is complete, using fibular drilling techniques. A third screw can be placed into the fibular ATFL tunnel to minimize loss of fixation in the fibula.




8b

The construct is complete, using Option B fibular drilling techniques.

Ordering Information

Bio-Tenodesis Screw Master Set (AR-1675S) includes:

Tear Drop Handle w/Suture Cleat	AR-2001BT
Cannulated Drill, 4 mm	AR-1204L
Cannulated Drill, 4.5 mm	AR-1204.5L
Cannulated Headed Reamers, 5 mm – 10 mm	AR-1405 – 1410
Driver for 10 mm Tenodesis Screws	AR-1540DB
Driver for 10 mm and 12 mm Tenodesis Screws	AR-1670DB
Driver for 15 mm Tenodesis Screws	AR-1350D
Driver for 23 mm Tenodesis Screws	AR-1570DB
Bio-Tenodesis Screw Instrumentation Case	AR-1675C



Implants:

BioComposite Tenodesis Screw w/handled inserter, 3 mm x 8 mm	AR-1530BC
BioComposite Tenodesis Screw, 4 mm x 10 mm	AR-1540BC
BioComposite Tenodesis Screw, 4.75 mm x 15 mm	AR-1547BC
BioComposite Tenodesis Screw, 5.5 mm x 15 mm	AR-1555BC
BioComposite Tenodesis Screw, 6.25 mm x 15 mm	AR-1562BC
BioComposite Tenodesis Screw, 7 mm x 10 mm	AR-1670BC
BioComposite Tenodesis Screw, 7 mm x 23 mm	AR-1570BC
BioComposite Tenodesis Screw, 8 mm x 12 mm	AR-1680BC
BioComposite Tenodesis Screw, 8 mm x 23 mm	AR-1580BC
BioComposite Tenodesis Screw, 9 mm x 23 mm	AR-1590BC
Tenodesis Screw, 4.75 mm x 15 mm, titanium	AR-1350-475
Tenodesis Screw, 5.5 mm x 15 mm, titanium	AR-1350-55

Bio-Tenodesis Screw w/handled inserter, 3 mm x 8 mm	AR-1530B
Bio-Tenodesis Screw, 4 mm x 10 mm	AR-1540B
Bio-Tenodesis Screw, 4.75 mm x 15 mm	AR-1547B
Bio-Tenodesis Screw, 5.5 mm x 15 mm	AR-1555B
Disposable Tenodesis Driver w/5.5 mm Screw and #2 FiberWire	AR-1555DS
Bio-Tenodesis Screw, 6.25 mm x 15 mm	AR-1562B
Bio-Tenodesis Screw, 7 mm x 10 mm	AR-1670B
Bio-Tenodesis Screw, 7 mm x 23 mm	AR-1570B
Bio-Tenodesis Screw, 8 mm x 12 mm	AR-1680B
Bio-Tenodesis Screw, 8 mm x 23 mm	AR-1580B
Bio-Tenodesis Screw, 9 mm x 23 mm	AR-1590B

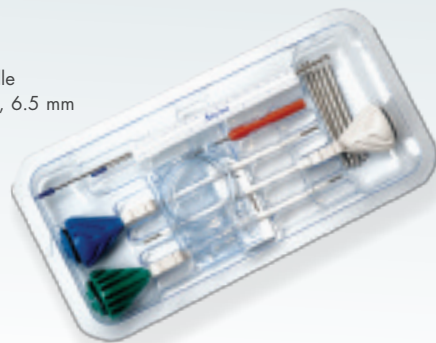PEEK Tenodesis Screw w/handled inserter, vented, 3 mm x 8 mm	AR-1530PS
PEEK Tenodesis Screw, vented, 4 mm x 10 mm	AR-1540PS
PEEK Tenodesis Screw, vented, 4.75 mm x 15 mm	AR-1547PS
PEEK Tenodesis Screw, vented, 5.5 mm x 8 mm	AR-1655PS
PEEK Tenodesis Screw, vented, 6.25 mm x 15 mm	AR-1562PS
PEEK Tenodesis Screw, vented, 7 mm x 10 mm	AR-1670PS
PEEK Tenodesis Screw, vented, 7 mm x 23 mm	AR-1570PS
PEEK Tenodesis Screw, vented, 8 mm x 12 mm	AR-1680PS
PEEK Tenodesis Screw, vented, 8 mm x 23 mm	AR-1580PS
PEEK Tenodesis Screw, vented, 9 mm x 23 mm	AR-1590PS

Lateral Ankle Reconstruction Implant System (AR-1675BC-CP) includes:

BioComposite Tenodesis Screws on Disposable Tenodesis Driver:

4 mm x 10 mm (fibula)
4.75 mm x 15 mm (talus or calcaneus)
5.5 mm x 15 mm (talus or calcaneus)
6.25 mm x 15 mm (calcaneus)

Guide Pins 1.6 mm, 2.4 mm
#2 FiberWire (blue)
6" Ruler
Suture Passing Wire
Two FiberLoops w/Straight Needle
Cannulated Drills, 4.5, 5, 5.5, 6, 6.5 mm
QuickPass Tendon Shuttle



Lateral Ankle Reconstruction Implant System (AR-1675BC-CP)


Optional Disposable Accessories:

Bio-Tenodesis Disposables Kit (AR-1676DS) includes:

Short Guide Pin w/eyelet, 2.4 mm, Suture Passing Wire,
#2 FiberLoop w/Straight Needle, two #2 FiberWire,
two 2-0 FiberWire, 6" Ruler

Bio-Tenodesis Disposables Kit for 3 mm x 8 mm Screw (AR-1530DS) includes:

Guidewire .041" (1 mm), Suture Passing Wire,
2-0 FiberWire w/Needle, Cannulated Drills 2.5 mm, 3 mm and 3.5 mm



Accessories (optional):

Bio-Tenodesis Tap, 4 mm x 10 mm	AR-1540T
Bio-Tenodesis Tap, 4.75 mm x 15 mm	AR-1547T
Bio-Tenodesis Tap, 5.5 mm x 15 mm	AR-1555T
Bio-Tenodesis Tap, 6.25 mm x 15 mm	AR-1562T
Bio-Tenodesis Tap, 7 mm x 10 mm	AR-1670T
Bio-Tenodesis Tap, 7 mm x 23 mm	AR-1570T
Bio-Tenodesis Tap, 8 mm x 12 mm	AR-1680T
6.7 mm Low Profile Screw System Tenodesis Module (for calcaneal osteotomies)	AR-8967S

Multimedia:

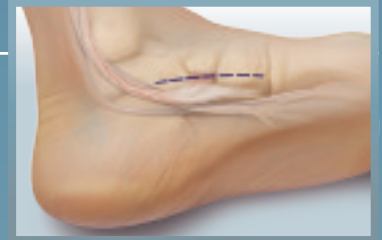Bio-Tenodesis Animation (web only)	DVD-1093
Comprehensive Foot & Ankle Surgical Technique	DVD-1103
Techniques for Tendon Transfer in Foot & Ankle Reconstruction using Bio-Tenodesis Fixation by Thomas Clanton, M.D. (web only)	DVD-1064
Lateral Ankle Reconstruction, Ankle Arthroscopy and Talar OATS by Nicholas Abidi, M.D. (web only)	DVD-1107

Literature:

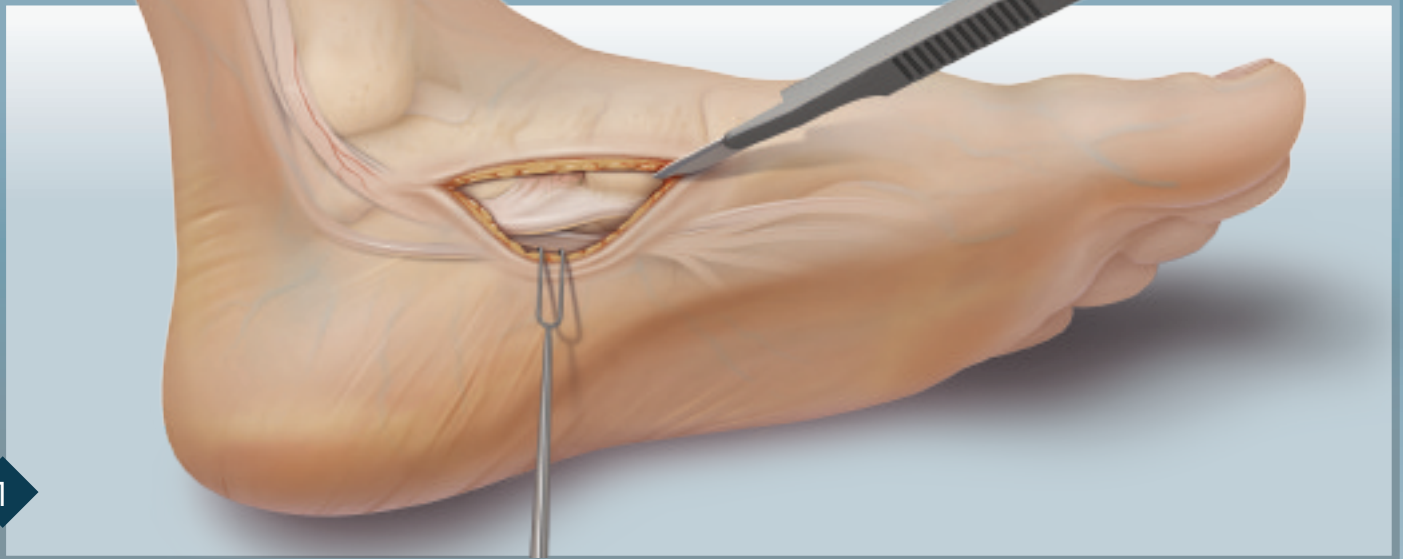
Bio-Tenodesis Brochure	LB0505
------------------------	--------

FDL Transfer

The FDL tendon transfer is indicated for patients with a dysfunction of the posterior tibial tendon, where the tendon has become stretched beyond its functional length or has ruptured. As a result, the FDL tendon is transferred into a bone tunnel into the navicular and fixated with a screw from the Bio-Tenodesis Screw System. This transfer is not recommended as the sole procedure to address flatfoot and should be combined with hindfoot techniques. The spring ligament should also be inspected as 80 – 90% of the PTT injuries compromise the spring ligament.



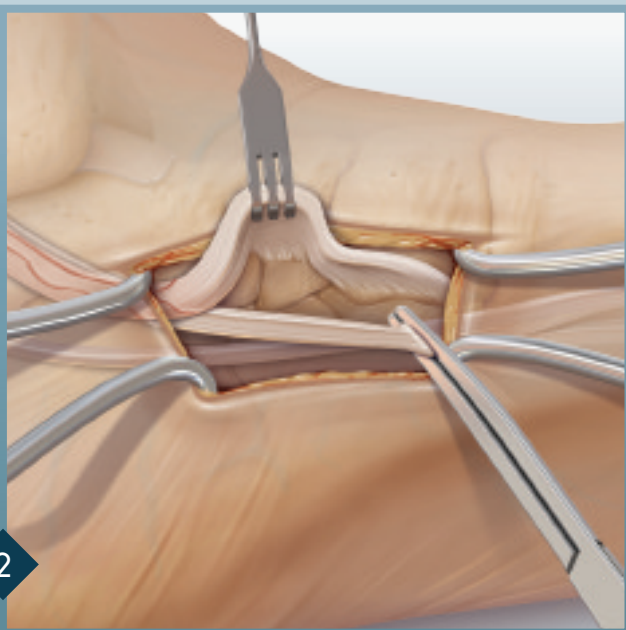
1



Make a longitudinal incision about 5 – 7 cm over the medial aspect of the navicular bone and naviculocuneiform joint. Deeper dissection is necessary to identify the insertional expansion of the Posterior Tibialis Tendon (PTT).

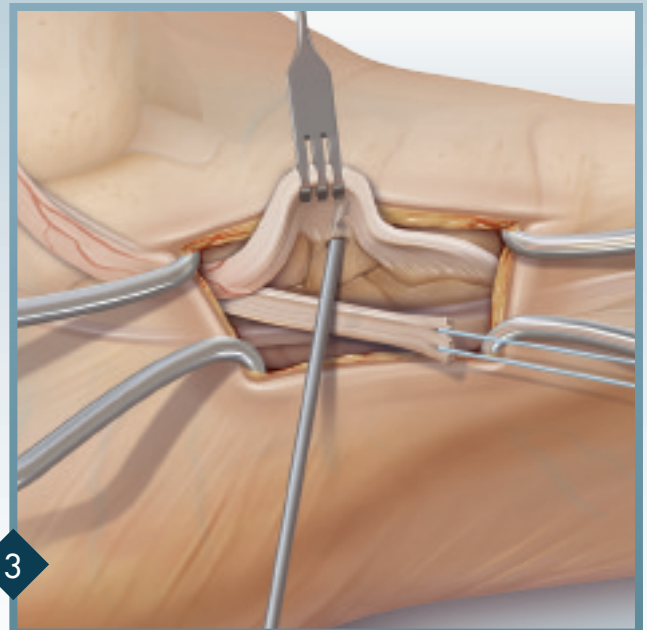
The posterior tibial tendon tenosynovectomy is performed and all necrotic PTT is excised. A longitudinal incision is made in the floor of the PTT sheath, carried down to the FDL.

2



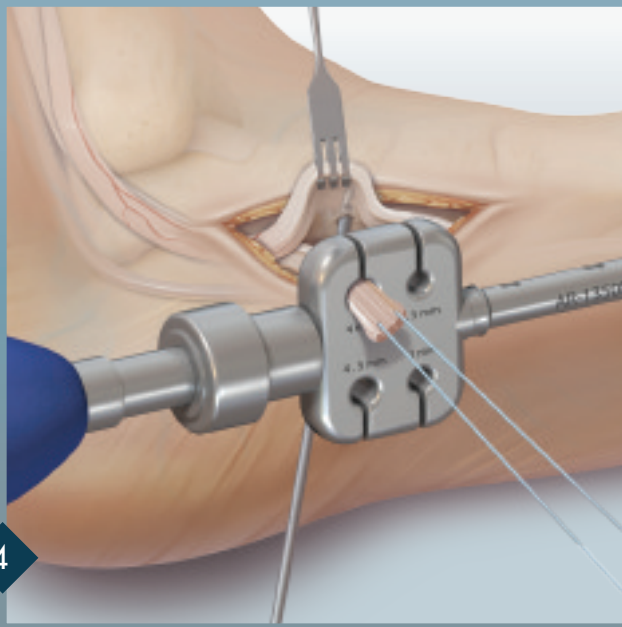
The medial fascia is opened, the FDL tendon is identified and dissected proximal to the Master Knot of Henry. The FDL is clamped.

3



A traction stitch is placed through the free end of the FDL tendon using a #2 FiberWire®. Place the 2.4 mm Guide Pin, from plantar-to-dorsal in the navicular, under fluoroscopy to verify near central position.

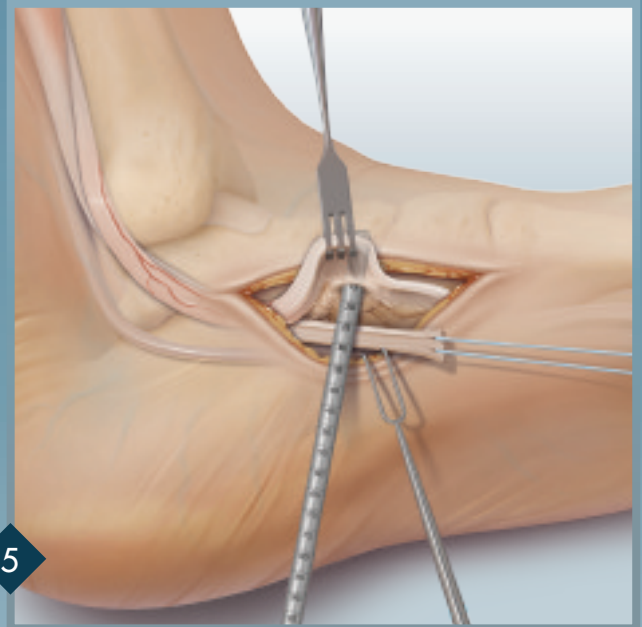
FDL Transfer



4

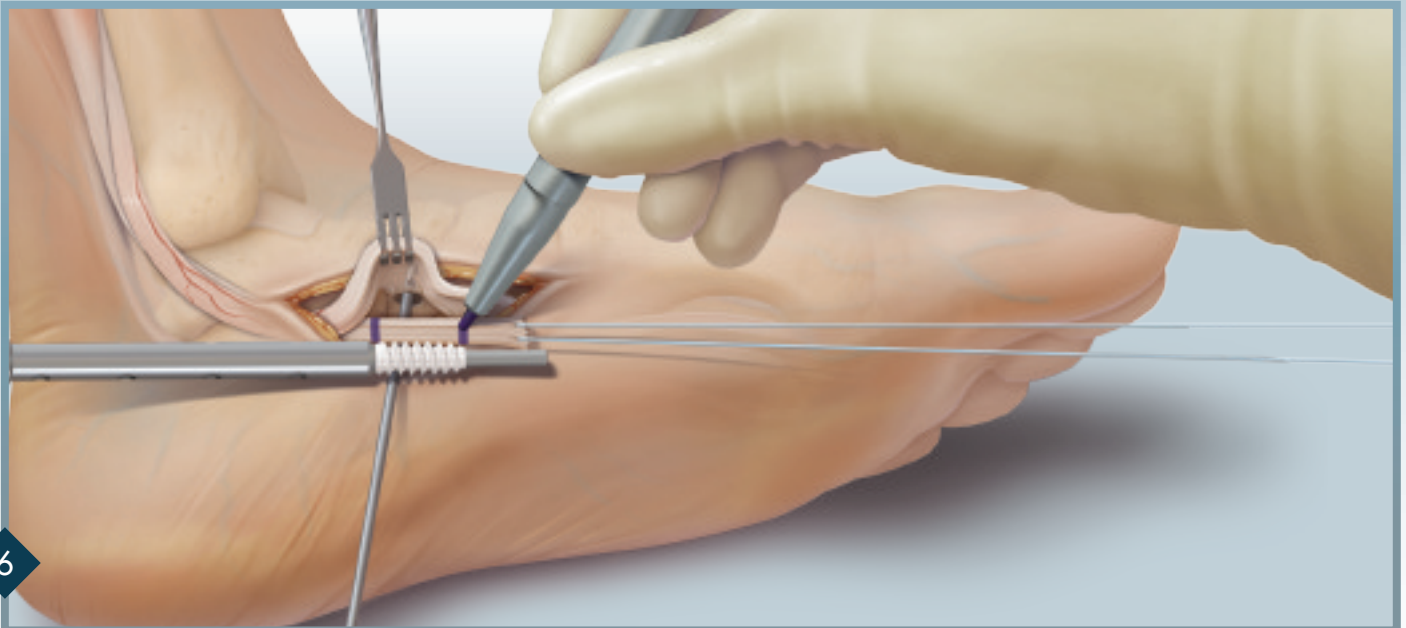
Using the traction stitch, size the tendon through the thumb pad on the driver.

Optional technique: If the surgeon prefers to use Interference Screw technique, more FDL length is needed and a plantar-to-dorsal hole should be created in the navicular.



5

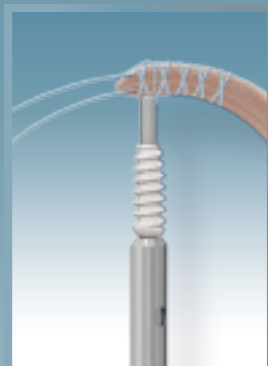

With a 4.5 mm tendon, ream over the guide pin with a 5.5 mm reamer 17 mm. *Note: On creation of the bone tunnel, (1) Proper screw and pilot hole diameter depend on the exact diameter of the tendon graft. (2) Bone tunnel diameter should be .5 mm to 1 mm larger than the size of the tendon (ex. 4.5 mm graft requires 5–5.5 mm diameter hole). (3) Bone tunnel depth should be 2 mm longer than the length of the screw (5.5 x 15 mm screw = depth of 17 mm).*




6

Tension and mark the tendon at the bone tunnel. Measure 17 mm from the first marking on the FDL and make a second mark.

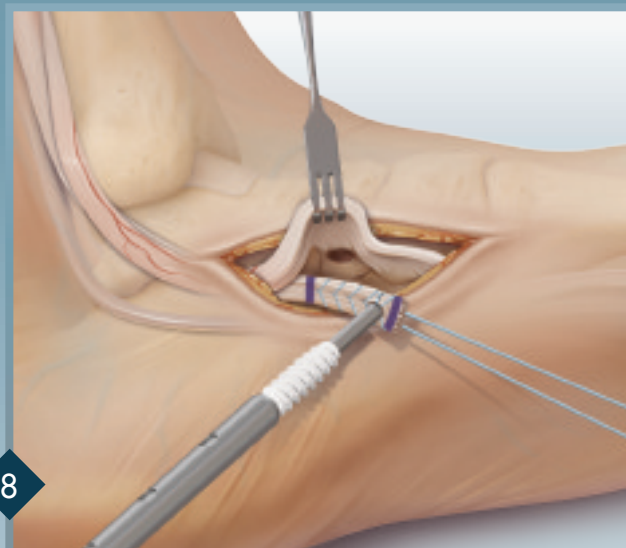
7



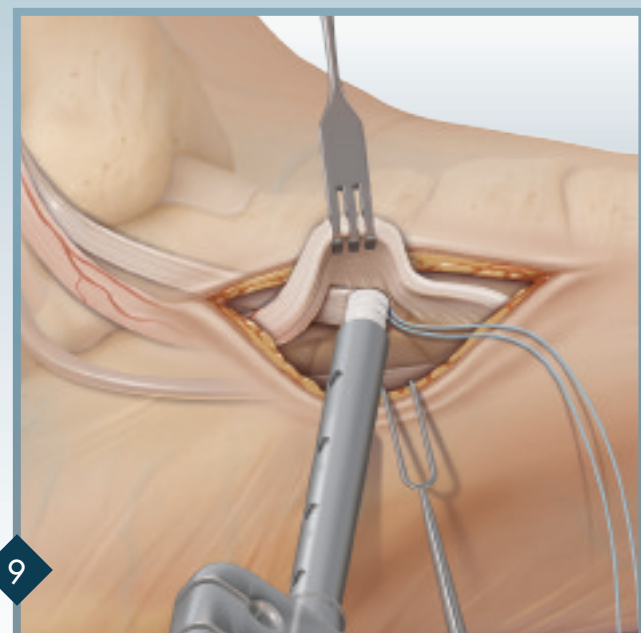
Use the Nitinol wire and #2 FiberWire to create a suture loop at the tip of the Bio-Tenodesis Driver. Snare the tip of the whipstitched tendon 2 mm from the end of the graft. Place tension on the sutures exiting the back of the Tear Drop Handle and wrap them once around the O-ring inside the cleat. It is important to maintain maximum tension between the driver tip and the tendon during initial placement of the tendon in the tunnel.



8

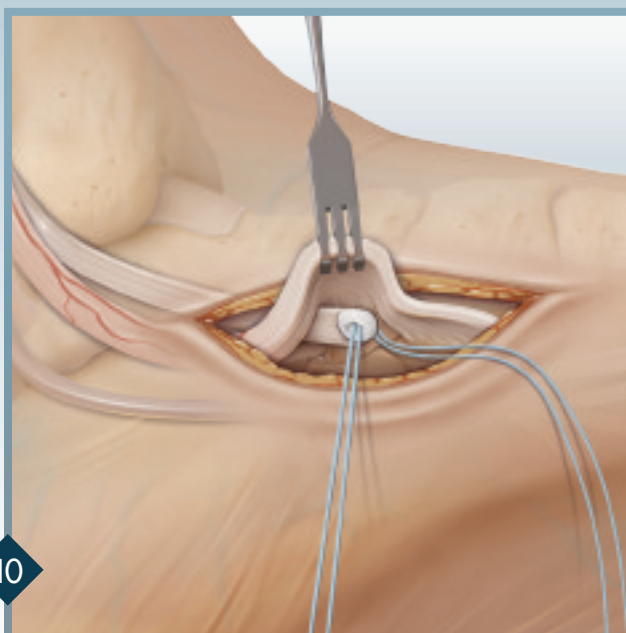


Using a #2 FiberLoop, SpeedWhip™ stitch the tendon between the two lines. Remove the tag stitch and trim up the tip of the tendon. Snare the tip of the tendon with the FiberWire loop, while maintaining maximum tension.



9

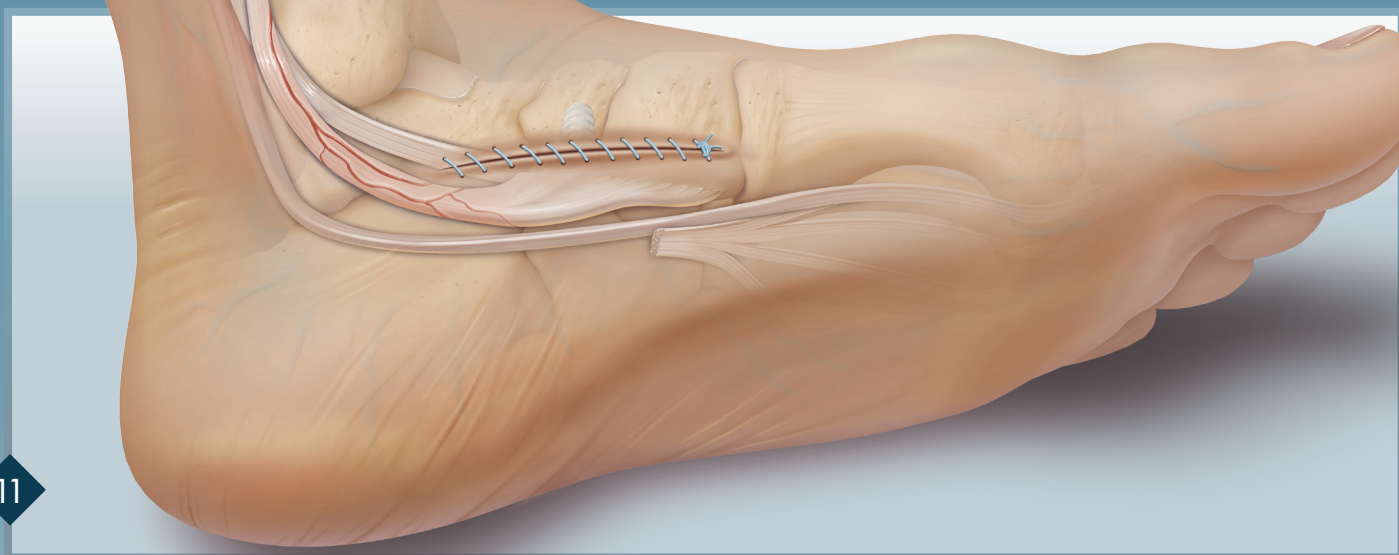
Place the driver, with the tendon, into the bone socket with the foot in maximum plantar flexion/inversion. The tip of the driver should fall easily into the bone tunnel. Correct tension can be confirmed when the initial pen marking on the tendon lines up at the bone tunnel and the proximal screw threads are in contact with the cortex. To advance the screw, turn the blue handle clockwise while holding the thumbpad stationary.



10

The screw is seated properly when it is flush with the cortical bone. Remove the driver and tie the suture tails over the top of the screw. Cut the remaining suture.

11

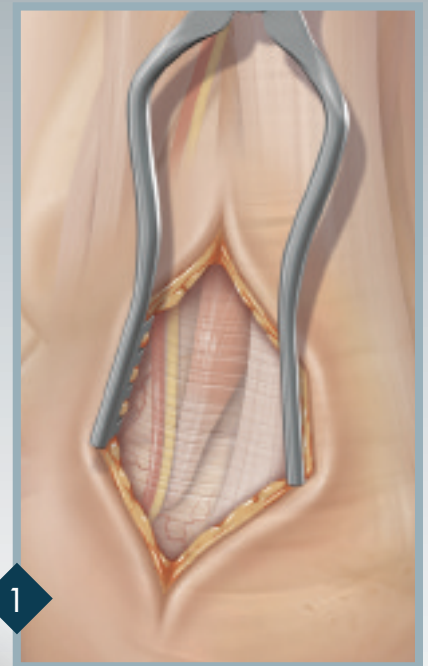
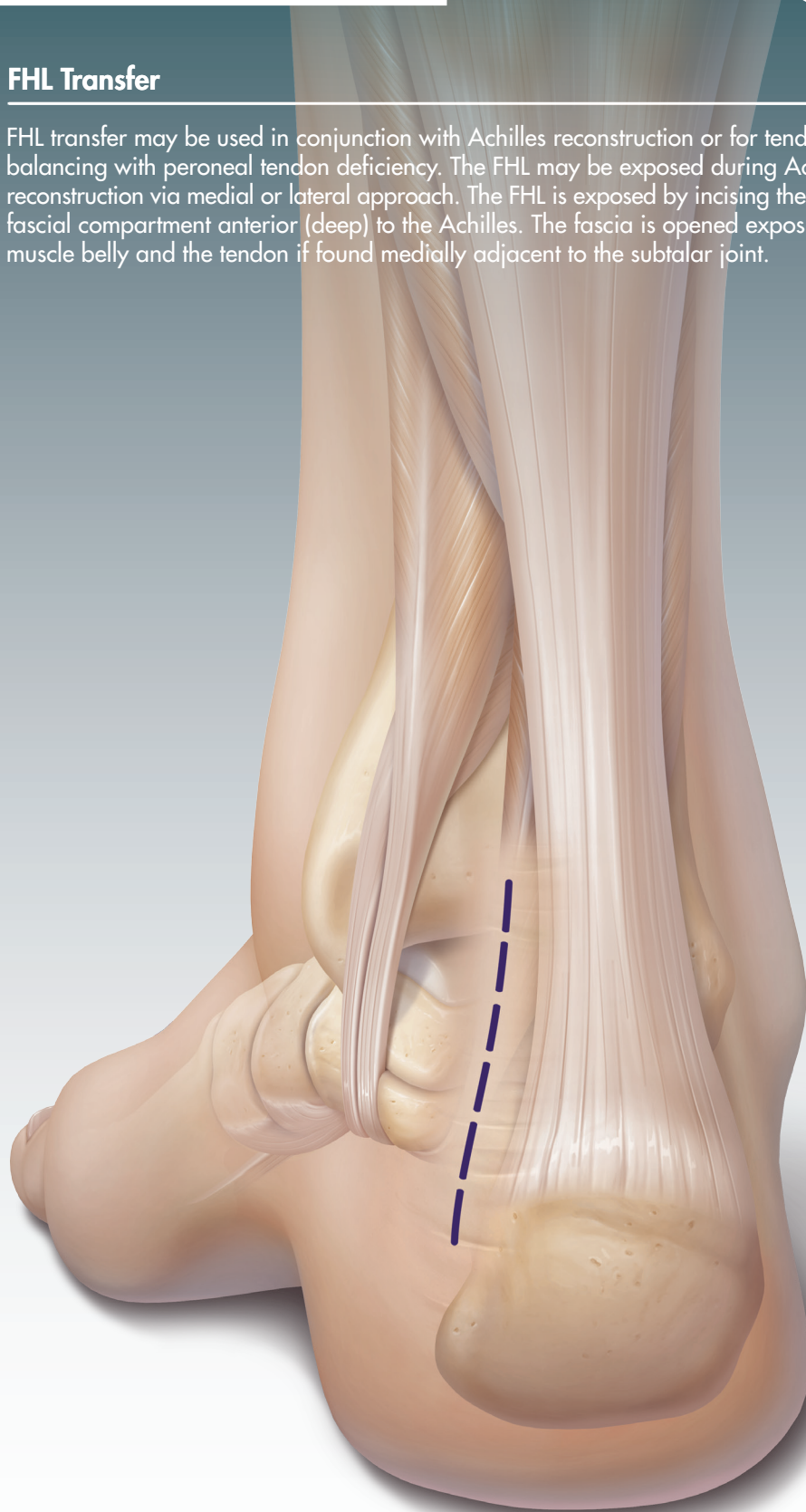


Final fixation.

Arthrex would like to thank our surgeon consultants Eugene Curry, M.D., and Paul Shurnas, M.D., who contributed to the comprehensive Tenodesis surgical technique.

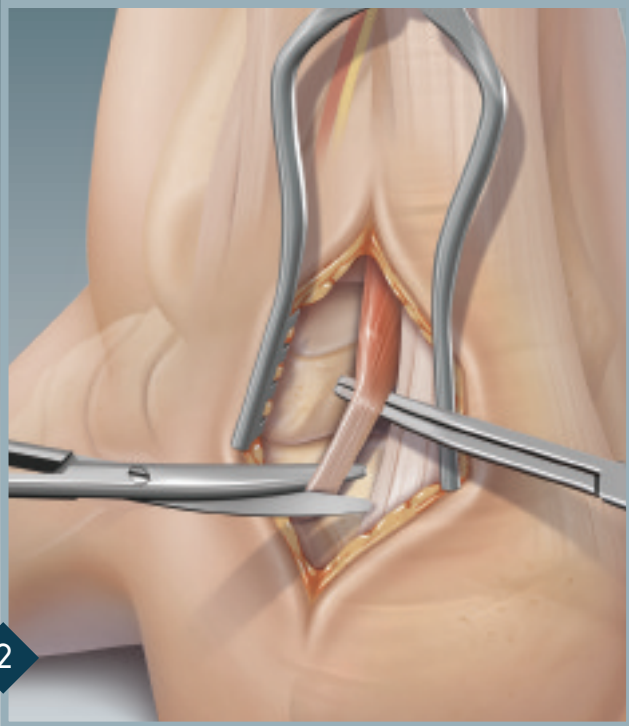
FHL Transfer

FHL transfer may be used in conjunction with Achilles reconstruction or for tendon balancing with peroneal tendon deficiency. The FHL may be exposed during Achilles reconstruction via medial or lateral approach. The FHL is exposed by incising the deep fascial compartment anterior (deep) to the Achilles. The fascia is opened exposing the muscle belly and the tendon if found medially adjacent to the subtalar joint.



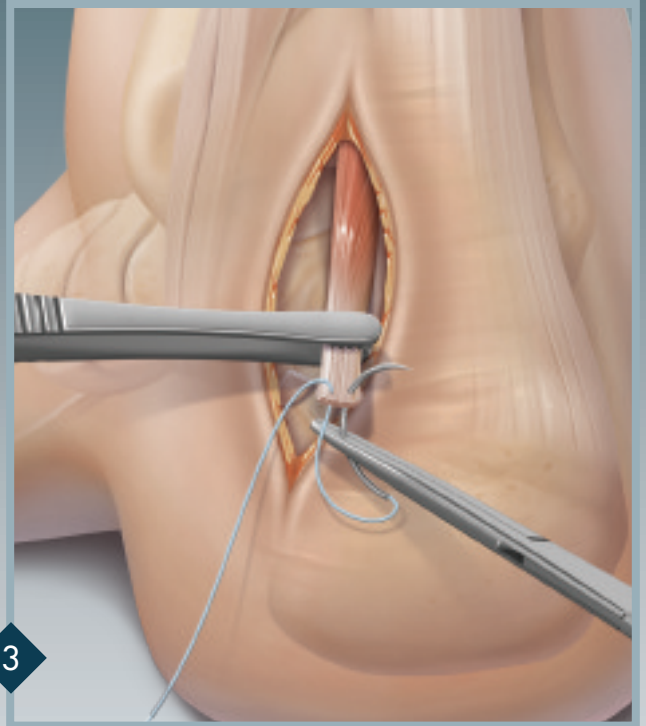
1 Make a 5 – 7 cm longitudinal incision just medial to the Achilles tendon. Deeper dissection is carried down with fine scissors through the fascia until the FHL tendon and its muscle belly are identified. The neurovascular bundle is retracted and the fibroosseous tunnel is opened to expose enough tendon.

FHL Transfer



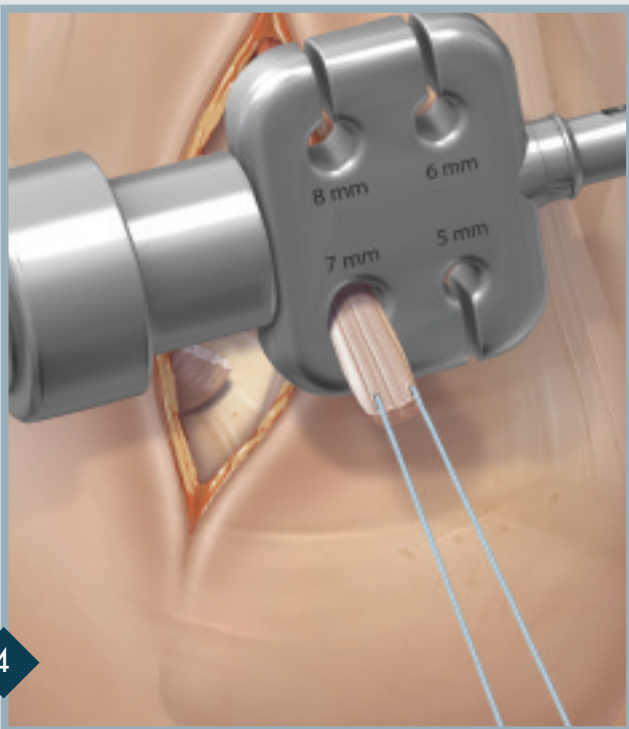
2

The FHL tendon is dissected out from the surrounding soft tissues as distally as possible and released.



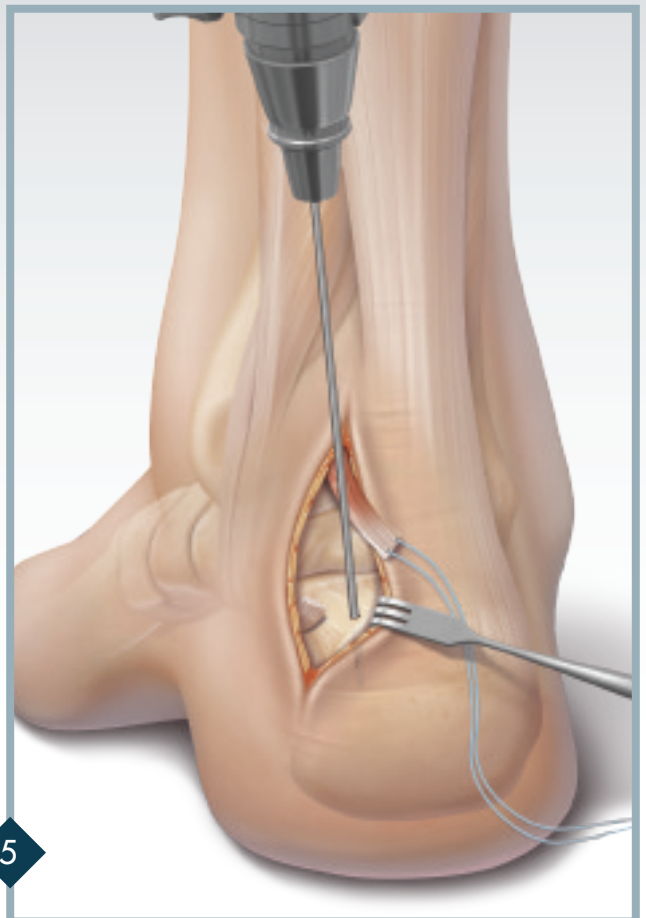
3

A traction stitch is placed through the tendon using #2 FiberWire®.



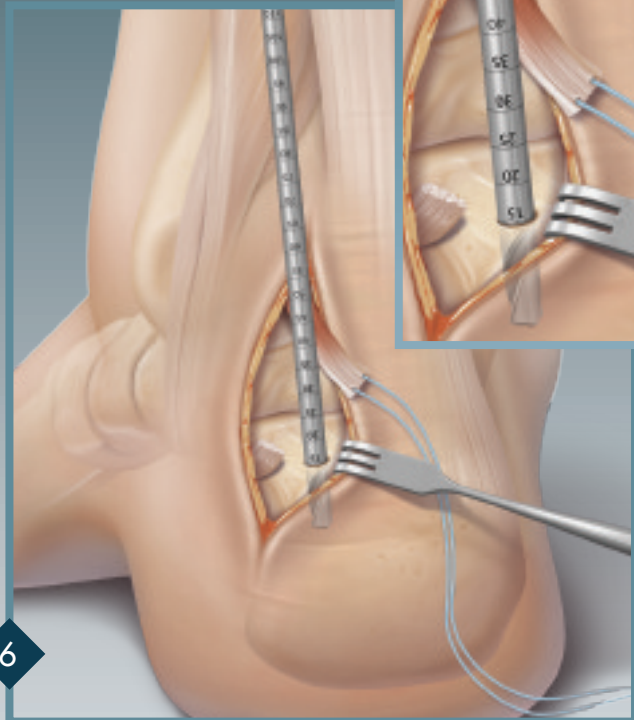
4

Use the traction stitch to size the tendon through one of the holes on the thumb pad of the driver.



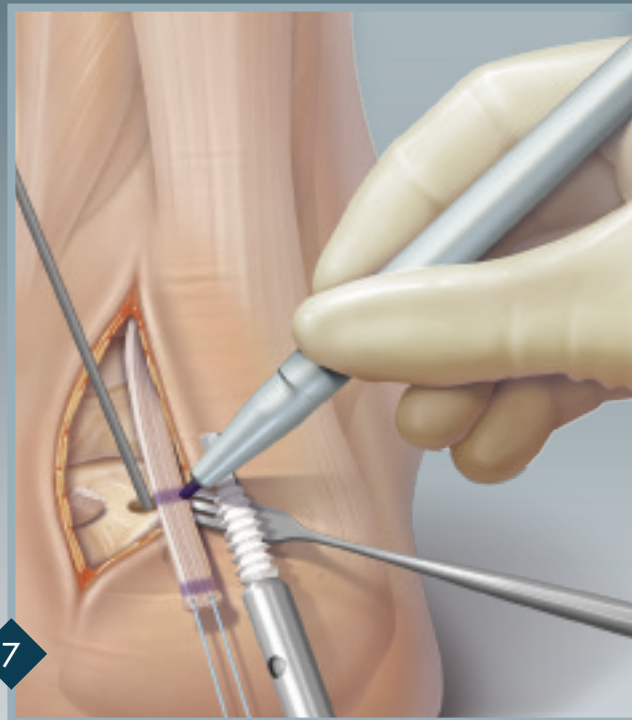
5

Place the 2.4 mm Guide Pin into the dorsal medial aspect of the calcaneus.



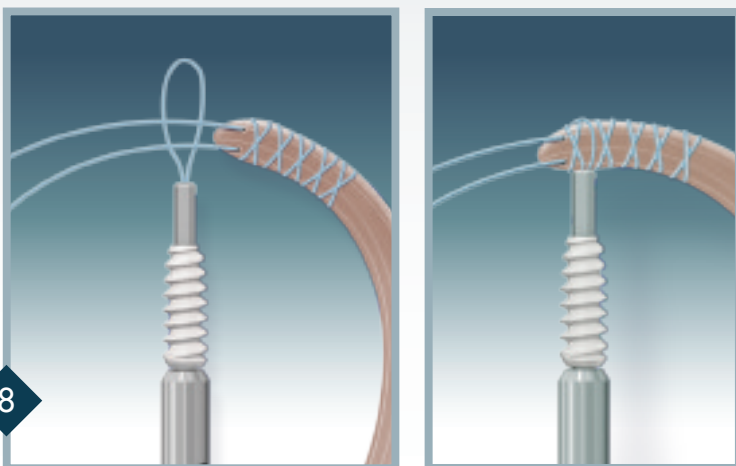
6

With a 6.5 mm tendon, ream over the Guide Pin with a 7 mm reamer 25 mm. *Note: On creation of bone tunnel, (1) Proper screw and pilot hole diameter depend on the exact diameter of the tendon graft. (2) Bone tunnel diameter should be .5 mm to 1 mm larger than the size of the tendon (ex. 6.5 mm graft requires 7 – 7.5 mm diameter hole). (3) Bone tunnel depth should be 2 mm longer than the length of the screw (7 mm x 23 mm screw = depth of 25 mm).*



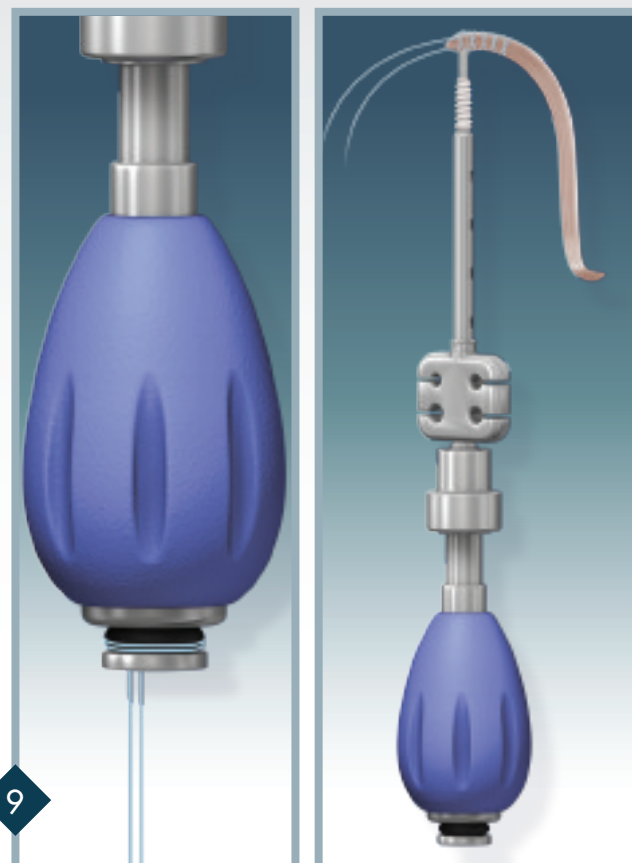
7

Plantar flex the foot and mark the tendon at the insertion of the Guide Pin, while under tension. Measure 25 mm from the pen marking on the FHL and speed whipstitch with #2 FiberLoop® between the two lines. Remove the tag stitch and trim up the tip of the tendon.

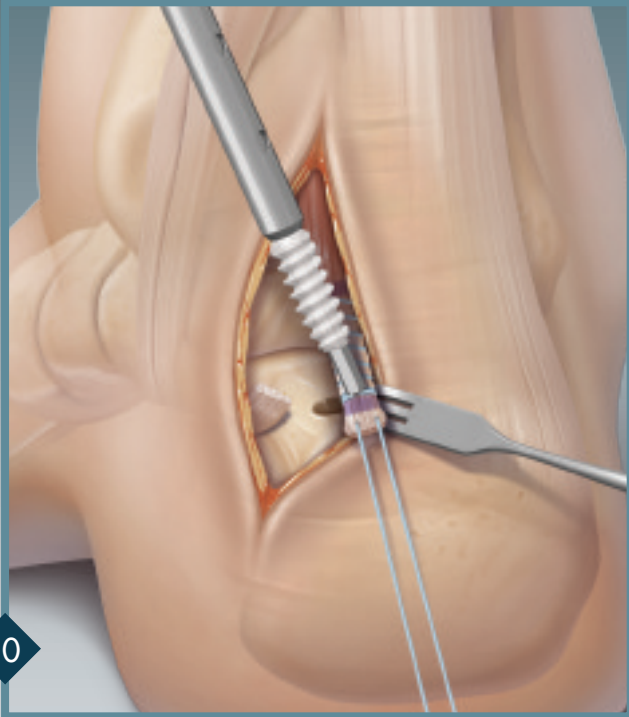


8

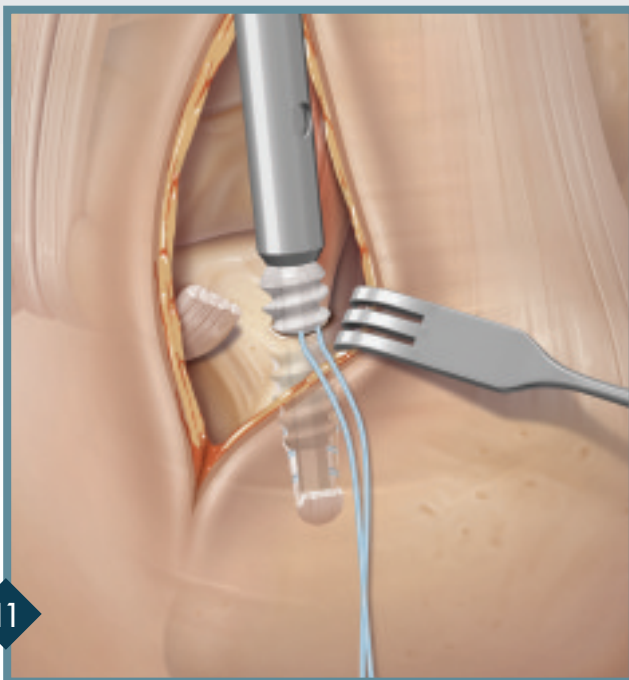
Use the Nitinol wire and #2 FiberWire to create a suture loop at the tip of the Bio-Tenodesis Driver. Snare the tip of the whipstitched tendon. Place tension on the sutures exiting the back of the Tear Drop Handle and wrap them once around the O-ring inside the cleat. It is important to maintain maximum tension between the driver tip and the tendon during initial placement of the tendon in the tunnel.



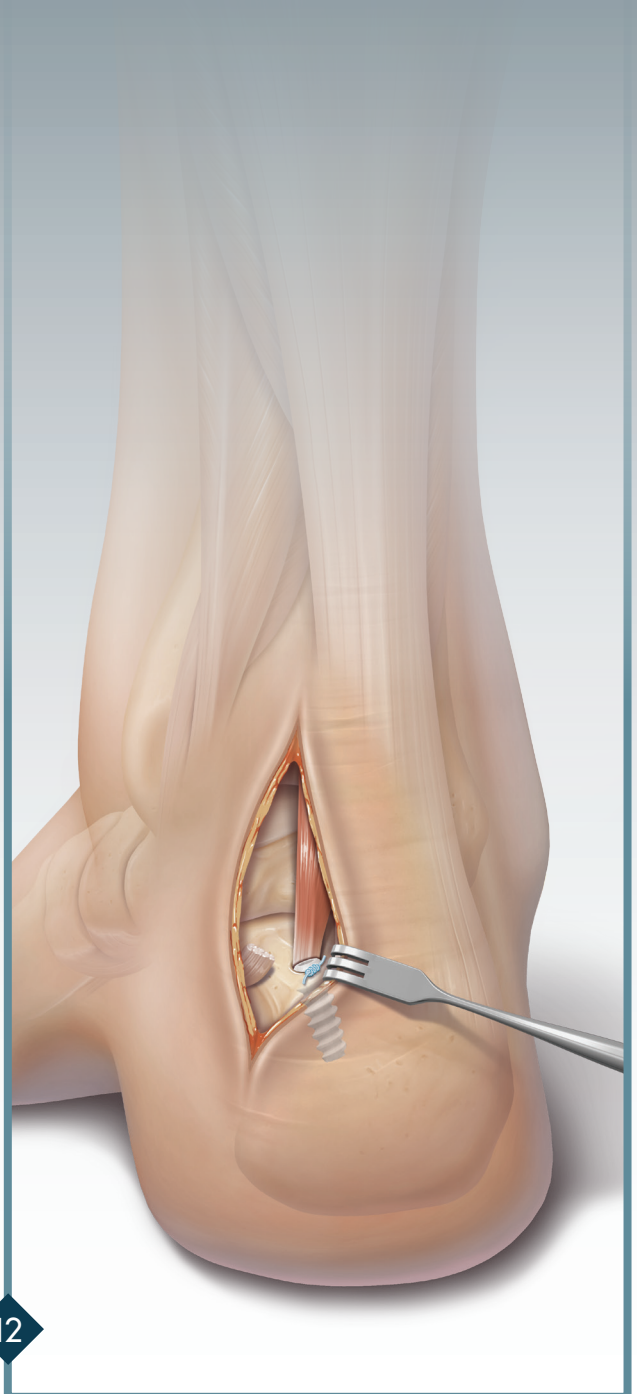
9



Snare the tip of the whipstitched tendon and place the driver into the bone tunnel. The tip of the driver should fall easily into the bone tunnel and proper tension can be confirmed when the initial pen marking on the tendon lines up at the opening of the bone tunnel and the proximal screw threads are in contact with the cortex. If the driver does not fall easily into the bone tunnel, remove the driver and trim up the tip of the tendon or ream with a larger reamer.



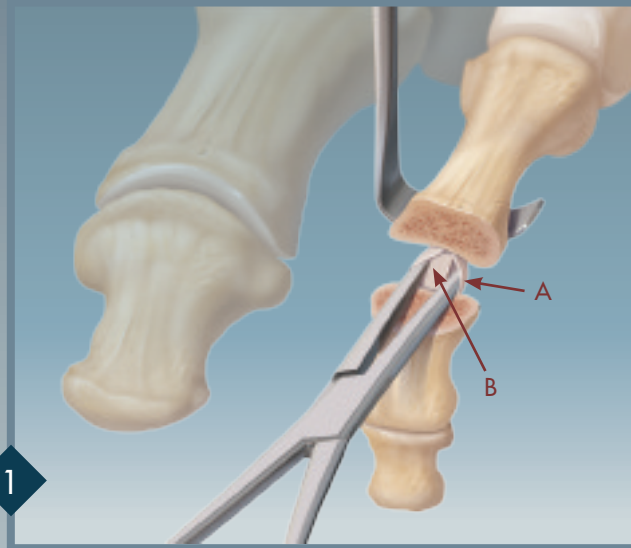
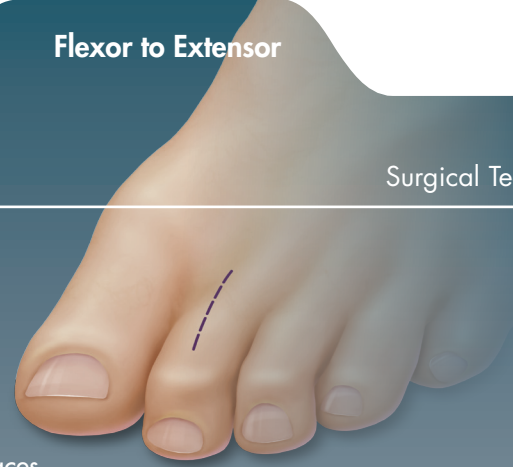Turn the blue handle clockwise while holding the metal thumb pad stationary. The screw is seated properly when it is flush with the cortical bone. Remove the driver and tie the suture tails over the top of the screw. Cut the remaining suture.



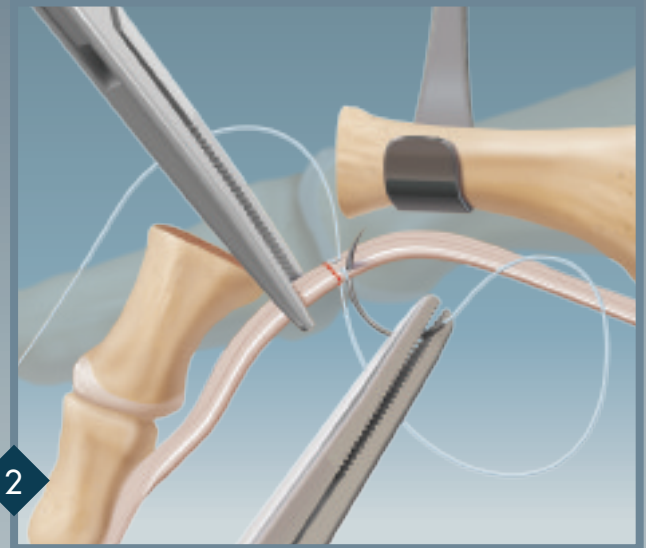
Final fixation.

Flexor to Extensor

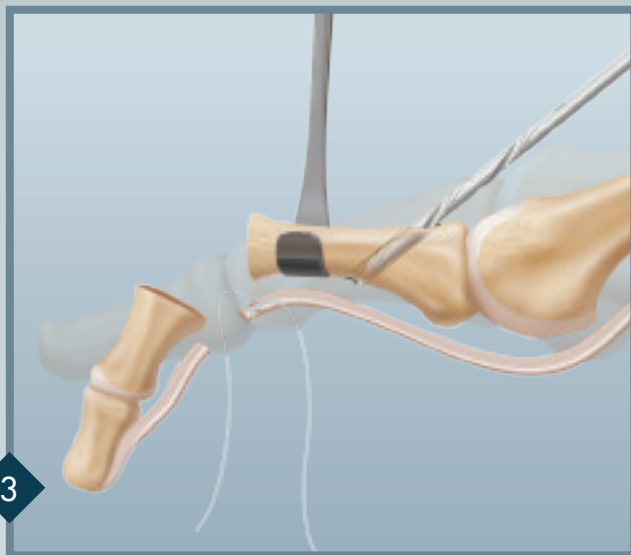
Hammertoe repair is performed when any fixed deformity is present. This is often the case with 2nd MTP joint subluxation or dislocation. When the phalanx base rides dorsal to the metatarsal head, a flexor transfer is performed. The drill hole in the proximal phalanx base is made in the dorsal metaphyseal diaphyseal junction to allow adequate bone stock for the transfer tunnel and 3 mm x 8 mm Tenodesis Screw fixation. The phalanx base is reduced to a level position with respect to the metatarsal head by tensioning the flexor transfer until the bony surfaces are aligned.



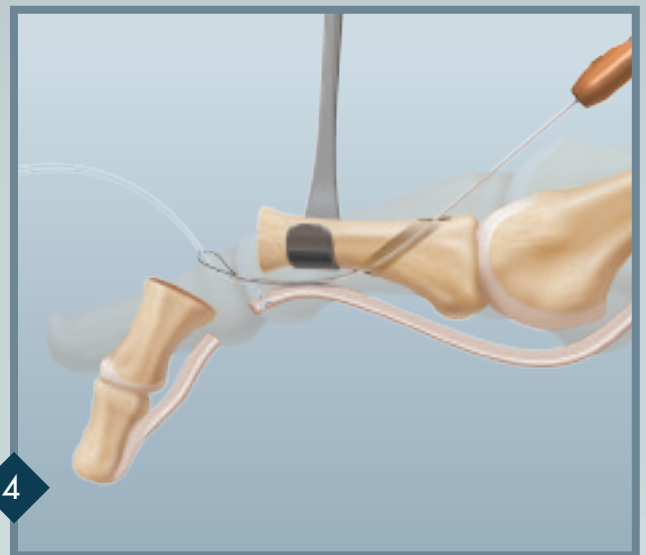
The articular cartilage of the head of the proximal phalanx and base of the middle phalanx are resected. The short flexor tendons (A) can be seen just below the retractor. Using blunt dissection, the short flexors are separated and the long flexor (FDL) is exposed (B).



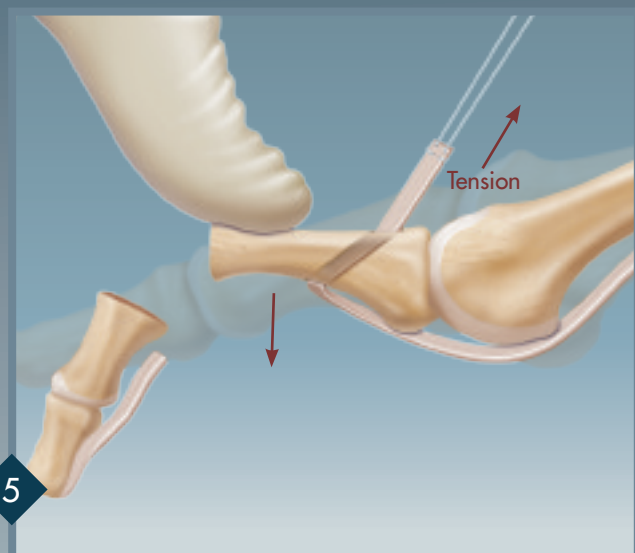
The long flexor is clamped and a traction stitch is added, using 2-0 FiberWire®. The stitch aids passage of the tendon from plantar-to-dorsal through the bone tunnel in the proximal phalanx. The long flexor is cut between the clamp and the traction stitch, as shown with the red line. Tendon diameter should be estimated for the drilling phase to follow.



Based on the tendon diameter, a 2.5 mm or 3 mm drill is selected. An angled drill hole is made at the base of the proximal phalanx. The oblique drill hole should be made from proximal to distal, and should start not more than 5 mm distal to the MTP joint and exit at the bottom of the phalanx.
Note: Cannulated and noncannulated drills are available for this procedure.

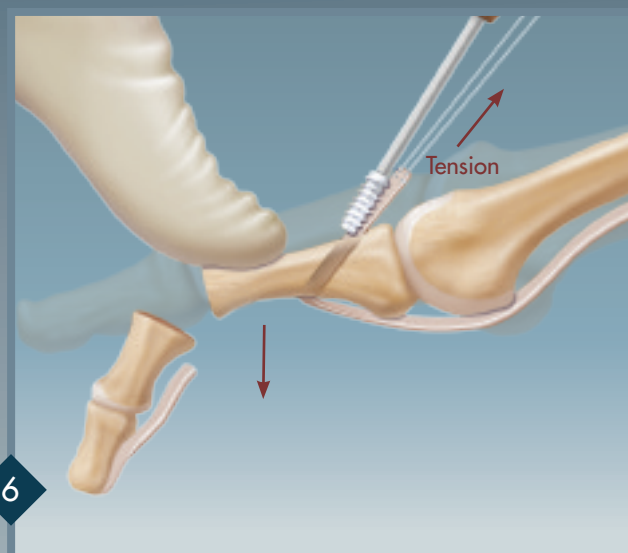


Clear any impinging soft tissues away from the shaft of the phalanx to aid passage of the tendon. A Nitinol wire loop or a Micro SutureLasso™ is placed in the bone tunnel and directed toward the exposed osteotomy. The Nitinol wire loop is used to snare the FiberWire traction stitch. Once the traction suture is passed through the bone tunnel, the tendon is pulled dorsally through the drill hole. *Note: The tendon tip must be properly sized and tapered for easy passage through the tunnel.*



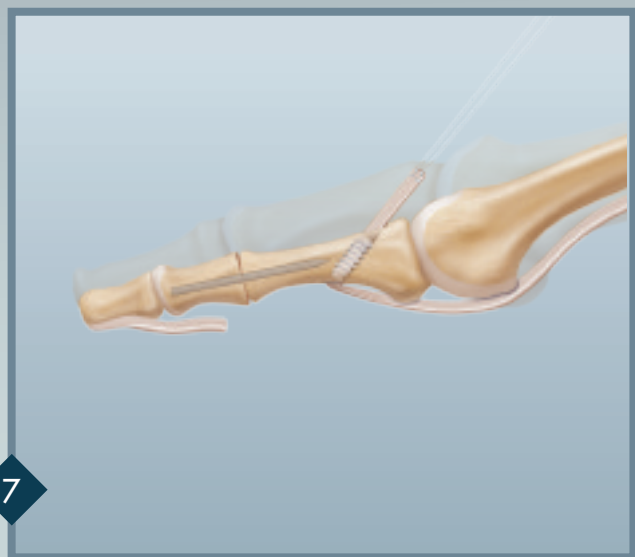
5

The proximal phalanx is pushed down to reduce the MTP joint. The tendon should be tensioned as needed to keep the toe in its normal anatomic position.



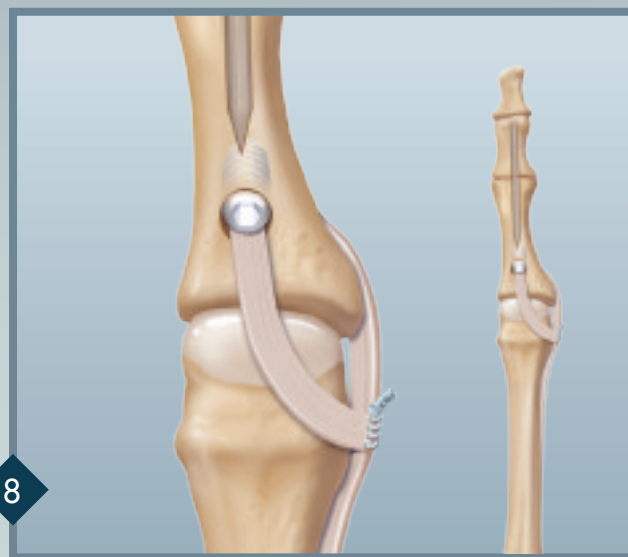
6

The Tenodesis Screw is used to secure the tendon.



7

Hammertoe repair by insertion of a TRIM-IT Drill Pin® or metal K-wire, retrograde from the tip of the toe, is added for stabilization.



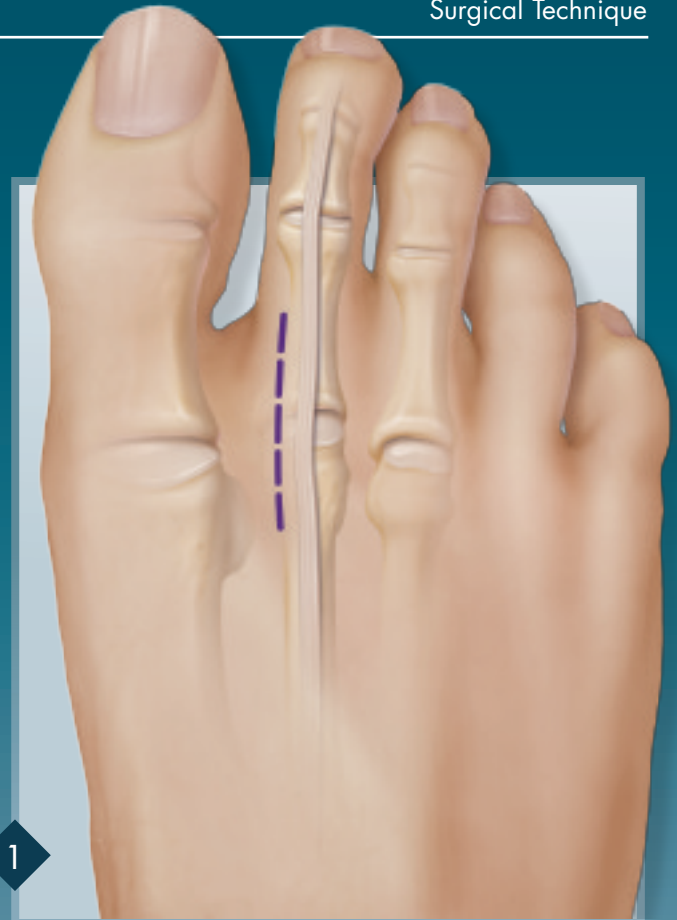
8

Repair is complete. The medial or more typically lateral capsule soft tissues and ligaments can be repaired with 2-0 or 4-0 FiberLoop®.

FDL/EDL Transfer – Plantar Approach

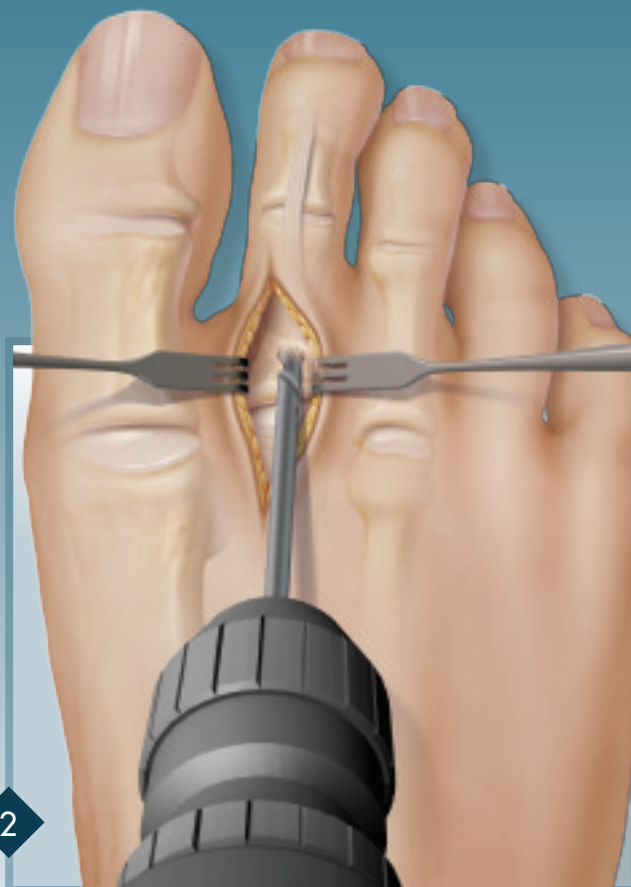
Surgical Technique

When a capsular instability is present without a hammertoe or clawtoe deformity, the FDL tendon must be harvested via the plantar approach.



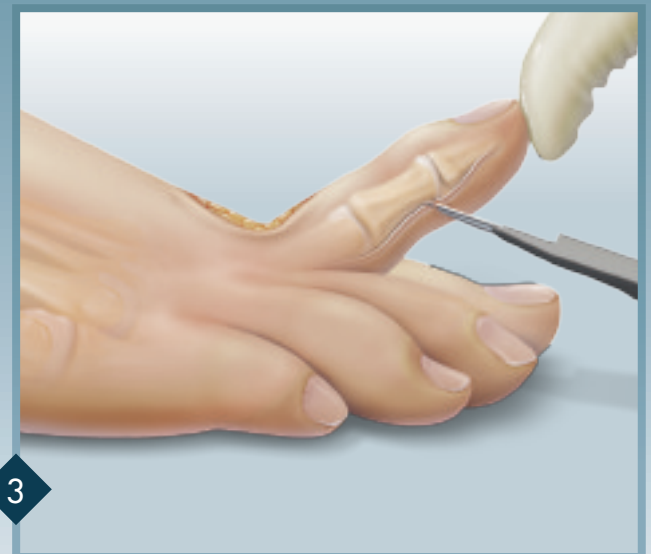
1

A dorsal incision is made over the 2nd MTP joint, preferably just medial or lateral to the EDL tendon. The location is often dictated by the concurrent procedures performed (e.g. distal soft tissue release for hallux valgus repair would call for an incision medial to the 2nd EDL tendon; procedures on multiple MTP joints would require incisions in the web spaces). The base of the proximal phalanx is exposed and angled slightly distal.



2

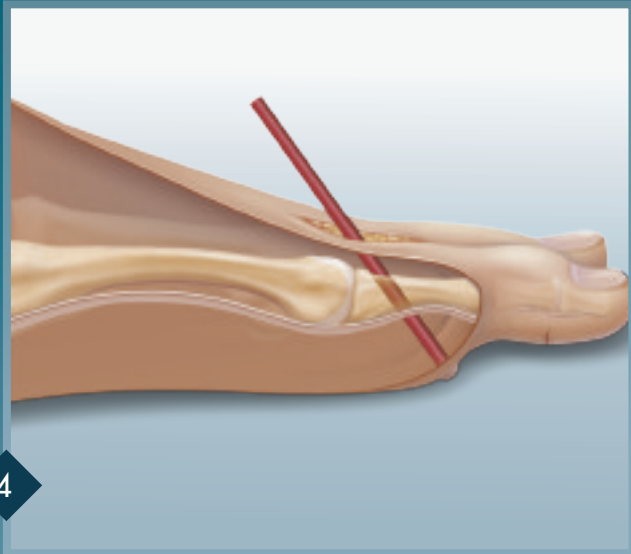
The starting point for the drill hole is 3 – 4 mm distal to the articular surface of the base of the proximal phalanx. A 3 mm drill hole is made in the proximal phalanx. If the bone quality is poor, use a 2.5 mm drill bit.



3

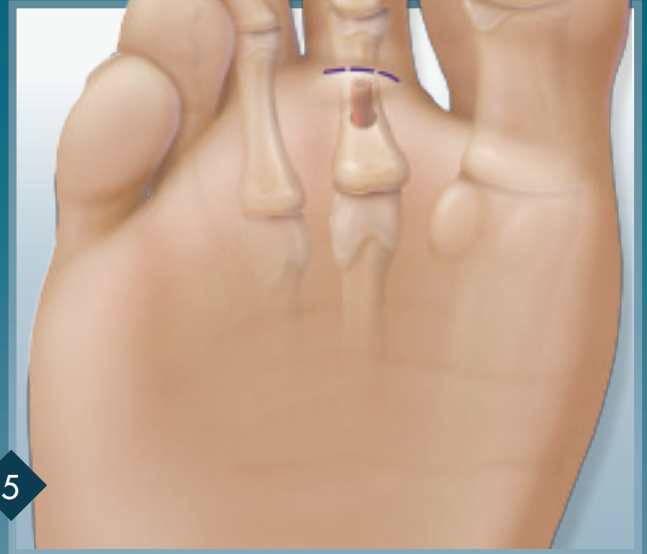
The toe is maximally dorsiflexed, thus tensioning the FDL tendon. The FDL tendon is transected at the distal plantar skin crease percutaneously. Avoid directing the knife blade too distally to prevent cutting the plantar capsule of the DIP joint. This can lead to hyperextension at that joint.

FDL/EDL Transfer – Plantar Approach



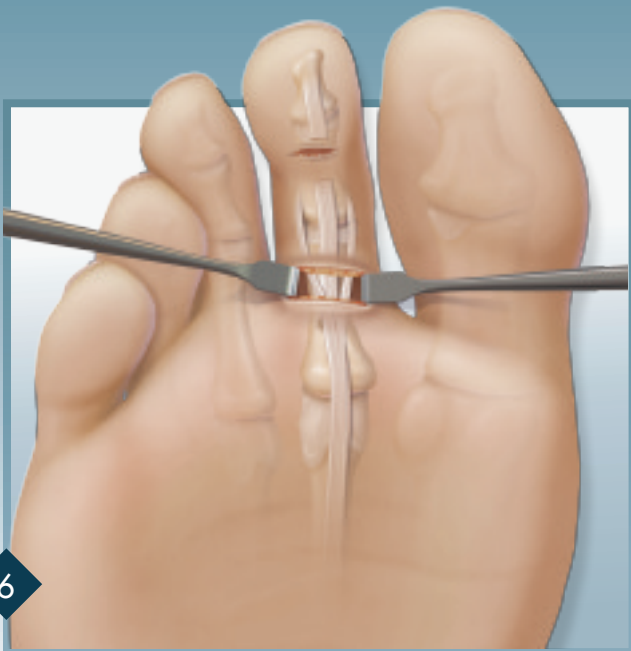
4

Insert the red plastic tube containing the Nitinol wire loop through the drill hole. Push down to identify the site of the plantar incision used to retrieve the FDL tendon. The incision will be typically located about 1 cm proximal to the MTP crease of the toe.



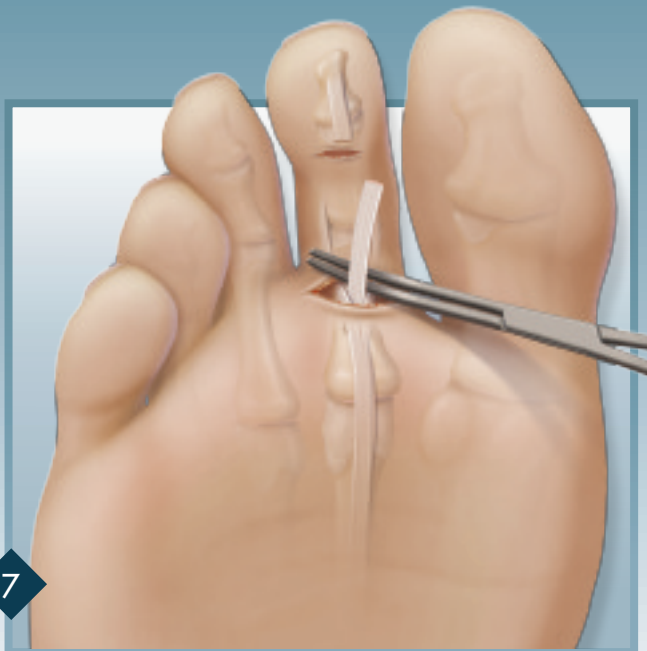
5

Make a 10–15 mm transverse incision on the plantar surface of the foot directly over where the red plastic tube was identified.



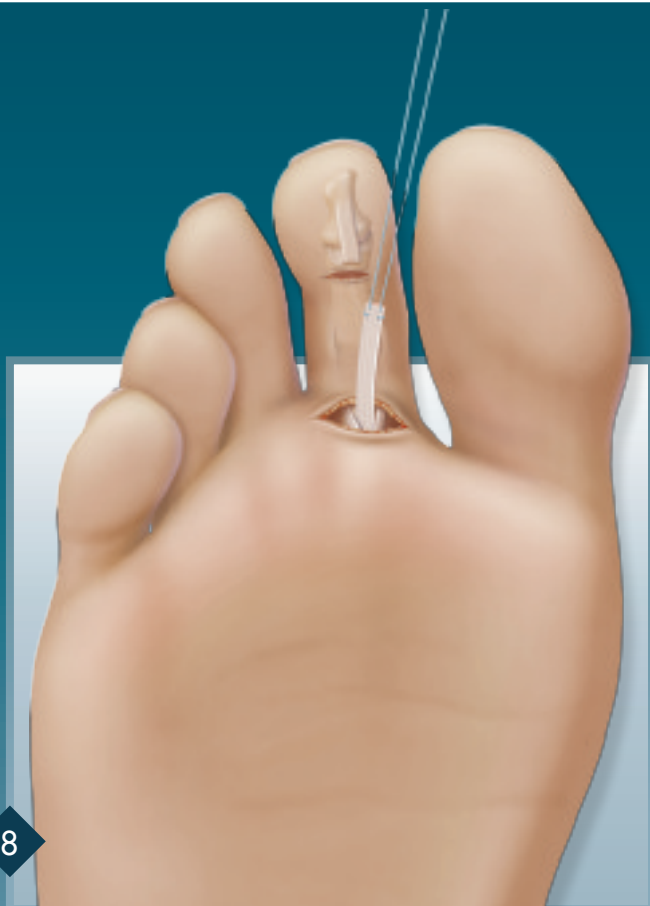
6

Use blunt dissection to locate the FDL/FDB tendon sheath. In patients with a crossover toe deformity the sheath may be subluxated medially. Make a vertical incision in the tendon sheath.



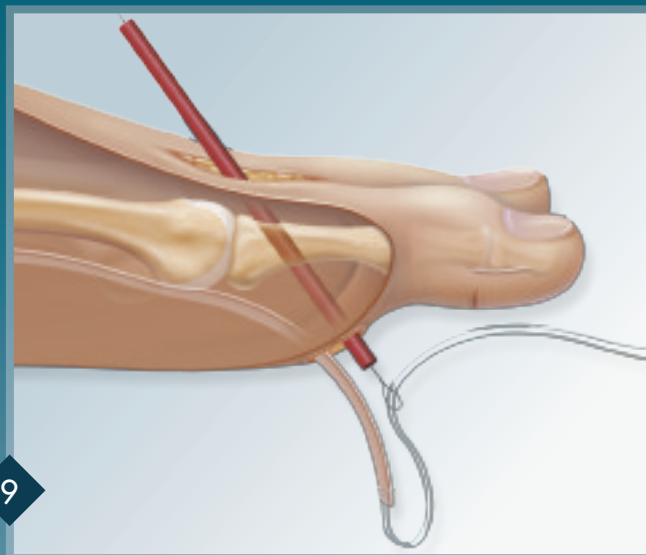
7

Use a small (mosquito) hemostat to locate the FDL tendon between the two limbs of the FDB tendon. Hook the FDL tendon with the curved hemostat and retrieve it, pulling it out of the incision site. If there is any difficulty in pulling the tendon out, it may still be partially attached distally—use the knife blade to completely transect it in the distal incision.



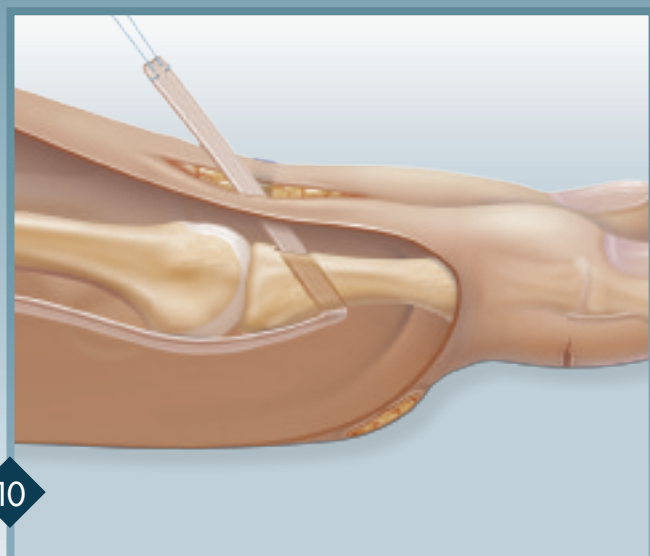
8

Whipstitch the FDL tendon with a 4-0 FiberWire® suture.



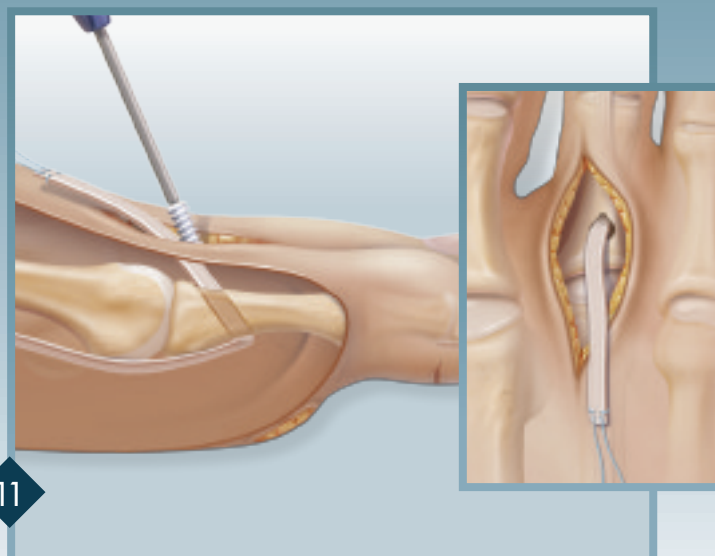
9

Pass the red plastic tube with Nitinol wire loop from dorsal to plantar direction through the drill hole. Make sure the tube passes between the two limbs of the FDB tendon and not medial or lateral to them. Push the Nitinol wire loop out and pull the suture ends through the loop.



10

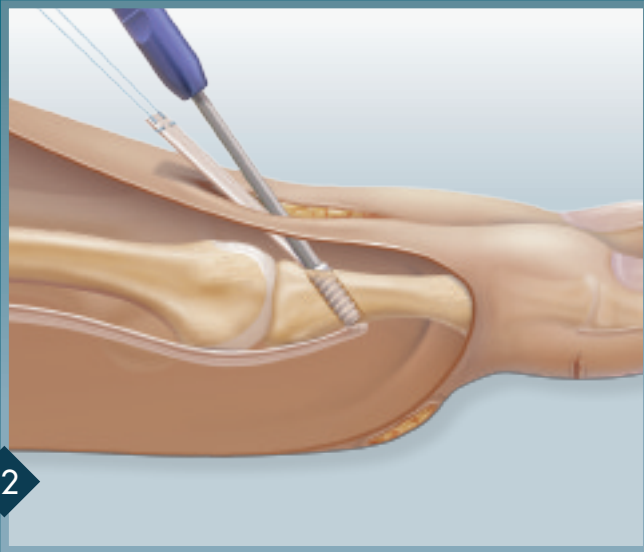
Retrieve the FDL tendon through the drill hole. If there is difficulty pulling the tendon through the hole, check the end of the tendon for any untrimmed edges. If the 2.5 drill was used to create the hole in the proximal phalanx, occasionally it is necessary to over-drill with a 3 mm drill bit to facilitate the passage of the tendon.



11

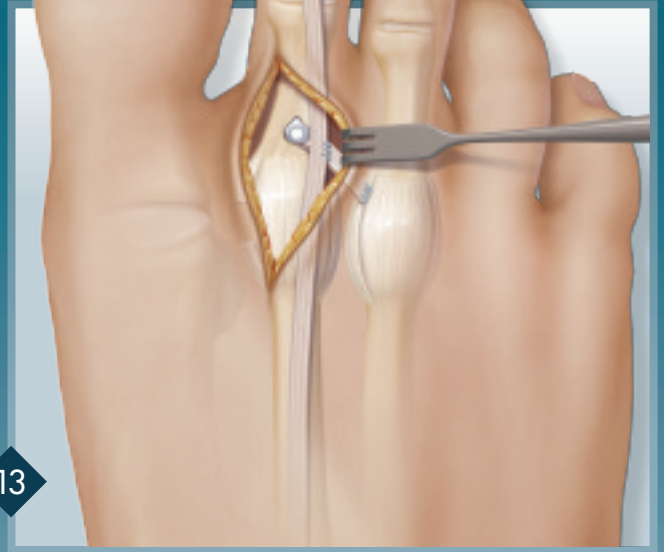
Tension the tendon, while pushing the proximal phalanx down. Insert the 3 x 8 mm Bio-Tenodesis Screw into the drill hole. If there is difficulty introducing the screw into the drill hole, use a small rongeur to notch the drill hole at the 12 o'clock position.

FDL / EDL Transfer – Plantar Approach



12

Tighten the screw; do not remove the blue inserter yet. Check the tension of the repair by dorsiflexing the toe. If there is too much plantar flexion of the toe with the ankle fully dorsiflexed, back out the screw. Readjust tension on the FDL tendon and reinsert the screw. Remove the inserter.



13

If there is a crossover toe deformity with (typically) medial toe deviation, release the medial contracted capsule and ligaments. Attach the remaining FDL tendon portion to the lateral capsule of the 2nd MTP and the medial capsule of the adjacent MTP joint.

Arthrex would like to thank our surgeon consultant Eugene Curry, M.D., who contributed to the comprehensive Tenodesis surgical technique.

This description of technique is provided as an educational tool and clinical aid to assist properly licensed medical professionals in the usage of specific Arthrex products. As part of this professional usage, the medical professional must use their professional judgment in making any final determinations in product usage and technique. In doing so, the medical professional should rely on their own training and experience and should conduct a thorough review of pertinent medical literature and the product's Directions For Use.



www.arthrex.com

*... up-to-date technology
just a click away*