

ISSUE 05

# ShARC BITE

GLENOSPHERE OVERHANG IN REVERSE TSA

Released January 2025



---

## Mission Statement

The Shoulder Arthroplasty Research Committee (ShARC) is a forward-looking global collaboration among research-focused surgeons of which the primary goal is to advance patient care. The ShARC Patient Registry is utilized to conduct patient monitoring, inform evidence-based implant design, and allow for the integration of novel technologies into clinical practice. Supported by Arthrex, the ShARC will continue to have tremendous influence on the advancement of shoulder arthroplasty through innovative research and a commitment to improve patient outcomes.

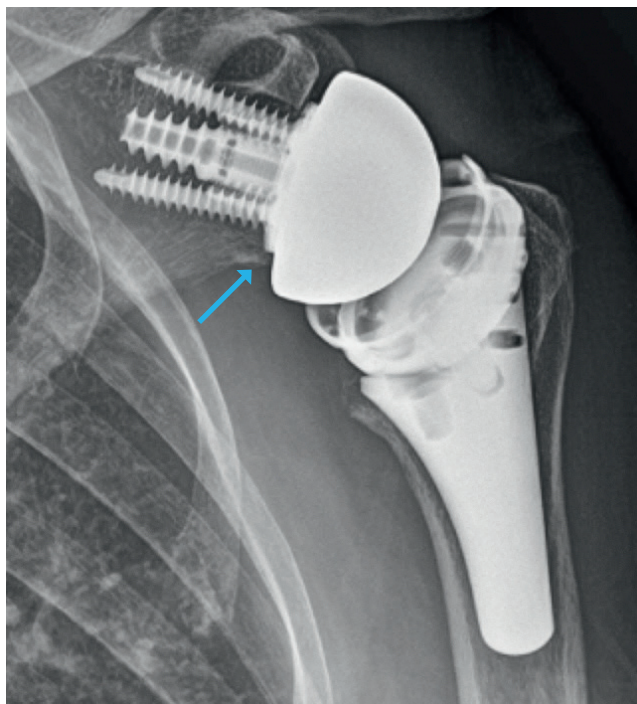
**ShARC Bites** are developed through registry data analysis and processing of the committee's preferences, cross-referenced with available ShARC and non-ShARC publications, to provide recommendations on current techniques and implants.

---

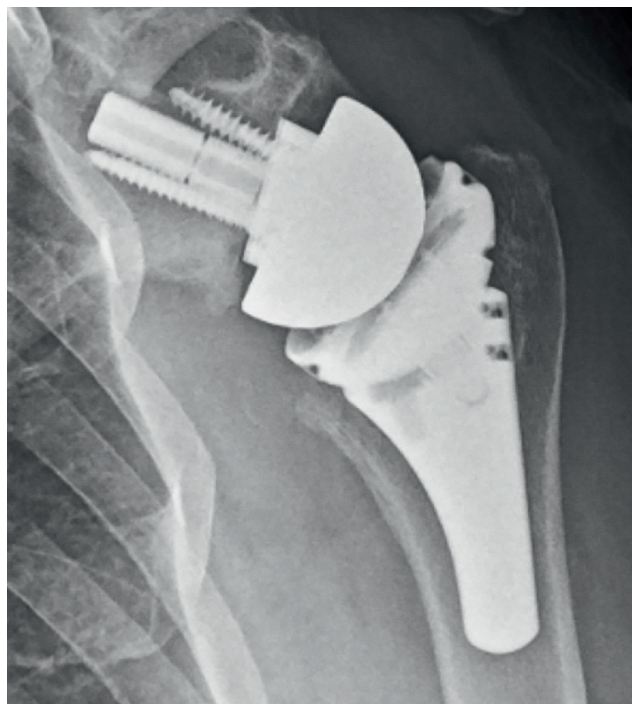
## Summary Recommendation

In reverse total shoulder arthroplasty, 93% of ShARC members prefer 0 to 2 mm of inferior glenosphere overhang. Previous work has shown that inferior overhang seems to improve outcomes but also increases the risk of stress fracture. As such, we may want to strive for inferiorly flush positioning, erring on the side of minimal inferior overhang if needed. Additionally, 78% of ShARC members preferred the glenosphere to be either flush or have 1 mm of over-coverage with the glenoid in the A-P direction. This practice is supported by recent evidence from the ShARC demonstrating that an increased subcoracoid distance, which is directly affected by glenosphere sizing, is ideal to optimize internal rotation and reduce anterior shoulder pain after RTSA.<sup>1</sup>

### Construct Comparison



Glenosphere Overhang



Inferiorly Flush Glenosphere

## Background

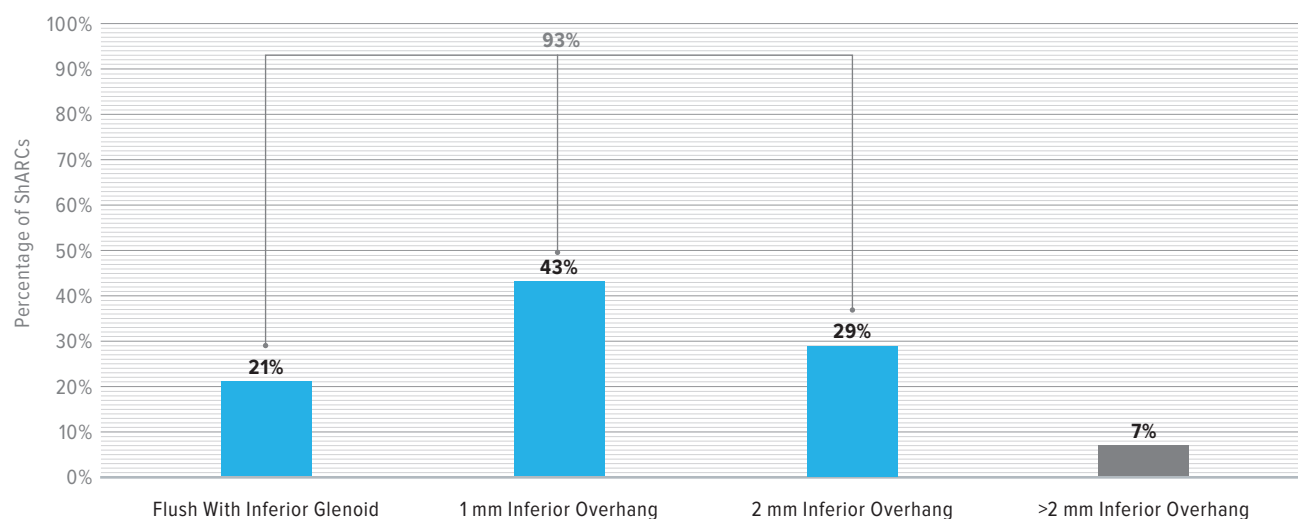
The ideal glenoid to glenosphere positioning in reverse total shoulder arthroplasty (RTSA) remains elusive. While most surgeons agree that inferior baseplate placement on the glenoid is preferred, it is unclear where the proper positioning of the glenosphere should be to maximize range of motion (ROM) and minimize complications.<sup>2</sup> An earlier study using different implants has found that a greater amount of inferior overhang (>9.9 mm vs <7.1 mm) correlated to a significantly greater amount of active forward elevation.<sup>3</sup> Another study showed that a greater amount of inferior overhang (3.1 mm vs 1.4 mm) demonstrated improvement in ROM and clinical outcome scores.<sup>4</sup> In the previous study, for every 1 mm increase in inferior glenosphere overhang, there was a 1.5× increase in the chance of achieving an excellent outcome. However, these findings should be considered alongside those of Pak et al, who found that increased inferior overhang increases the risk of stress fracture.<sup>5</sup>

## Data

When the ShARC members were surveyed on the ideal amount of inferior glenosphere overhang in RTSA, there was no consensus among the group. Overall, **93% preferred the glenosphere to have 2 mm of overhang or less**; 21% preferred the glenosphere to be flush; 43% preferred 1 mm of inferior overhang; and 29% preferred 2 mm of inferior overhang. Only 7% wanted more than 2 mm of inferior overhang.

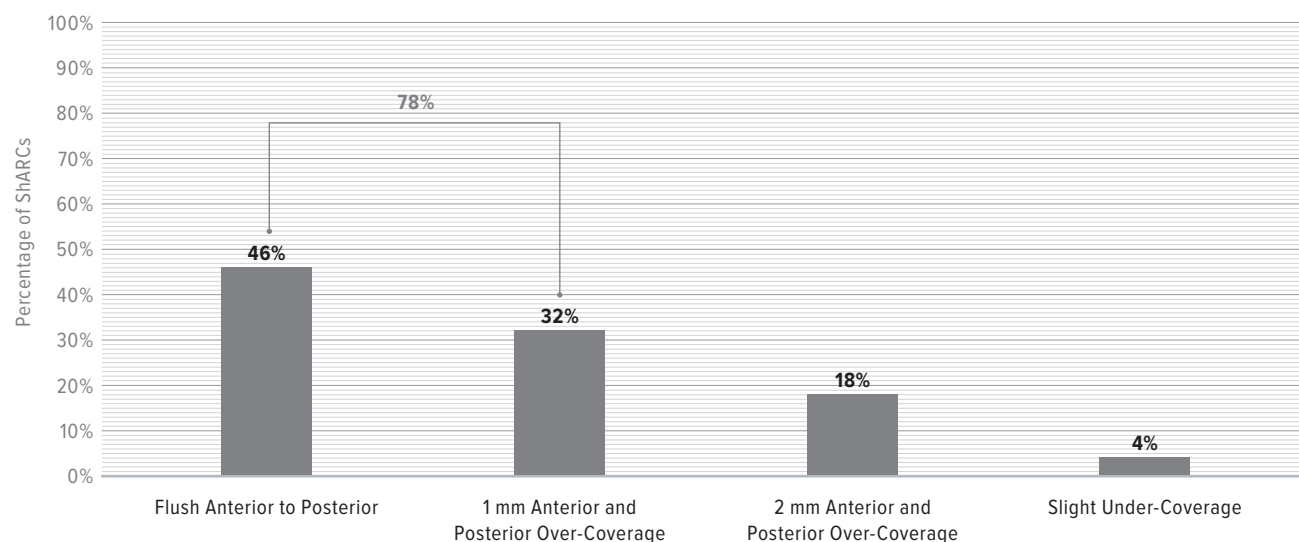
When surveyed on the anterior to posterior (A-P) coverage of the glenosphere, most ShARC members preferred the glenosphere to be flush with the glenoid A-P (46%) or have 1 mm of A-P over-coverage (32%). Fewer preferred 2 mm of A-P over-coverage (18%) and only 4% wanted slight under-coverage.

### Ideal Inferior Glenosphere Overhang





## Ideal Anterior/Posterior Glenosphere Overhang



## References

1. Klosterman EL, Tagliero AJ, Lenters TR, et al. The subcoracoid distance is correlated with pain and internal rotation after reverse shoulder arthroplasty. *JSES Int.* 2024;8(3):528-534. doi:10.1016/j.jseint.2024.01.010
2. Collotte P, Bercik M, Vieira TD, Walch G. Long-term reverse total shoulder arthroplasty outcomes: the effect of the inferior shifting of glenoid component fixation. *Clin Orthop Surg.* 2021;13(4):505-512. doi:10.4055/cios20245
3. Dean EW, Dean NE, Wright TW, et al. Clinical outcomes related to glenosphere overhang in reverse shoulder arthroplasty using a lateralized humeral design. *J Shoulder Elbow Surg.* 2022;31(10):2106-2115. doi:10.1016/j.jse.2022.03.014
4. Haidamous G, Ladermann A, Hartzler RU, et al. Radiographic parameters associated with excellent versus poor range of motion outcomes following reverse shoulder arthroplasty. *Shoulder Elbow.* 2022;14(1):39-47. doi:10.1177/1758573220936234
5. Pak T, Ardebol J, Menendez ME, et al. Robert H. Cofield, MD, Award for Best Oral Presentation 2023: Up to 8 mm of glenoid-sided lateralization does not increase the risk of acromial or scapular spine stress fracture following reverse shoulder arthroplasty with a 135° inlay humeral component. *J Shoulder Elbow Surg.* 2024;33(6S):S1-S8. doi:10.1016/j.jse.2023.11.018



View the ShARC  
Publication List

**ShARC**  
Shoulder Arthroplasty Research Committee

