

An anatomical illustration of a human hand and wrist joint, viewed from the dorsal (back) perspective. The bones, including the metacarpals, phalanges, and carpal bones, are rendered in a realistic, light brown color. A blue, woven bandage is wrapped around the wrist, secured with a small black device. The bandage is positioned over the distal radius and ulna. The background is a solid light gray. The word 'Art' is partially visible in the bottom right corner.

Surgical Technique



Lisfranc Fixation System for *InternalBrace*™ Repair

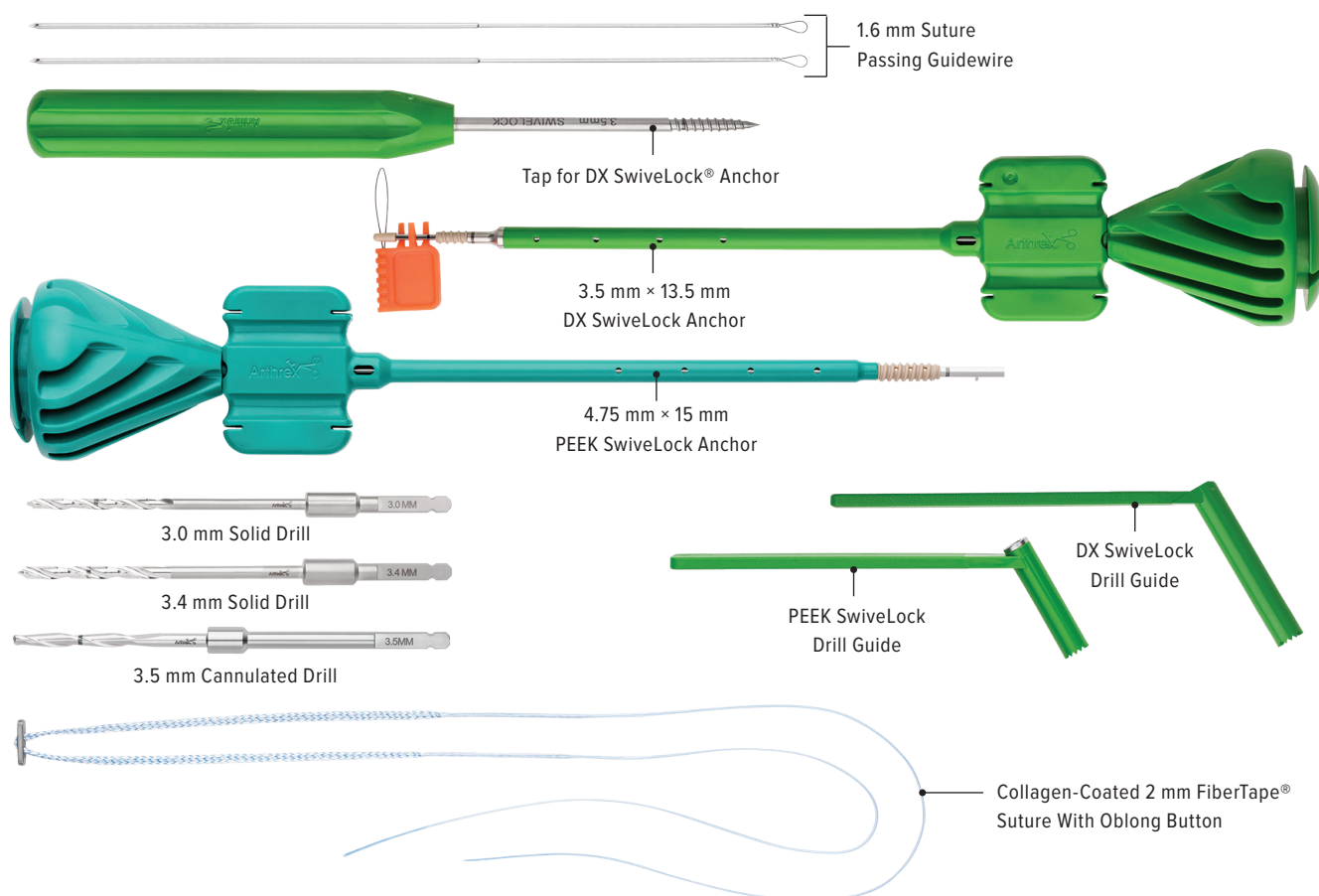
Low-energy, purely ligamentous injuries of the Lisfranc complex in young adults and high-level athletes can be difficult to treat. The demands of this population are such that the standard of care with screw fixation and/or fusion is not well tolerated, placing this group at a higher risk for posttraumatic arthritis and complications such as hardware breakage and failure.¹

The novel Lisfranc fixation system for *InternalBrace* repair is designed to provide both immediate construct stability and postoperative injury protection throughout the healing process.

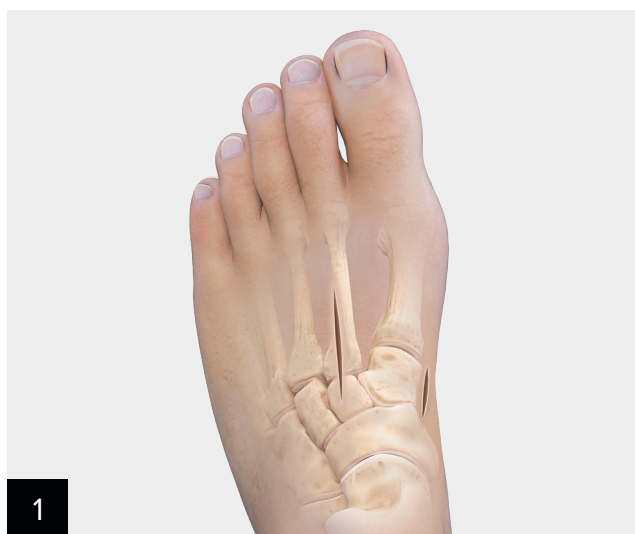Additionally, unlike conventional fixation methods that require a secondary surgery for hardware removal, the Lisfranc fixation system allows for natural motion, minimizing the risk of hardware failure and avoiding a second surgery.

Lisfranc Fixation System Advantages:

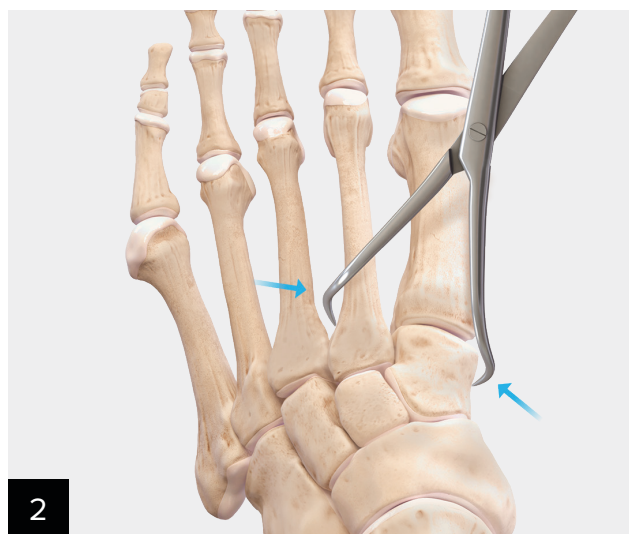
- Robust construct stability is equivalent to a native, intact Lisfranc complex.²
- Reduced risk of broken hardware³ means less likelihood for secondary surgery to remove hardware.⁴
- May prevent excess range of motion during the healing phase and may reduce the chance of secondary injury.²
- 1.6 mm bone prep minimizes disturbance to the healing ligaments and attachment site as compared to 3.2 mm predrilling for a 4.5 mm Lisfranc screw.⁵



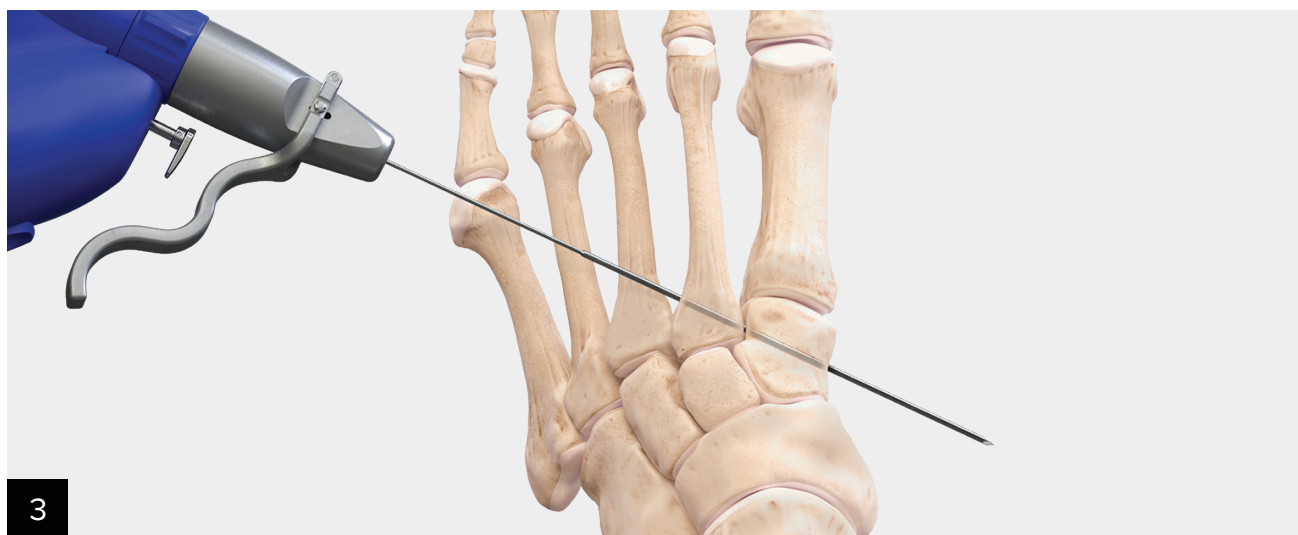
The *InternalBrace* surgical technique is intended only to augment the primary repair/reconstruction by expanding the area of tissue approximation during the healing period and is not intended as a replacement for the native ligament. The *InternalBrace* technique is for use during soft tissue-to-bone fixation procedures and is not cleared for bone-to-bone fixation.



Use a two-incision technique. Make the first incision dorsally over the 2nd metatarsal and middle cuneiform. The second incision should be medial, along the medial cuneiform, inferior to the tibialis anterior tendon insertion. Take care to protect the neurovascular bundle, underneath the extensor hallucis brevis (EHB).

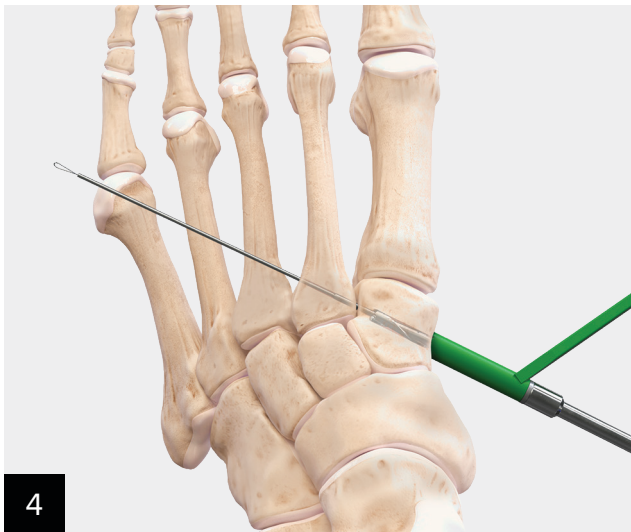


Stabilize the Lisfranc complex with the reduction clamp and compress the 2nd metatarsal base and the medial cuneiform. Complete the direct repair of the dorsal Lisfranc ligament per the standard technique.

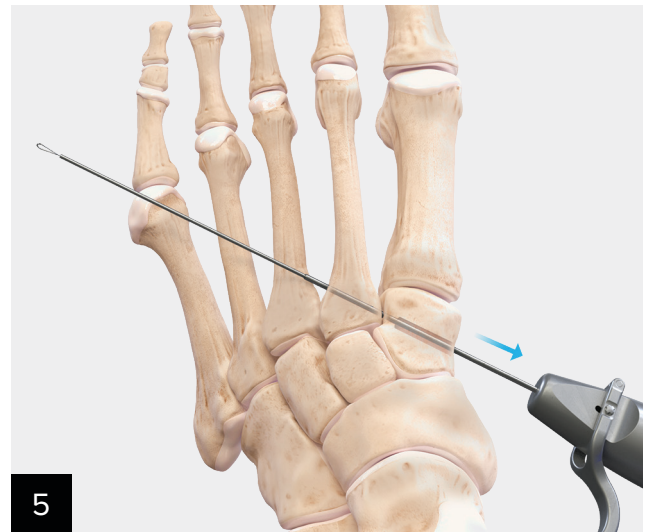


Insert the 1.6 mm guidewire starting at the dorsal lateral edge of the 2nd metatarsal base aiming plantar towards the medial cuneiform and through the interosseous ligament. The guidewire should exit inferior to the tibialis anterior tendon. Check guidewire trajectory under fluoroscopy.

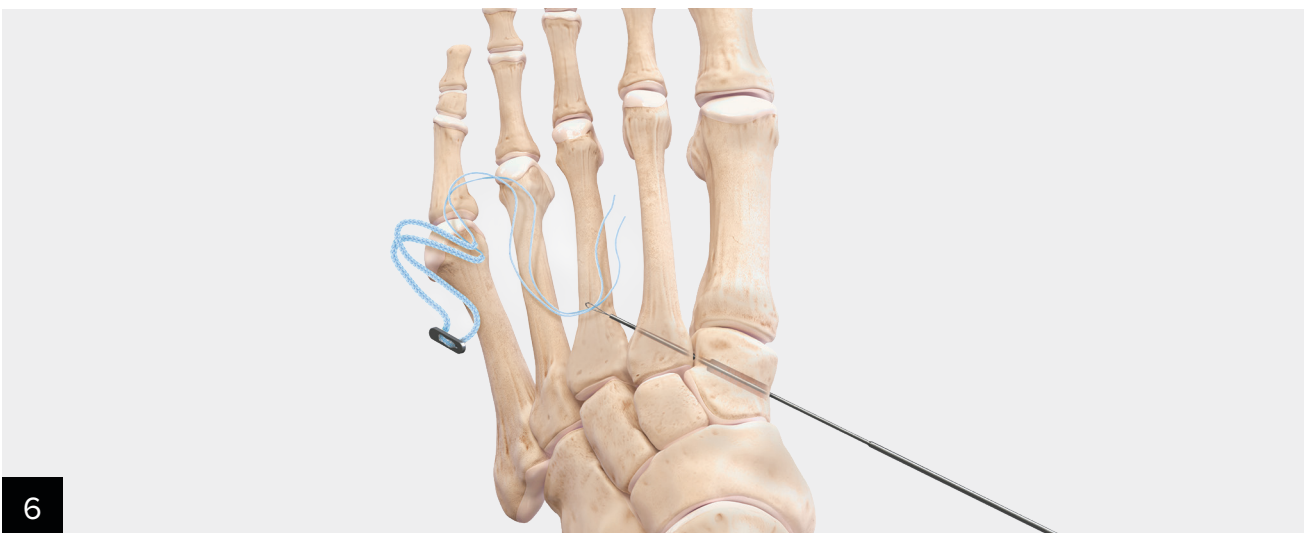
Note: Clamp omitted for clarity.



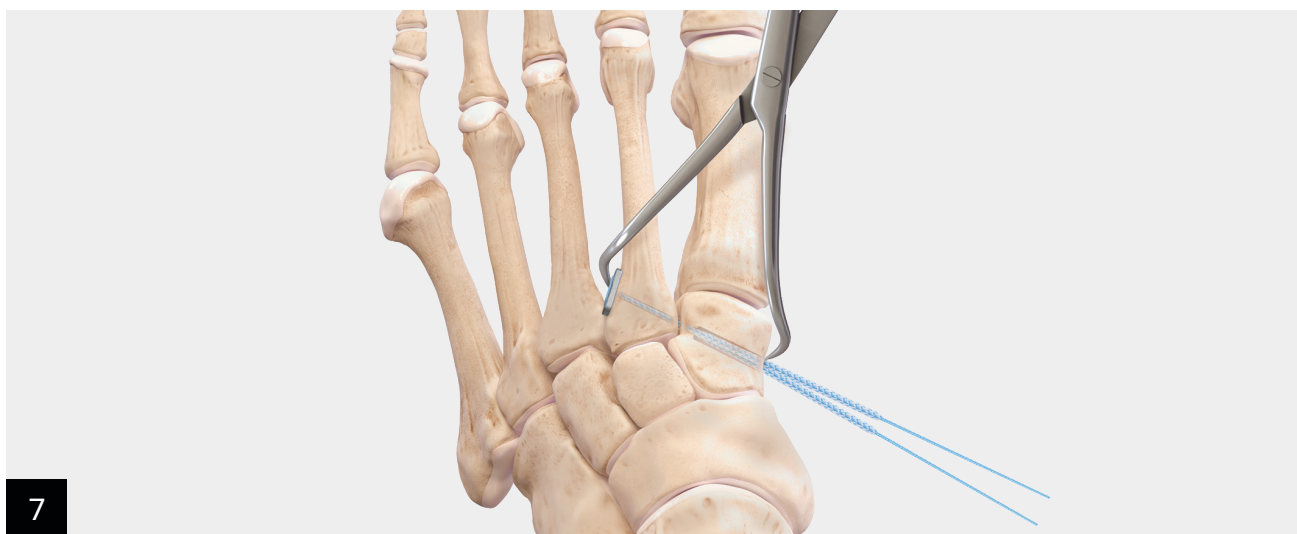
Retrograde the 3.5 mm cannulated drill and drill guide to prepare a 15 mm deep tunnel in the medial cuneiform. The drill stop prevents penetration of the drill into the Lisfranc articulation.



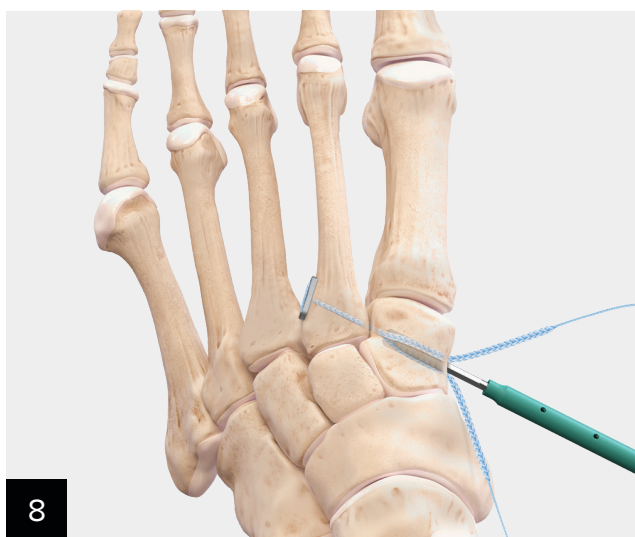
Oscillate the 1.6 mm guidewire from lateral to medial until the tapered 1.1 mm portion of the guidewire enters the 2nd metatarsal base and moves freely by hand. Once the guidewire is advanced past the 1.1 mm mark, the FiberTape® suture will advance easily through the Lisfranc articulation.



Load the collagen-coated 2 mm FiberTape suture with the oblong button through the nitinol loop on the 1.6 mm guidewire.

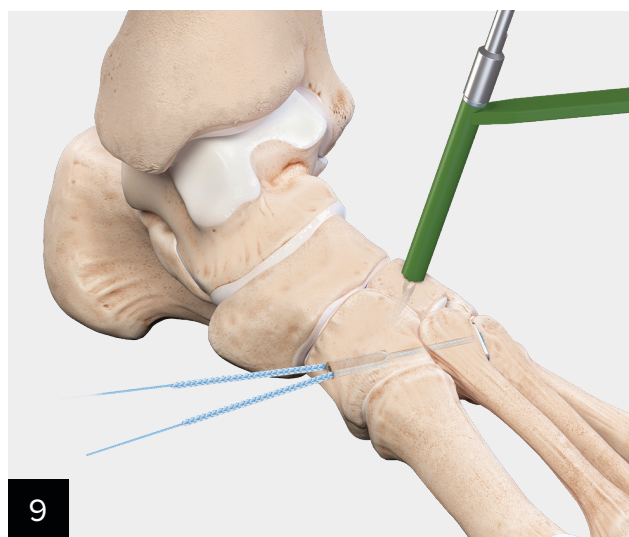


From the medial foot, pull maximum tension on the collagen-coated 2 mm FiberTape® suture. Ensure that the suture tails are straight and not twisted around each other. Additionally, ensure that the button is flush against the 2nd metatarsal cortex and in the correct orientation.

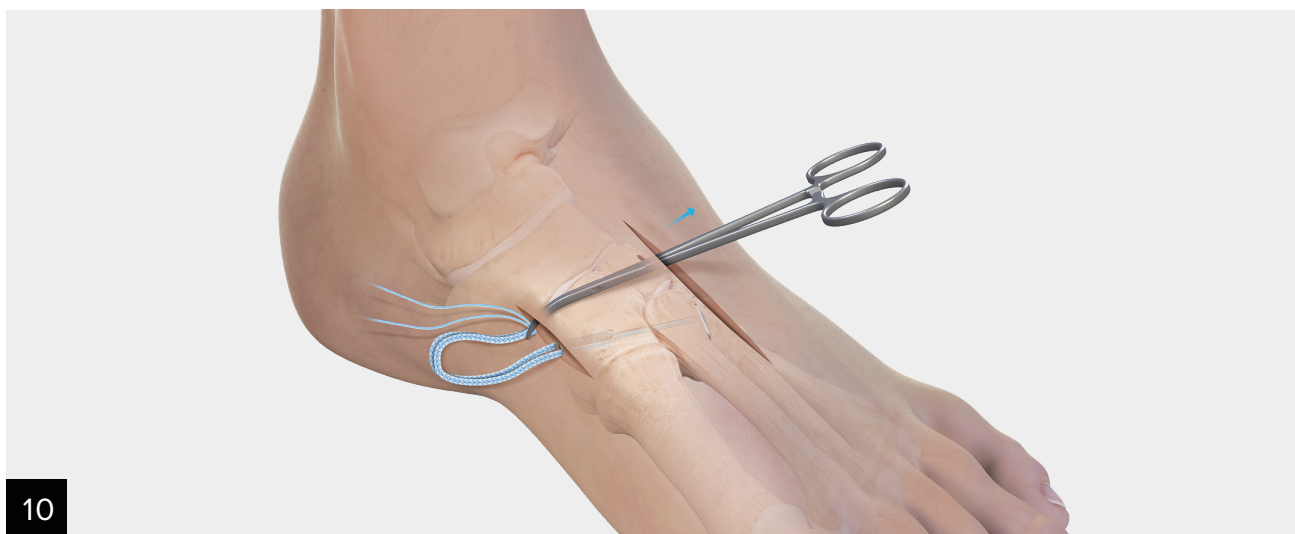


Insert the 4.75 mm PEEK SwiveLock® anchor between the suture tails while pulling tension on the FiberTape suture.

Note: For maximum construct strength, ensure that the anchor is placed between the split tails of the FiberTape suture.

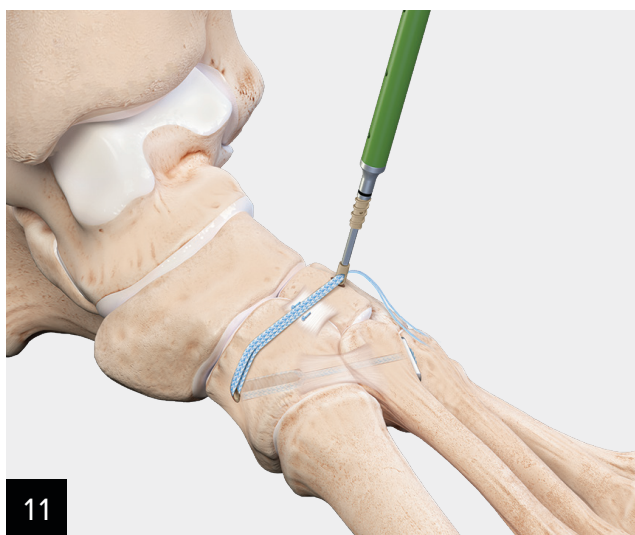


Intercuneiform instability: Drill the central portion of the intermediate cuneiform with the drill guide and the 3.4 mm drill bit.



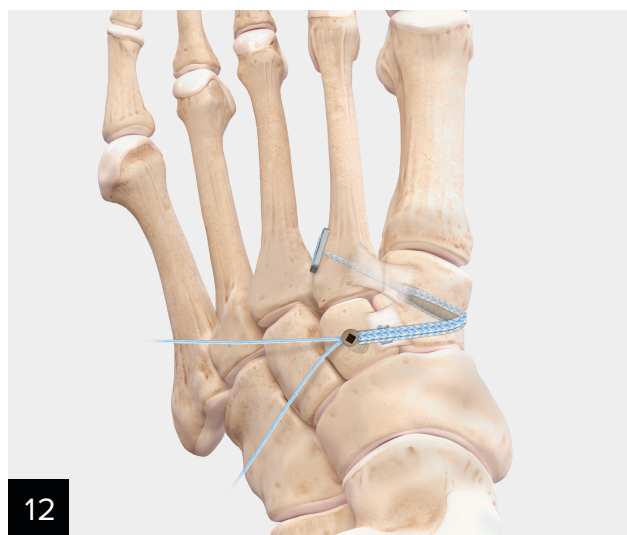
10

Using a blunt elevator, carefully dissect under the tibialis anterior tendon and the neurovascular bundle from both the medial and lateral directions. Pass a curved hemostat or curved tendon passer to grab and shuttle the tails of the FiberTape® suture from the medial side up and out of the dorsal incision. Once passed, use a retractor to ensure that the FiberTape suture is deep to the neurovascular bundle and tibialis anterior tendon.



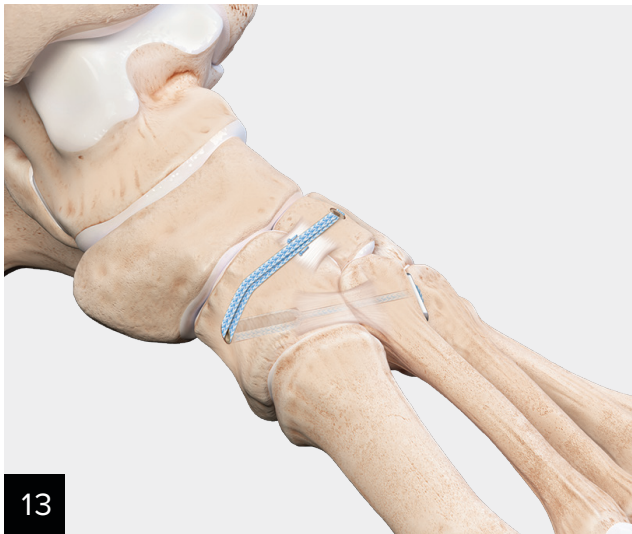11

Load FiberTape suture tails through the 3.5 mm × 13.5 mm SwiveLock® anchor.



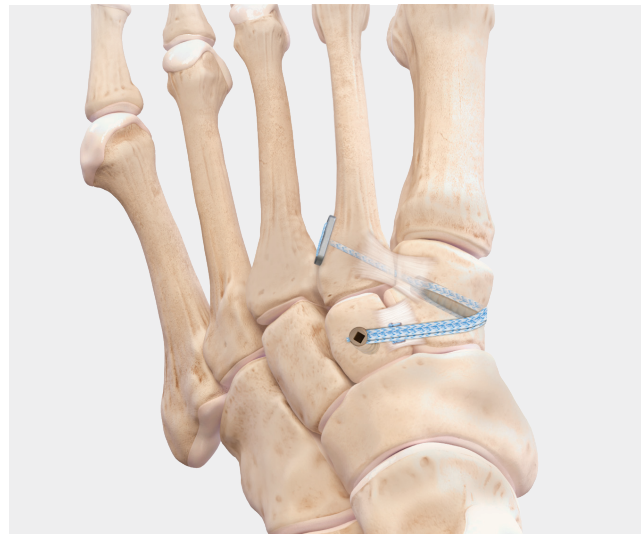12

Insert the 3.5 mm SwiveLock anchor.



13

Final fixation.



Ordering Information

Lisfranc Fixation System

Product Description	Item Number
PEEK SwiveLock® Suture Anchor, 4.75 mm FiberTape® Suture, collagen-coated, with button Drill Bit, cannulated, 3.5 mm Drill Guide Suture Passing Wire, 1.6 mm, qty. 2	AR-1698-CP

Additional Part Numbers for Supplemental Fixation Technique

Product Description	Item Number
DX SwiveLock Anchor, PEEK, w/ closed eyelet, 3.5 mm × 13.5 mm	AR-8979P

Disposables Kit for DX SwiveLock Anchor, 3.5 mm × 13.5 mm

Product Description	Item Number
Drill Guide w/ Depth Stop Drill Bit, solid, 3.0 mm Drill Bit, solid, 3.4 mm Tap for DX SwiveLock Anchor	AR-8979DS

References

1. Charlton T, Boe C, Thordarson DB. Suture button fixation treatment of chronic Lisfranc injury in professional dancers and high-level athletes. *J Dance Med Sci.* 2015;19(4):135-139. doi:10.12678/1089-313X.19.4.135
2. Koroneos Z, Vannatta E, Kim M, et al. Biomechanical comparison of fibertape device repair techniques of ligamentous Lisfranc injury in a cadaveric model. *Injury.* 2021;52(4):692-698. doi:10.1016/j.injury.2021.02.077
3. Stavlas P, Roberts CS, Xypnitos FN, Giannoudis PV. The role of reduction and internal fixation of Lisfranc fracture-dislocations: a systematic review of the literature. *Int Orthop.* 2010;34(8):1083-1091. doi:10.1007/s00264-010-1101-x
4. Panchbhavi VK, Vallurupalli S, Yang J, Andersen CR. Screw fixation compared with suture-button fixation of isolated Lisfranc ligament injuries. *J Bone Joint Surg Am.* 2009;91(5):1143-1148. doi:10.2106/JBJS.H.00162
5. Wright Medical. Charlotte Lisfranc bone screw surgical technique (009925B). <https://www.wright.com/footandankleproducts/charlotte-lisfranc-reconstructive-system>



This description of technique is provided as an educational tool and clinical aid to assist properly licensed medical professionals in the usage of specific Arthrex products. As part of this professional usage, the medical professional must use their professional judgment in making any final determinations in product usage and technique. In doing so, the medical professional should rely on their own training and experience, and should conduct a thorough review of pertinent medical literature and the product's directions for use. Postoperative management is patient-specific and dependent on the treating professional's assessment. Individual results will vary and not all patients will experience the same postoperative activity level and/or outcomes.

arthrex.com

© 2024-02 Arthrex GmbH. All rights reserved. LT1-00105-EN_D



Arthrex manufacturer,
authorized representative,
and importer information
(Arthrex eIFUs)



US patent information