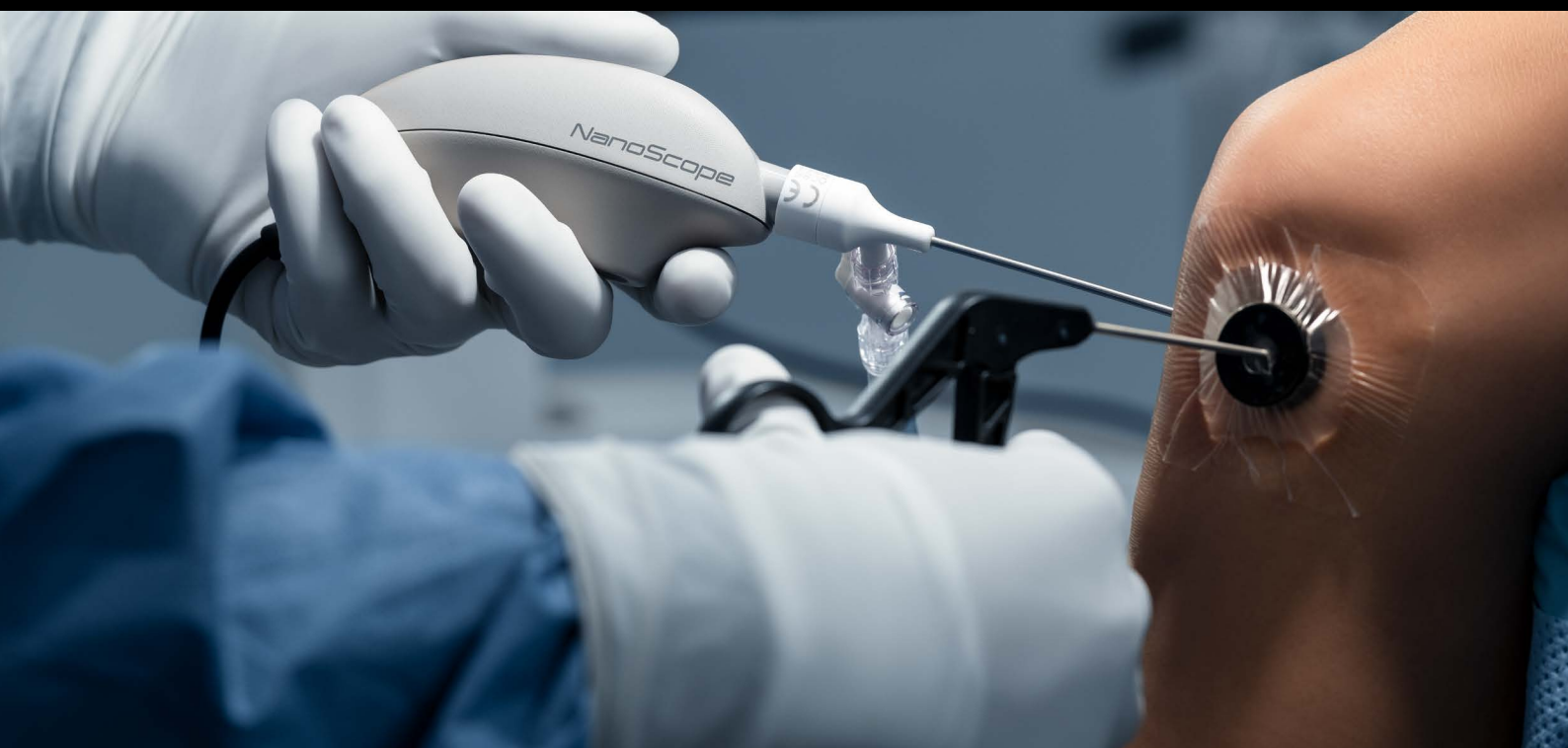

Therapeutic NanoScope™ Surgery with Local Anesthesia

Developed by Brian B. Gilmer, MD



Arthrex® 

Table of Contents

Pre-op Instructions	03
Equipment.....	03
Medications	03
Setup of Mini Nano Tray.....	03
Nano Console Linked to Overhead Monitors.....	04
Nano Sterile Instructions Available As Needed	04
Steps.....	04
Examples	07
Positioning	07
Steps Continued.....	08
Diagnostic Nano Arthroscopy Dictation Template	08
Example Postprocedure Instructions	10

Pre-op Instructions

NPO in case anesthesia is needed

Equipment

- Standard OR draping
- Pump tubing
- 1 L NS bag for standard cannula

Medications

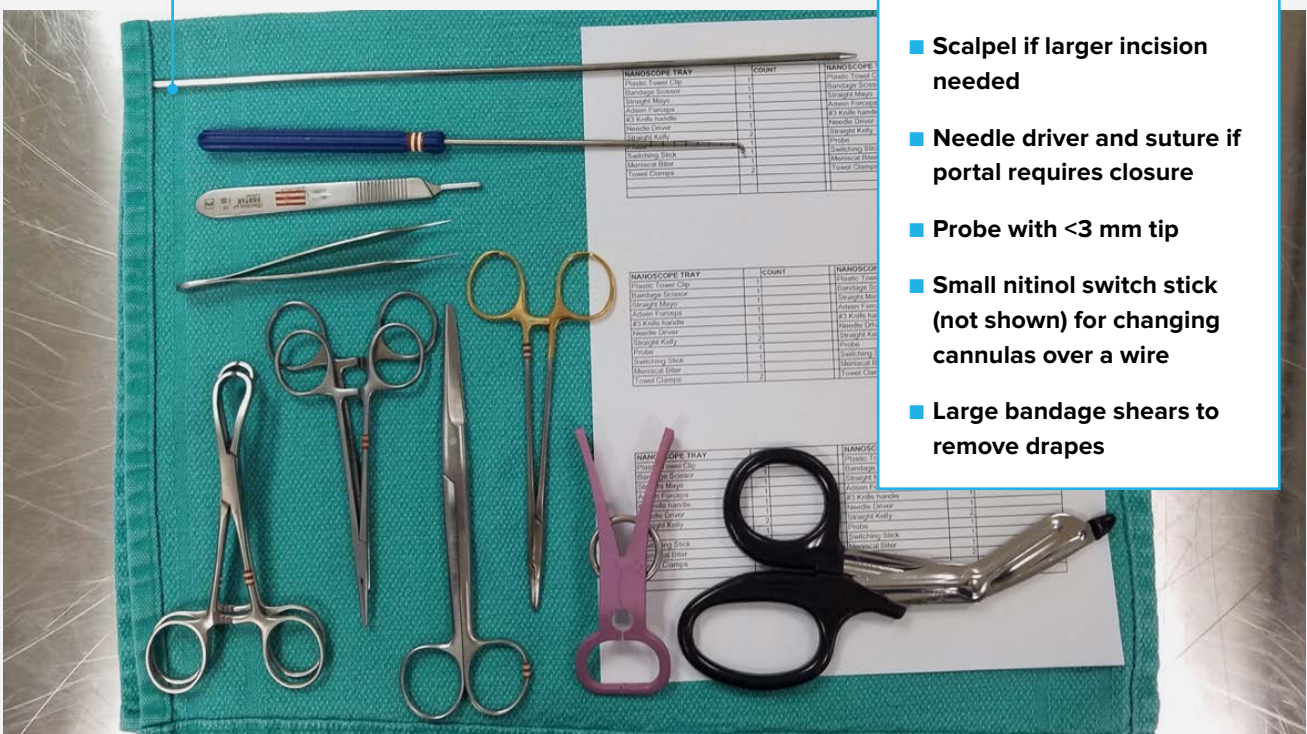
Preprocedure

- No medications are required
- Optional, for anxiety: 2 mg PO diazepam 30 minutes prior; may repeat x1

Postprocedure

- OTC Tylenol® 650 mg PO q 6 hours PRN pain
- OTC anti-inflammatory (eg, ibuprofen) as instructed per package insert

1. Setup of Mini Nano Tray



- Towel clips for draping: avoids adhesive on patient skin
- Scalpel if larger incision needed
- Needle driver and suture if portal requires closure
- Probe with <3 mm tip
- Small nitinol switch stick (not shown) for changing cannulas over a wire
- Large bandage shears to remove drapes

2. Nano console linked to overhead monitors with connector

3. Nano sterile instruments available as needed

■ NanoProbe



■ Saber shaver



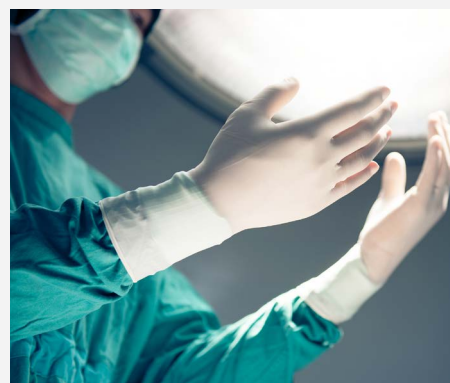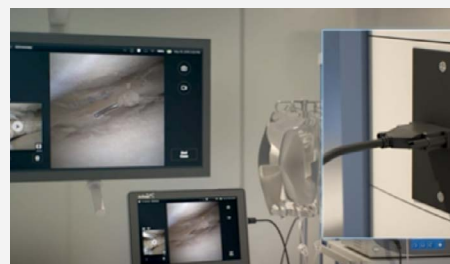■ NanoCannula



Steps

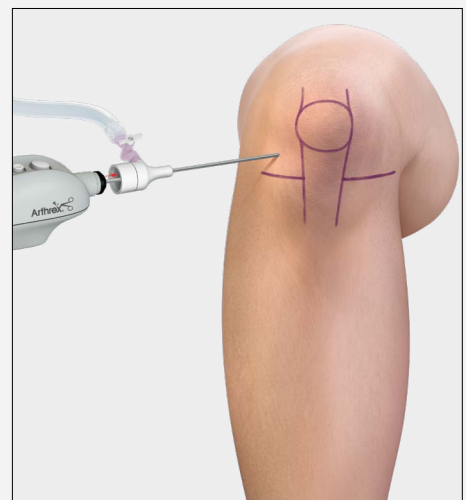
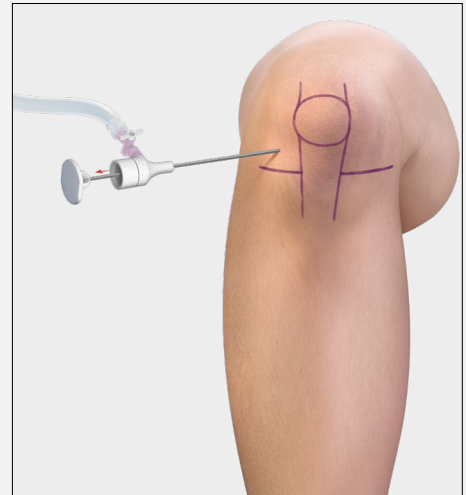
1. Patient comes to OR with nursing staff
2. Confirm site and side
3. Single blue $\frac{3}{4}$ sheet drape up between patient and surgeon
4. Prep portal sites with ChloroPrep™* stick
5. Place knee in position
 - a. 90° on the bed; sit on patient foot to maintain position
6. Mark patellar tendon or portal sites
 - a. 2 cm below the inferior pole of the patella
 - i. 1 cm from tendon borders for notch and condyle
 - ii. 2 cm from tendon borders for meniscus
7. 25 Ga or 28 Ga needle to inject 1 mL into the skin
8. 22 Ga needle to inject through a fat pad in a line toward the anticipated area of pathology; inject the remaining 8 mL; make a wheel along the joint line on both sides
9. Surgeon goes to scrub
10. Circulator performs standard prep

*ChloroPrep is a trademark of CareFusion 2200, Inc.



Steps (Cont.)

11. Surgeon and scrub tech
 - a. Place sterile towel and secure with clips
 - b. Sterile extremity drape
12. Staff prepares the tablet while local anesthetic sets in
 - a. Connect tablet
 - b. Input relevant information
 - c. Calibrate
 - d. Confirm the function of the camera
13. Lower room lights to improve the view
 - a. NanoScope™ system lighting is less bright than with standard arthroscopy
14. Insert trocar into the lateral portal site after testing for skin analgesia using a sharp trocar
 - a. Direct toward notch
15. Attach tubing and allow insufflation of knee with some fluid
16. Insert camera and conduct diagnostic scope with the camera alone
17. Make medial portal under direct visualization based on localization with a spinal needle (local anesthetic is applied to the area of the medial portal)
18. A simple probe may be used through the medial portal for use of further instrumentation once pathology is confirmed



Steps (Cont.)

19. For the standard NanoScope™ system, resection work will typically require a separate inflow cannula to support shaving and resection

20. Inflow sheath should be placed peripherally in the compartment where the primary pathology is located

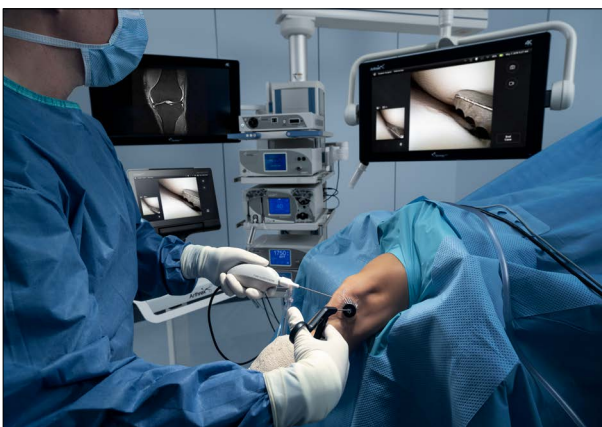
Example: medial meniscal tear

21. Insert medial trocar under direct visualization from a far medial position 2 cm more medial to the working medial portal, and use sharp trocar directing toward the notch

22. Move the inflow from the lateral sheath to the far medial sheath and open flow

23. Medial sheath may now be used as a probe or positioned near the posterior horn

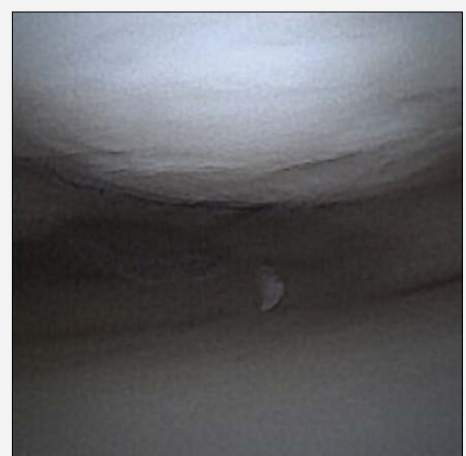24. Meniscal biter (NanoBiter) and shaver may now be used in and out of the medial portal as with standard arthroscopy



NanoBiter in the medial compartment



Saber shaver in the medial compartment



After meniscectomy

Examples

In the image to the right, the standard NanoScope™ inflow sheath is in the far medial portal directed into the notch (superior instrument), and a 3.5 mm shaver is in the standard medial portal debriding synovial overgrowth in the intercondylar notch. The inflow's location near the working instrument allows for preserved visualization during resection with good image resolution.

Positioning

Typical of standard arthroscopy with lateral post

Medial compartment: gentle valgus is well tolerated

Patients with tight varus knees based on a preoperative exam or those expected to require MCL release may not be ideal candidates for nano arthroscopy with local anesthesia only; consider patient-specific anesthesia

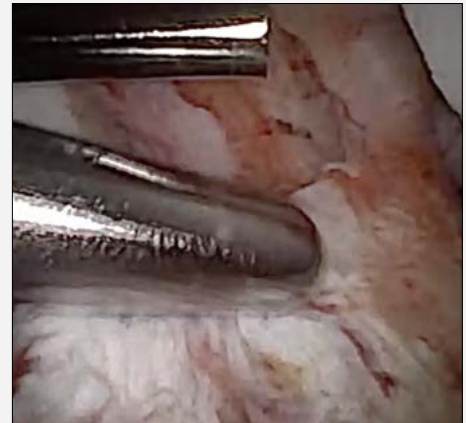- Lateral compartment: this is well tolerated
- Notch/condyles: knee remains at 90° off the edge of the bed

Pathology by portal


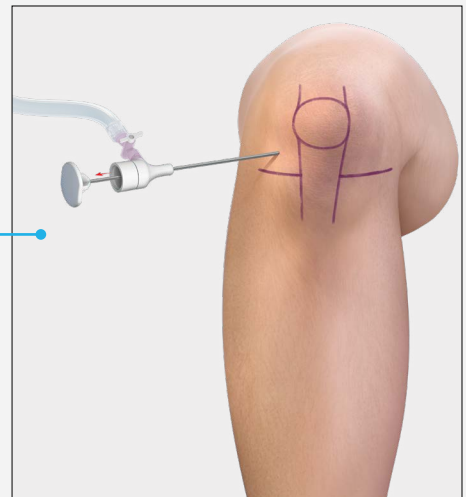
- ACL: lateral portal
- PCL: lateral portal
- Medial meniscus (anterior horn and body): lateral portal
- Medial meniscus (posterior horn and root): medial portal under valgus stress
- Lateral meniscus (anterior horn and body): medial portal
- Lateral meniscus (posterior horn and root): lateral portal
- Medial condyle: lateral portal 30° to 90° of flexion
- Lateral condyle: medial portal 30° to 90° of flexion
- Patellofemoral: knee in extension; consider accessory superior medial and/or superior lateral portals for the examination of gutters and suprapatellar pouch as needed

If difficult to evaluate the meniscal root from the contralateral portal, consider:

- using pre-bent 10° high-flow sheath
- gently bend the standard Nano sheath to 10°
- use a transpatellar tendon portal



Debridement of ACL Cyclops lesion

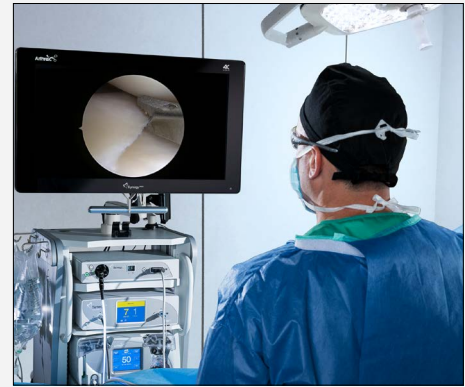

Positioning (Cont.)

27. Obtain images
28. Remove camera
29. Manually express any excess fluid
30. Remove sheaths
31. Dermabond® over portal sites when dry
32. Place JumpStart® dressings
33. Upload images to PACS/Surgeon Vault® system

Diagnostic Nano Arthroscopy Dictation Template:

Preoperative Diagnosis:	
Postoperative Diagnosis:	
Procedure Performed	
	Nano arthroscopy
	With partial meniscectomy (29881)
	Partial medial and lateral meniscectomies (29880)
	Meniscal repair (29882)
	3 compartment synovectomy (29876)
	Chondroplasty (29877)
	Removal of the loose body through a separate incision (29874)



Complications: None apparent	
Surgeon:	
Assistant:	
None	Anesthesiologist
Local	Anesthesia
Normal	Complexity
N/A	Devices and implants
N/A	Implant sheet reviewed
None	Estimated blood loss
None	Specimen removed
None	Blood administered
None	Tourniquet time

Diagnostic Nano Arthroscopy Dictation Template (Cont.)

Description of Procedure:

On the date of surgery, the patient was identified in the preoperative holding area. The surgical site was agreed upon, confirmed, and marked by the surgery team, nursing staff, and patient. I marked the operative side. The patient was taken to the operating room and a surgical time-out was performed. The patient was positioned supine on the operating table with attention paid to padding all bony prominences. A local anesthetic was administered. The limb was prepped and draped in the usual sterile fashion. The patient received antibiotic prophylaxis within 30 minutes of incision and mechanical DVT prophylaxis to the nonoperative leg.

Attention was first turned to the diagnostic portion of the procedure. Physical examination was performed which revealed [].

Diagnostic NanoScope arthroscopy was then undertaken. Portal sites were marked using anatomic landmarks. A suprapatellar, then lateral, and then medial viewing portal was established. A probe was introduced, and all structures were thoroughly probed and evaluated for pathology. Results of the diagnostic arthroscopy are as follows:

Suprapatellar pouch normal
Patella normal
Trochlea normal
Medial femoral condyle normal
Medial tibial plateau normal
Lateral femoral condyle normal
Lateral tibial plateau normal
Medial meniscus normal
Lateral meniscus normal
Medial gutter normal
Lateral gutter normal
Notch normal
ACL normal
PCL normal

Attention was then turned to the therapeutic portion of the arthroscopic procedure.

(A curved shaver was introduced into the knee. A combination of shaver and biter was then used to perform a meniscectomy, removing enough meniscus to leave a stable base. Loose meniscal pieces were removed. Total meniscus resected at the deepest depth of resection was [].)

(Chondroplasty was performed with a mechanized shaver of the chondral damage noted above.)

The NanoScope was removed. The portals were closed with Dermabond and sterile dressings were placed. The patient was taken to the recovery room in good condition. Sponge needle counts were correct x2.

Postoperative Plan:

Date of discharge protocol with oral or over-the-counter analgesics. No restrictions. Begin physical therapy this week. Follow up in the clinic in 2 weeks to review arthroscopic findings.

Postprocedure Instructions: Nano Arthroscopy of Knee

Activity

- You may put as much weight as comfortable on your leg.
- You may bend and straighten your knee as much as you like.
- Do not engage in prolonged periods of standing or walking the first day after surgery.
- Avoid long periods of sitting or long distance traveling for 2 weeks.

Dressings and Incisions

- The first 2 days after surgery, you can expect a small amount of red-tinged drainage on your dressings. This is normal.
- Please keep the dressing clean and dry; if you are going to shower/bathe, you must protect the dressing. You may not soak in a pool, lake, hot tub, or the ocean for 2 weeks.
- You may remove the BAND-AID® dressing 4 days after surgery.
- After 4 days you may apply BAND-AID dressings to the portals or leave them open to the air.
- Please do not use bacitracin or other ointments on the portals.

Pain and Inflammation

- Ice: You may apply ice bags wrapped in a dry towel as needed for pain relief and inflammation.
- Compression: Use an Ace™ wrap as needed to decrease swelling, but this is not required.
- Elevation: Keep your foot elevated above your heart if you have increased swelling or discomfort.
- Pain Medication: If you need pain medication, you may take Tylenol 500 mg to 650 mg every 4 to 6 hours as needed and as directed per the package insert. Do not take more than 3 grams or 3,000 mg in 24 hours.
- Anti-inflammatory medications (Ibuprofen, etc) may be taken as needed and as directed per the package insert.

Emergencies

- Please have someone stay with you for the first 24 hours after surgery
- Please call the clinic or the orthopedist on call if:
 - Drainage from the incision soaks the dressings and continues to drain after a bandage change
 - You develop a fever (>101.5°) or chills
 - You experience leg or calf pain, leg swelling, or difficulty breathing

Follow-up Care

- Please schedule a follow-up visit to review your surgery 10 to 14 days postoperatively. You may choose to schedule a remote video or phone follow up at your discretion.

arthrex.com

© 2021 Arthrex, Inc. All rights reserved. LI1-000125-en-US_A

