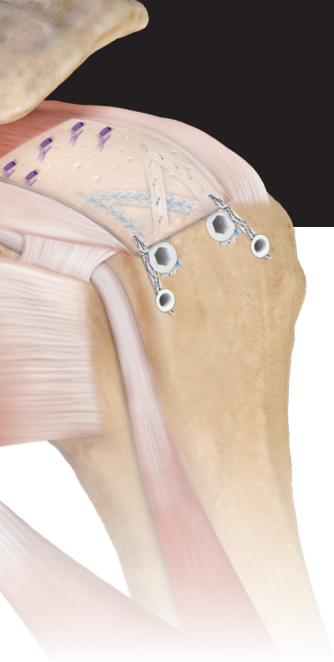


Dermal Allograft Augmentation of Rotator Cuff Repair Scientific Update



Duong JK,
Lam P,
Murrell GAC

Most rotator cuff tears are degenerative in nature. The deterioration in tendon quality explains why the most common mode of rotator cuff failure is tendon pulling through suture. While mechanical advancement has been made to improve fixation (ie, double-row constructs or FiberTape® sutures), retears continue to occur, particularly with larger tears, advancing age, and fatty infiltration. Scientific literature has shown that dermal allograft augmentation can improve mechanical strength of a repair, has the capability to integrate into tendon, and has distinct advantages over xenograft sources (ie, bovine patch). Clinical evidence suggests that healing and functional outcomes can be improved with dermal allograft augmentation. Knowledge of the risk factors for re-tear may provide guidance on when to use dermal allograft augmentation during rotator cuff repair.

Scope of the Problem

[Anteroposterior tear size, age, hospital, and case number are important predictors of repair integrity: an analysis of 1962 consecutive arthroscopic single-row rotator cuff repairs \[published online ahead of print, 2020 Nov 4\]. *J Shoulder Elbow Surg.* 2020;S1058-2746\(20\)30834-X. doi:10.1016/j.jse.2020.09.038](#)

- Retrospective evaluation of 1962 rotator cuff repairs performed by a single surgeon over a 12-year period
- Healing was assessed by ultrasound at 6 months postoperative
- The overall re-tear rate was 14%
- The odds of re-tear increased with tear size and age:
 - 4-fold when the anteroposterior tear size increased from 1 cm to 3 cm
 - 2-fold when the age increased from 50 to 70 years

Takeaway:

The re-tear rate is highest with larger tears and advancing age. Tears >3 cm may warrant consideration of biologic techniques to improve healing.

Kwon J,
Kim S,
Lee Y,
Kim T,
Oh JH

[The Rotator Cuff Healing Index: A New Scoring System to Predict Rotator Cuff Healing After Surgical Repair.](#) *Am J Sports Med.* 2019;47(1):173-180. doi:10.1177/0363546518810763

- Evaluation of factors associated with healing in 603 patients with a postoperative MRI or CT arthrogram 1 year after arthroscopic rotator cuff repair
- The overall retear rate was 24%
- Odds of a retear were increased to the greatest degree with the following:
 - Retraction >3 cm: 12.9 times
 - Infraspinatus fatty infiltration >2: 2.91 times
 - Age >70 years: 2.71 times
- The authors created a scoring index to predict healing, which can be referenced in the example below:
 - A 50-year-old patient with a 3 cm retracted tear and grade 2 or higher infraspinatus atrophy has a 12% to 46% chance of healing depending on level of work activity

Takeaway:

Increasing tear retraction and fatty infiltration decreases the odds of healing after rotator cuff repair. Suggestion: Review preoperative MRIs with surgeons and when large tears with fatty infiltration are noted, discuss the odds of healing with a standard repair.

Haque A,
Pal Singh H

[Does structural integrity following rotator cuff repair affect functional outcomes and pain scores? A meta-analysis.](#) *Shoulder Elbow.* 2018;10(3):163-169. doi:10.1177/1758573217731548

- Systematic review and meta-analysis comparing functional outcome in healed and failed rotator cuff repairs from Level I-III studies
- 12 studies with 800 patients were included
- The overall retear rate was 22%
- Functional outcome was improved in the setting of healing:
 - Constant score: 8.6 points higher ($P < .001$)
 - ASES score: 9.5 points higher ($P < .001$)
 - VAS pain score: 0.6 points lower ($P < .001$)

Takeaway:

Healing is associated with improved clinical outcome compared to structural failure following rotator cuff repair.



McElvany M,
McGoldrick E,
Gee A,
Neradilek M,
Matsen FA 3rd

[Rotator cuff repair: published evidence on factors associated with repair integrity and clinical outcome.](#) *Am J Sports Med.* 2015;43(2):491-500. doi:10.1177/0363546514529644

- Systematic review of the functional outcomes and healing of rotator cuff repairs from 1990 to 2012
- 108 articles with 8011 shoulders were included
- The overall retear rate was 27%
- The percentage of maximal possible improvement (%MPI) achieved was 72%
- There was no difference in healing or %MPI between 1990 and 2012 despite an increase in number of publications

Takeaway

Despite improved fixation techniques, retear remains common after rotator cuff repair and there is room for improvement in outcomes. This suggests that other avenues of advancement (ie, biology) are needed to improve clinical outcomes of rotator cuff repair.

Cummins C,
Murrell GA

[Mode of failure for rotator cuff repair with suture anchors identified at revision surgery.](#) *J Shoulder Elbow Surg.* 2003;12(2):128-133. doi:10.1067/mse.2003.21

- Prospective evaluation of 342 rotator cuff repairs performed by a single surgeon with a mean of 4 anchors
- Patients were followed for 2 years after surgery
- 21 patients (6%) underwent a revision procedure within the study period, with 1 patient having 2 revisions
- The mode of failure in 86% of cases (19 of 22) was tendon pulling through sutures
- Mean tear size was larger following failure compared to the initial repair (8.9 cm² vs 6.3 cm²; $P = .043$)

Takeaway:

As evidenced by the mode of failure, the weak link in rotator cuff repair is the tendon, rather than anchor fixation.



Smith M,
Bozynski C,
Kuroki K,
Cook C,
Stoker A,
Cook JL

Basic Science Studies

[Comparison of biologic scaffolds for augmentation of partial rotator cuff tears in a canine model.](#) *J Shoulder Elbow Surg.* 2020;29(8):1573-1583. doi:10.1016/j.jse.2019.11.028

- Evaluation of treatment of partial-thickness rotator cuff tears in a canine model:
 - 8 control shoulders
 - 8 shoulders treated with debridement alone
 - 8 shoulders treated with amnion matrix cord scaffold (Arthrex Amnion™ scaffold)
 - 8 shoulders treated with a 1 mm dermal allograft patch (ArthroFlex dermal allograft)
 - 8 shoulders treated with a bovine collagen patch (Regeneten [Smith & Nephew, Inc.]
- 6-month outcomes:
 - Pain was significantly higher and range of motion was significantly lower in the debridement and Regeneten patch groups compared to the amnion matrix cord and dermal allograft groups
 - Ultrasounds showed healing in all groups, but inflammation and synovitis in the bovine patch group were consistent with foreign body reaction
 - Histopathology scores of the tendon 6 months after the procedures were lowest (most normal) in the dermal allograft group and lower in the amnion matrix cord group compared to the debridement and bovine patch groups

Takeaway:

In a canine model, dermal allograft or amnion matrix cord improve outcomes in the treatment of partial rotator cuff tears. A bovine patch is associated with inflammation and leads to less normal tendon healing.

Omae H,
Steinmann S,
Zhao C,
Zobitz ME,
Wongtriratanachai P,
Sperling JW,
An KN

[Biomechanical effect of rotator cuff augmentation with an acellular dermal matrix graft: a cadaver study.](#) *Clin Biomech (Bristol, Avon).* 2012;27(8):789-792. doi:10.1016/j.clinbiomech.2012.05.001

- Biomechanical evaluation of the impact of dermal allograft augmentation on rotator cuff repair in 9 matched pairs of human cadavers
 - Control group: Single-row repair
 - Experimental group: Augmentation with a 2 mm acellular human dermal allograft
- Load to failure was improved by 62% with addition of dermal allograft augmentation (560 N vs 346 N; $P < .01$)
- Mode of failure was tendon cutout in 7 of 9 standard repairs, which was reduced to 5 of 9 with dermal allograft

Takeaway:

Dermal allograft augmentation increases the biomechanical strength of a rotator cuff repair by over 60%.



Snyder S,
Arnoczky S,
Bond J,
Dopirak R

[Histologic evaluation of a biopsy specimen obtained 3 months after rotator cuff augmentation with GraftJacket Matrix.](#) *Arthroscopy*. 2009;25(3):329-333. doi:10.1016/j.arthro.2008.05.023

- Case report of a second look 3 months after a rotator cuff repair performed with dermal allograft augmentation
- Biopsy of the dermal allograft showed vascularity and remodeling of the graft into tendon-like tissue
- There was no evidence of inflammation

Takeaway:

This case report, among others, demonstrates the ability for dermal allograft to both vascularize and remodel in the clinical setting.

Clinical Studies

[Graft augmentation of repairable rotator cuff tears: an algorithmic approach based on healing rates \[published online ahead of print, 2021 Nov 9\].](#) *Arthroscopy*. 2021;S0749-8063(21)00963-4. doi:10.1016/j.arthro.2021.10.032

- Review paper on the factors associated with failure of healing after rotator cuff repair followed by recommendations for consideration of augmentation
- Both patient factors and tear factors are associated with an increased risk of failure of healing, most notably:
 - Tear size (large and massive rotator cuff tears)
 - Fatty infiltration
 - Increasing age
- Tissue augmentation can improve healing of rotator cuff tears
 - Best evidence supports the use of dermal allograft
- Authors advocate for the use of the Rotator Cuff Healing Index as a guideline for preoperatively assessing the need for dermal allograft augmentation
 - From their perspective, a reasonable cutoff is a score of 7 points because the chance of healing without augmentation decreases from approximately 66% at 6 points to 38% at 7 points

Takeaway:

The Rotator Cuff Healing Index can be applied to assess the need for dermal allograft augmentation preoperatively, with a score of 7 points representing a reasonable threshold for the addition of dermal allograft given the sharp decrease in healing with a nonaugmented repair at that threshold.

Jackson GR,
Bedi A,
Denard PJ



Bailey J,
Kim C,
Alentorn-Geli E,
Kirkendall DT,
Ledbetter L,
Taylor DC,
Toth AP,
Garrigues GE

[Rotator Cuff Matrix Augmentation and Interposition: A Systematic Review and Meta-analysis.](#)

Am J Sports Med. 2019;47(6):1496-1506. doi:10.1177/0363546518774762

- Systematic review and meta-analysis of rotator cuff augmentation
- 5 papers were included
- Retear rate was lower and ASES scores were improved with augmentation ($P < .05$)
 - Specific rates:
 - Allograft: 82%
 - Xenograft: 68%
 - Nonaugmented repairs: 49%
- Forward flexion improvement was higher with allograft compared to xenograft (45° vs 31°)

Takeaway:

Based on systematic review, augmentation improves rotator cuff healing. Healing and function are improved with allograft compared to xenograft augmentation.

Gilot G,
Alvarez-Pinzon AM,
Barcksdale L,
Westerdahl D,
Krill M,
Peck E

[Outcome of Large to Massive Rotator Cuff Tears Repaired With and Without Extracellular Matrix Augmentation: A Prospective Comparative Study.](#)

Arthroscopy. 2015;31(8):1459-1465.

doi:10.1016/j.arthro.2015.02.032

- Prospective (nonrandomized) study of 35 large and massive rotator cuff tears:
 - 20 repairs augmented with ArthroFlex graft
 - 15 standard repairs
- Retears were more common in standard repairs compared to augmented repairs (26% vs 10%; $P = .0483$)
- Postoperative pain scores were lower with ArthroFlex graft (0.9 vs 4.1; $P = .024$)
- Postoperative ASES scores were higher with ArthroFlex graft (88.9 vs 72.6; $P = .02$)

Takeaway:

Postoperative healing and functional outcome of large and massive rotator cuff tears is improved with ArthroFlex augmentation.



Barber F,
Burns J,
Deutsch A,
Labbé M,
Litchfield RB

[A prospective, randomized evaluation of acellular human dermal matrix augmentation for arthroscopic rotator cuff repair.](#) *Arthroscopy*. 2012;28(1):8-15. doi:10.1016/j.arthro.2011.06.038

- Randomized controlled trial of 42 large rotator cuff tears (>3 cm)
 - Control group: Standard repair
 - Experimental group: Dermal allograft augmentation
- MRIs were obtained at a minimum of 1 year postoperative
 - Standard group: 40% healing
 - Dermal allograft augmentation: 85% healing
- No adverse events were observed with augmentation

Takeaway:

In this Level 1 trial, healing of large rotator cuff tears was over 2× as likely (85% vs 40%) with dermal allograft augmentation compared to a standard repair.