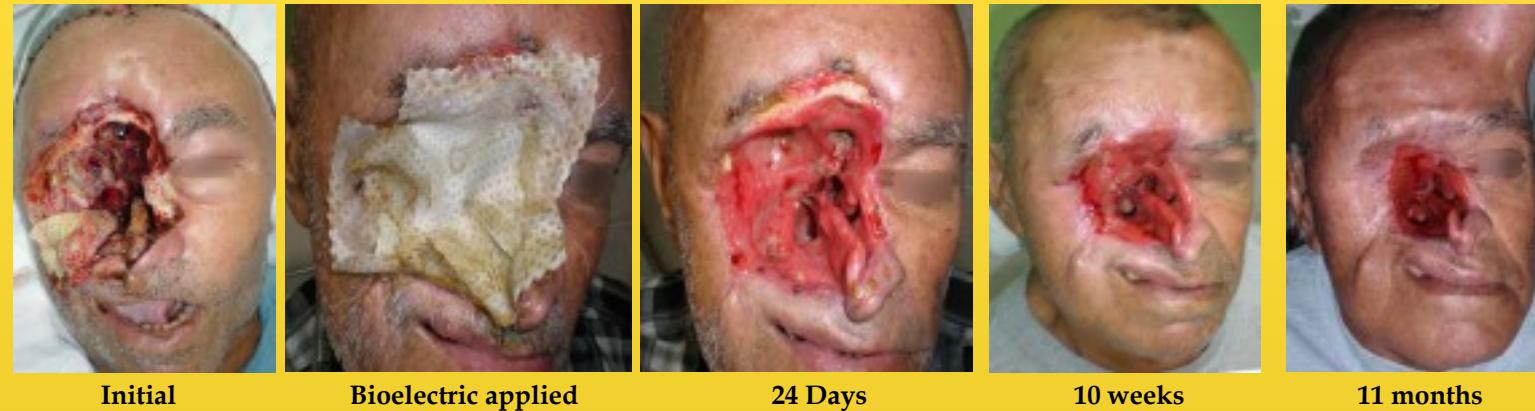

The management of complex wounds with the use of a bioelectric, antimicrobial dressing

Author: Jorge Elizondo, MD
Wound Clinic, Dermatology Department
Hospital México, San Jose, Costa Rica

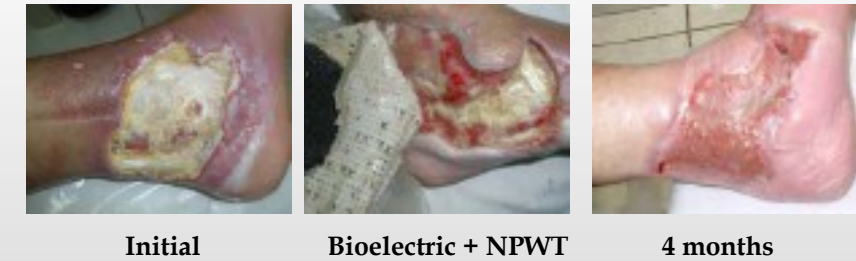Exposed Bone

69 y.o. male with wound secondary to excision of squamous cell carcinoma. Previous treatment was non-adherent dressing with vaseline gauze. Participant reported significant pain reduction with the use of the bioelectric dressing.



Infected Wound

38 y.o. female with type 1 diabetes presented with soft tissue infection and osteomyelitis on the lateral aspect of the right foot. Previous tx: 40 days NPWT + bioelectric dressing, followed with calcium alginate. 3 months later, bioelectric dressing was reapplied as an interface between NPWT sponge and wound site to obtain final epithelialization.



Background:

Complex wounds require a specialized approach in the area of dressing selection and wound management. A growing body of research has shown the benefits of the synergistic activity of electric stimulation and antimicrobial action (1). A novel antimicrobial bioelectric dressing* that exhibits these two mechanisms of action has been clinically observed to initiate healing in complex wounds that had failed all other methods of treatment (2).

Methods:

A bioelectric, antimicrobial wound dressing was evaluated in a series of case studies. Patients with wounds of various etiologies were treated with a bioelectric dressing, which was applied to the cleansed wound site and covered with a sterile semi-occlusive dressing for a period of 5 days to 11 months with 2-3 dressing changes per week. The wound was observed closely for any signs of healing initiation and epithelialization.

Results:

All wounds in the presented case studies showed signs of healing. No adverse effects were reported.

Conclusion:

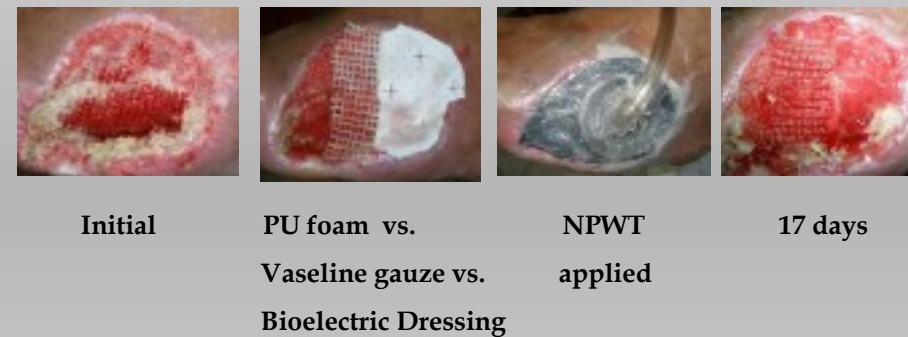
Based on the results from the presented clinical case study observations, it appears that the application of an antimicrobial, close-proximity electrically active wound dressing may be effective in facilitating healing of severe, complex wounds. Future studies are needed to determine if the bioelectric dressing is applicable other acute and chronic wound settings.

References:

- Berger TJ, Spadaro JA, Chapin SE, Becker RO. Electrically generated silver ions; quantitative effects on bacterial and mammalian cells. *Antimicrob Agents Chemother* 1976;9:357-8.
- Sheftel SN. The role of a bio-electric, antimicrobial dressing in the healing of acute and chronic wounds [abstract]. *Clinical Symposium on Advances in Skin and Wound Care, Las Vegas, NV, October 2008; (suppl): 217.*

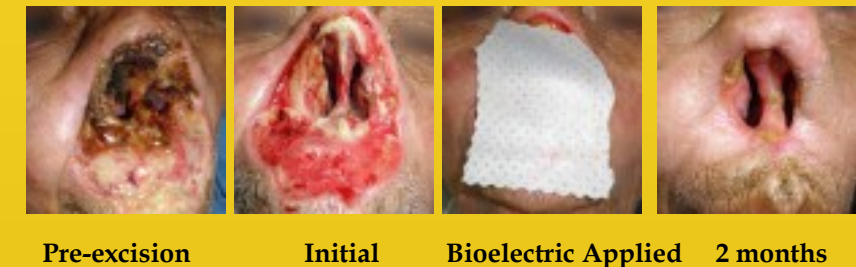
Exposed Tendon

43 y.o. male with history of diabetes presented with exposed tendon on the lateral aspect of the left foot. Wound treated with NPWT**. 3 interfaces were utilized under the NPWT device and compared: polyurethane foam dressing, vaseline gauze, and the bioelectric dressing.



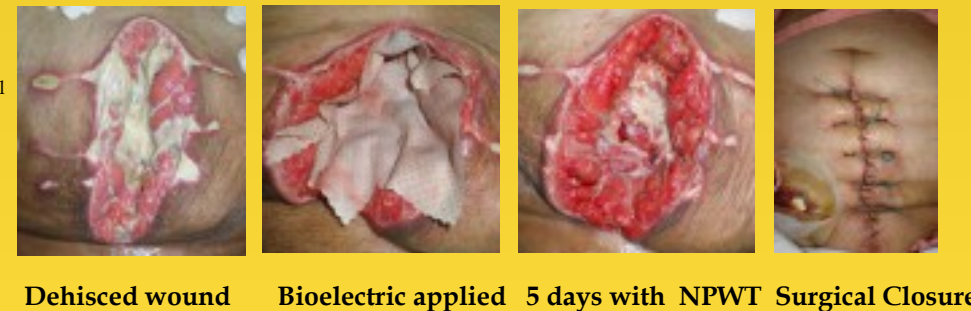Exposed Cartilage

65 y.o. male presented with wound secondary to excision of squamous cell carcinoma. Original tx: non-adherent dressing with vaseline gauze. Bioelectric dressing was easy to apply and served as a barrier to nasal secretion. Epithelialization over bone observed at 2 months.



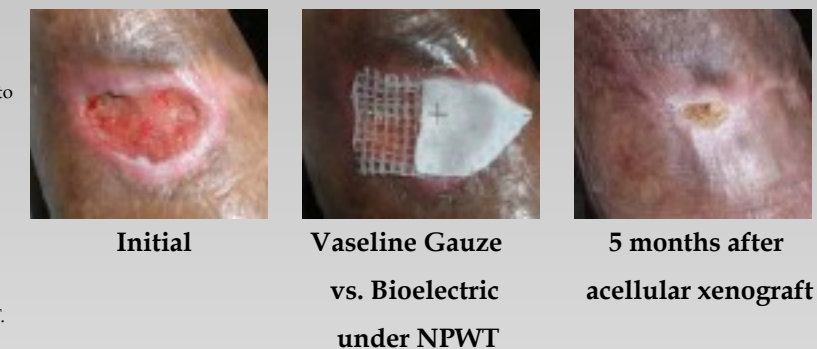
Wound Dehiscence

58 y.o. male presented with abdominal ascites secondary to Peritoneal carcinomatosis. Previous tx: calcium alginate, NPWT. The use of the bioelectric dressing as an adjunct to NPWT better prepared the wound borders for resuturing.



Traumatic Lesion

58 y.o. physician with venous insufficiency presented with a traumatic lesion. Previous tx: hydrocolloid alginate. NPWT used to prepare wound bed. Bioelectric dressing and vaseline gauze were both used and compared as an interface under the NPWT device. When granulation tissue was obtained, an acellular xenograft implant*** and unna boot was applied. Better outcome was observed using the bioelectric dressing as an interface with NPWT.



*Procellera™, Vomeris Innovations, Inc., Chandler, AZ
**Wound V.A.C.®, Kinetic Concepts Inc., San Antonio, TX
***OASIS® Wound Matrix, Healthpoint Ltd., Fort Worth, TX