

# CLINICAL EXPERIENCE WITH A BIOELECTRIC WOUND DRESSING AS A PRIMARY AND ADJUNCTIVE TREATMENT METHOD

STEPHEN BERGQUIST, MD, CWSP

WOUND MANAGEMENT CENTER, JACKSON-MADISON COUNTY GENERAL HOSPITAL, JACKSON, TN

Wound Management Center



Jackson-Madison County General Hospital


An affiliate of West Tennessee Healthcare

BACKGROUND	RESULTS	REFERENCES
<p>There remains a significant need for clinical and cost effective wound healing interventions that can improve quality of life and health and reduce associated healthcare costs. (1) There exist various advanced wound interventions designed to mimic and enhance the healing process and induce a healing response through the administration of an external therapeutic stimulus. (2) While these modalities have demonstrated clinical efficacy, they are oftentimes cost-prohibitive. Specialized multi-modality wound treatment approaches have demonstrated clinical success with long-term cost savings through expediting wound healing processes and reducing risk for infectious complications. A growing body of evidence points to clinically enhanced outcomes with the use of a bioelectric, wireless, current-generating wound dressing<sup>a</sup> either when used as a stand-alone modality or as an adjunct to other advanced therapies (3-5). The dressing produces a low-level microcurrent on its surface in the presence of moisture.</p>	<p>The present case series demonstrates the safety and efficacy of utilizing the bioelectric dressing as an adjunct to biologic dressings. In case 1: application of a bioelectric dressing alone on a non-healing wound that had failed to respond to other advanced modalities resulted in successful wound closure and reduced the need for secondary procedures and other adjunctive therapies. Cases 2 and 3 demonstrated that when used as an adjunct to biologic skin substitutes, the bioelectric dressing may serve as a viable method for wound management for even the most recalcitrant wounds. Despite recurring VLU ulcerations for over 10 years, Case 2 achieved full closure in a 2-month timeframe, reducing the time needed for adjunct care. Case 3, although presenting with multiple comorbidities, achieved complete closure in 4 weeks.</p>	<p>1) Baranoski S, Ayello E (2008) Wound Care Essentials. Practice Principles. Lippincott Williams &amp; Wilkins</p> <p>2) Widgerow AD. Deconstructing the Stalled Wound. Wounds. 2012;24(3)</p> <p>3) Blount A, Foster S, Wilcox R. Use of Bioelectric Dressings for Faster Wound Healing: A Prospective Case Series. [abstract] Plastic &amp; Reconstructive Surgery 2010; 126(4) :97.</p> <p>4) Guberman et.al. Preliminary study findings: Faster wound closure is achieved when the bioelectric dressing is used as an adjunct to Negative Pressure Wound Therapy. [abstract]. Presented at the Diabetic Foot Conference, Los Angeles, CA, March 2010 (suppl).</p> <p>5) Deleon, J et al. The Use of Current Generating Dressings under Negative Pressure. [abstract]. Presented at the Symposium on Advanced Wound Care, Orlando, FL. April 2010; (suppl).</p> <p><sup>a</sup>Procellera<sup>®</sup> Wound Dressing, Vomaris Wound Care, Inc., Chandler, AZ USA  <sup>b</sup>Aquacel<sup>®</sup> Ag, Convatec, Skillman, NJ  <sup>c</sup>Iodosorb, Smith &amp; Nephew, Inc., London, UK  <sup>d</sup>Apligraf<sup>®</sup>, Oranogenesis, Canton, MA  <sup>e</sup>Dermagraft<sup>®</sup>, Shire, San Diego, CA</p>
METHODS	CONCLUSION	
<p>The bioelectric dressing was assessed in a case series of diabetic and venous insufficiency ulcers. The bioelectric dressing was applied either alone or in conjunction with best wound care principles and adjunctive therapies 1-2 times per week. Wounds were evaluated for signs of healing progression at clinic visits.</p>	<p>The present case series demonstrates the safety, efficacy and versatility of the bioelectric dressing as a treatment option for a broad scope of wounds of varying complexities and etiologies. In addition to the value of microcurrents in expediting wound healing in stalled wounds, learnings from this case series points to the importance of moisture balance and wound bed preparation in establishing an optimal wound healing environment. Interventions to speed healing and reduce treatment times or need for advanced treatment modalities may result in overall decreased resource utilization and cost savings.</p>	


## CASE 1: BIOELECTRIC ONLY      CASE 2: BIOELECTRIC + BI-LAYERED LIVING CELL TREATMENT<sup>b</sup>      CASE 3: BIOELECTRIC + HUMAN FIBROBLAST-DERIVED DERMAL SUBSTITUTE<sup>e</sup>

**CASE 1: BIOELECTRIC ONLY**


- 58 y/o male
- Began as a blister on the medial malleolus on 5/27/11
- Began treatment at the Wound Center 6/9/2011
- Dx: Chronic pain and numbness in feet, new onset of DM
- Initial status at Wound Center: eschar, exposed joint, minimal drainage, slight erythema with a measurement of 2.2 x 2.5 x 0.2 cm
- Prior treatments: hydrofiber<sup>b</sup>, cadexomer iodine gel<sup>c</sup>, and sharp debridement




Initial



Day 14

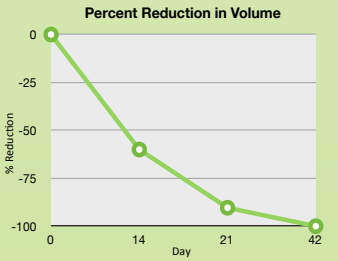


Day 21



Day 42 Closed


**Percent Reduction in Volume**




Day	L (cm)	W (cm)	D (cm)	Volume (cm <sup>3</sup> )
0	1.3	2	0.4	1.04
14	1.6	1.3	0.2	0.416
21	1	1	0.1	0.1
42	0	0	0	0

**CASE 2: BIOELECTRIC + BI-LAYERED LIVING CELL TREATMENT<sup>b</sup>**


- 45 y/o male
- Recurrent leg ulcers for over 10 years
- Tri-phasic arterial flow from vascular studies in Jan. 2011
- Complicating Dx: Venous insufficiency, pain in legs with history of DVTs, recurrent ulcerations
- Initiated Procellera and bi-layered living cell treatment
- on 8/30/11
- 5 Bi-layered living cell treatment applications



Initial

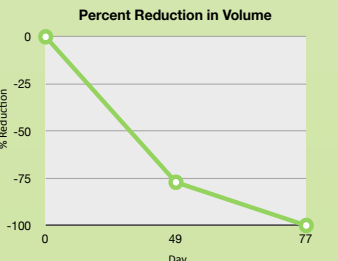


Day 35



Day 63


**Percent Reduction in Volume**




Day	L (cm)	W (cm)	D (cm)	Volume (cm <sup>3</sup> )
0	4.9	2.5	0.2	2.45
49	3.3	1.7	0.1	0.561
63	0.2	0.2	0.1	0.004

**CASE 3: BIOELECTRIC + HUMAN FIBROBLAST-DERIVED DERMAL SUBSTITUTE<sup>e</sup>**


- 54 y/o female
- Dx: HTN, poor circulation, ESRD on dialysis, DM, lupus vasculitis, recent respiratory failure requiring intubation and ICR care, hyperlipidemia, morbid obesity, pancreatitis, meningitis, seizures, 20 year smoking history
- Wound initially presented with eschar. Removal of devitalized tissue via Santyl and sharp debridement.



8/30/11: (wound on right)

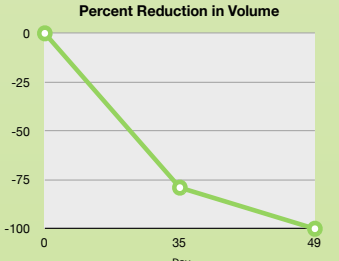


Day 35



Day 49: Closed

**Percent Reduction in Volume**



Day	L (cm)	W (cm)	D (cm)	Volume (cm <sup>3</sup> )
0	5.5	2.7	0.2	2.97
35	2.5	2.5	0.1	0.625
49	0	0	0	0