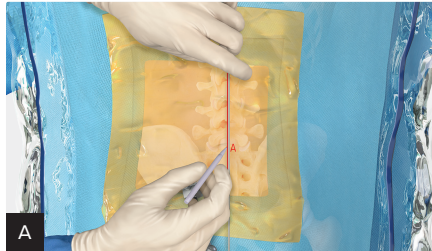


# Transforaminal Approach for Discectomy

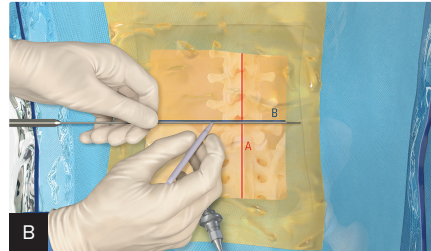
## Quick Reference Guide

View full  
surgical  
technique



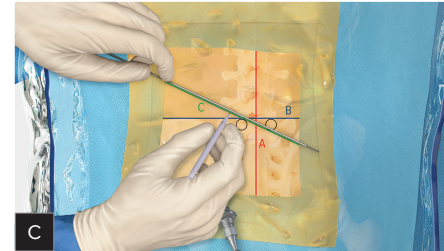
### Midline

- With a blunt dissector, mark the midline using the spinous processes as reference (Line A).



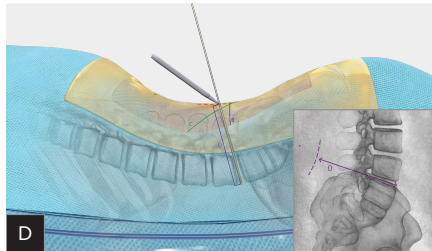
### Disc Space

- Mark the disc space at the level of herniation (Line B).



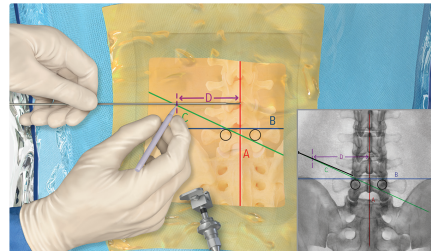
### Oblique Line

- Mark the oblique line from the superior ipsilateral pedicle to the inferior contralateral pedicle (Line C).



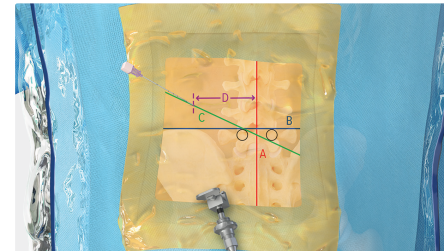
### Measuring Lateral Line

- On lateral x-ray, measure the distance from the ventral disc space to the surface of skin (Line D).



### Marking Lateral Line

- From the midline (Line A), mark a horizontal line that is the length of Line D to intersect the oblique line (Line C). This is your starting point for needle placement.



### Needle Placement