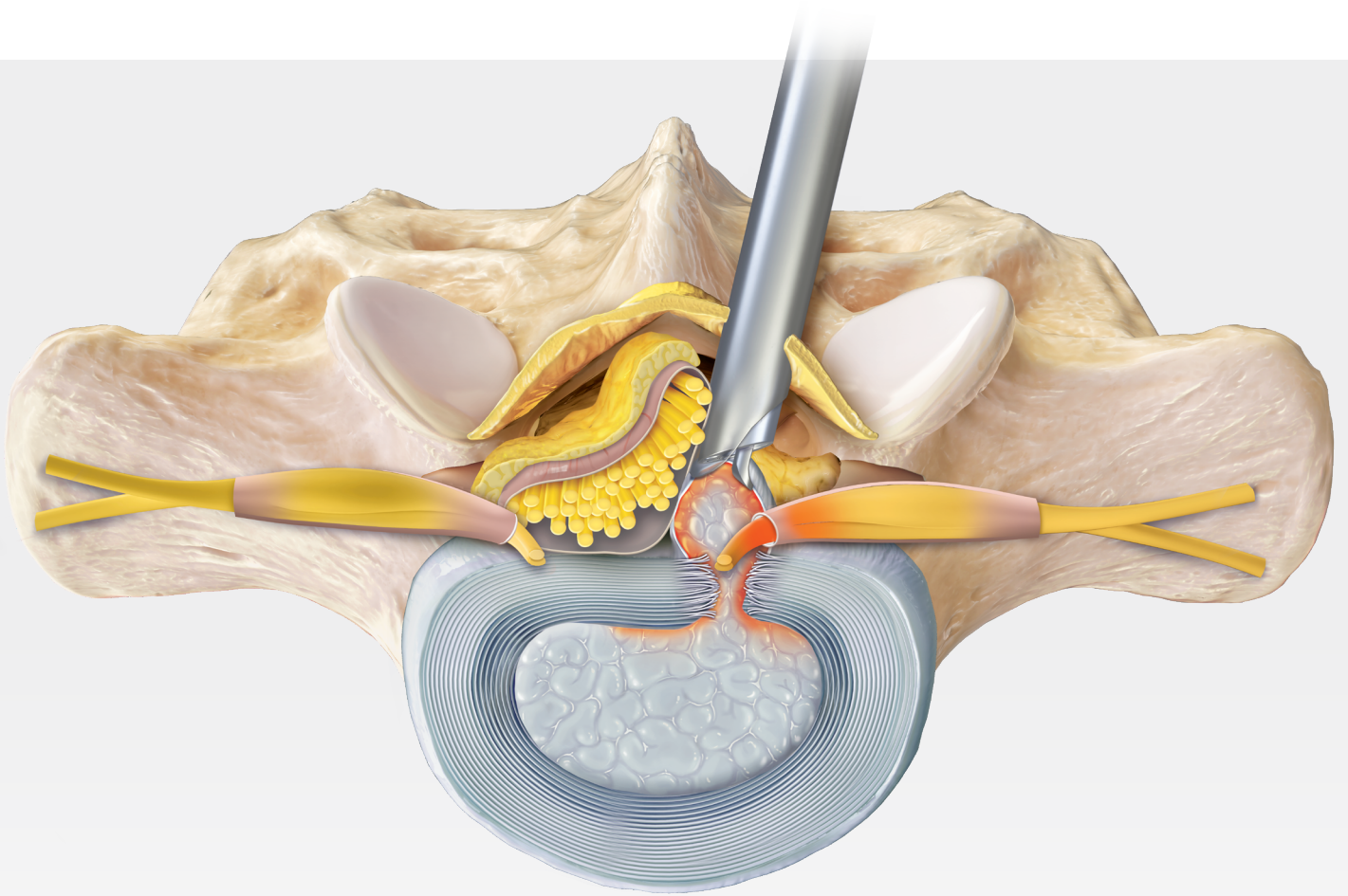


# Lumbar Interlaminar Discectomy

Endoscopic Surgical Technique




# Endoscopic Approach to Interlaminar Discectomy

## Introduction

The endoscopic approach to interlaminar discectomies is an ultra-minimally invasive surgery ideal for patients who have been diagnosed with a paracentral lumbar disc herniation in the lower lumbar spine. During this procedure, a spine-specific endoscope is used for access and visualization. The Synergy imaging system, in conjunction with the ergonomic instruments, provides innovative new technology to treat this pathology.

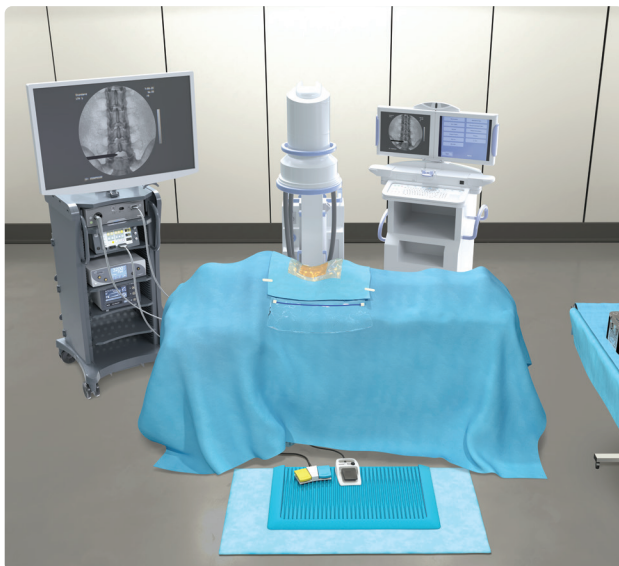
- › WishBone™ handle combines ergonomics, efficiency, and control
- › Synergy integration and imaging optimize visualization
- › Depth stop and cannula holder allow for improved control of the endoscope and cannula
- › Premium instruments are available with a ceramic coating



## 6-Step Method

1. Target the bullseye
2. The click
3. Clean the trampoline
4. Create and identify the black hole
5. Identify the edge
6. Retract and protect

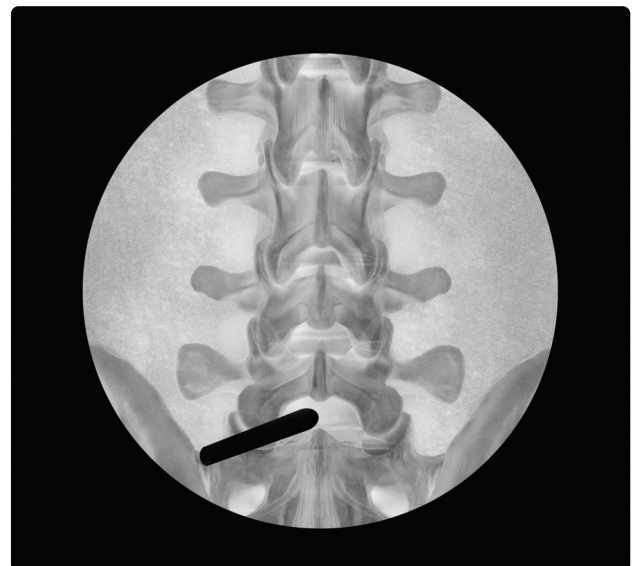
## The Bullseye



1

### Patient Positioning and OR Setup

With the patient prone and their arms extended, position the C-arm across from the surgeon with the video monitor at the head and the C-arm monitor at the foot of the bed.

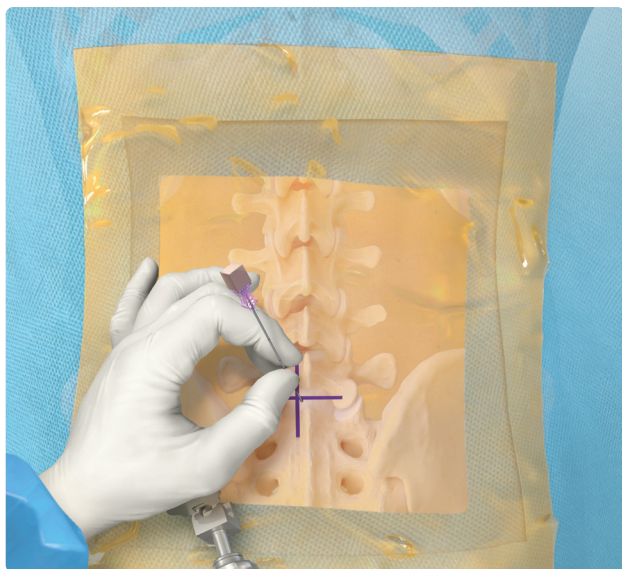


2

### Targeting

Use AP and lateral views to target and confirm the correct level is being treated. Use the switching stick to identify the entry point that is the lateral aspect of the ipsilateral interlaminar window.

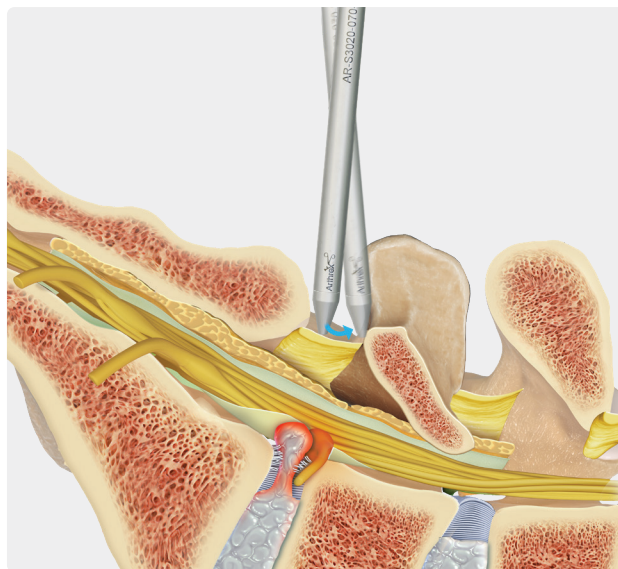
## The Click



3a

### Docking

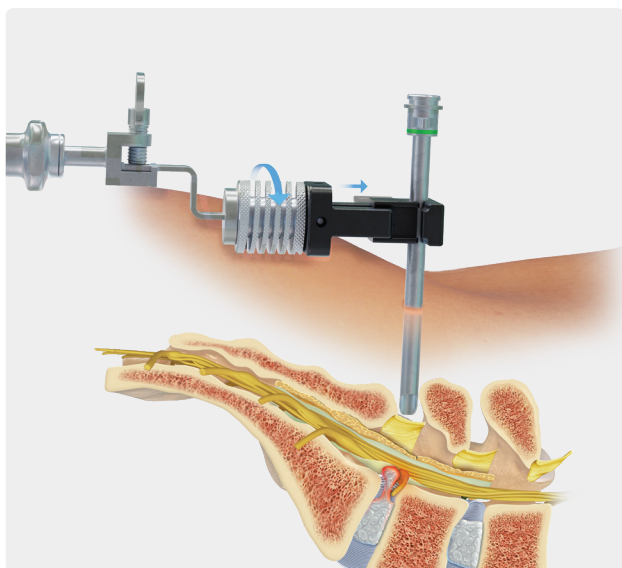
Make an 8 to 10 mm incision through both the skin and fascia. Insert the switching stick into the interlaminar window and on top of the ligamentum flavum. Alternatively, a needle cannula can be placed, followed by a guidewire, skin incision, and sequential dilators.



3b

### Feel the Click

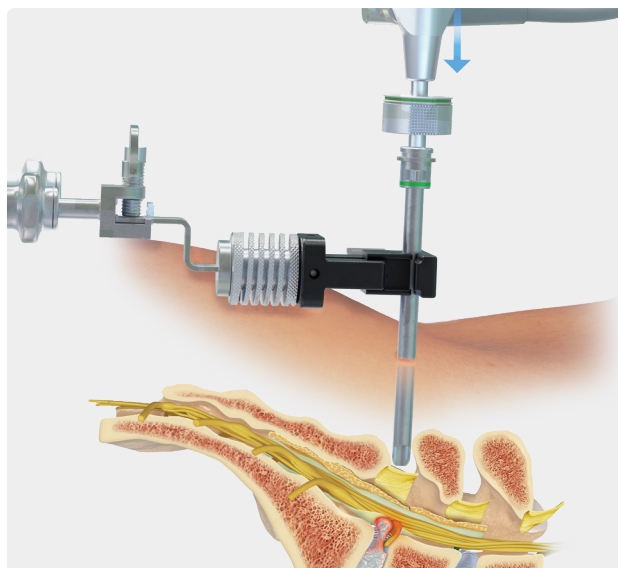
- › Dock the switching stick vertically on the trailing edge of the L5 lamina (for L5-S1 discectomy).
- › Use the switching stick to “click” between the caudal edge of the lamina and the ligamentum flavum (LF).
- › Use tactile feedback to feel the “bounce” of the LF and confirm your location in the interlaminar window.



4

### Cannula Holder and Depth Stop

Insert the cannula over the switching stick. With the spine TRIMANO arm holder attached to the bed via a bed rail adapter, connect the cannula holder. Maintain the trajectory and location of the cannula to the anatomy while positioning and attaching the holder to the cannula.



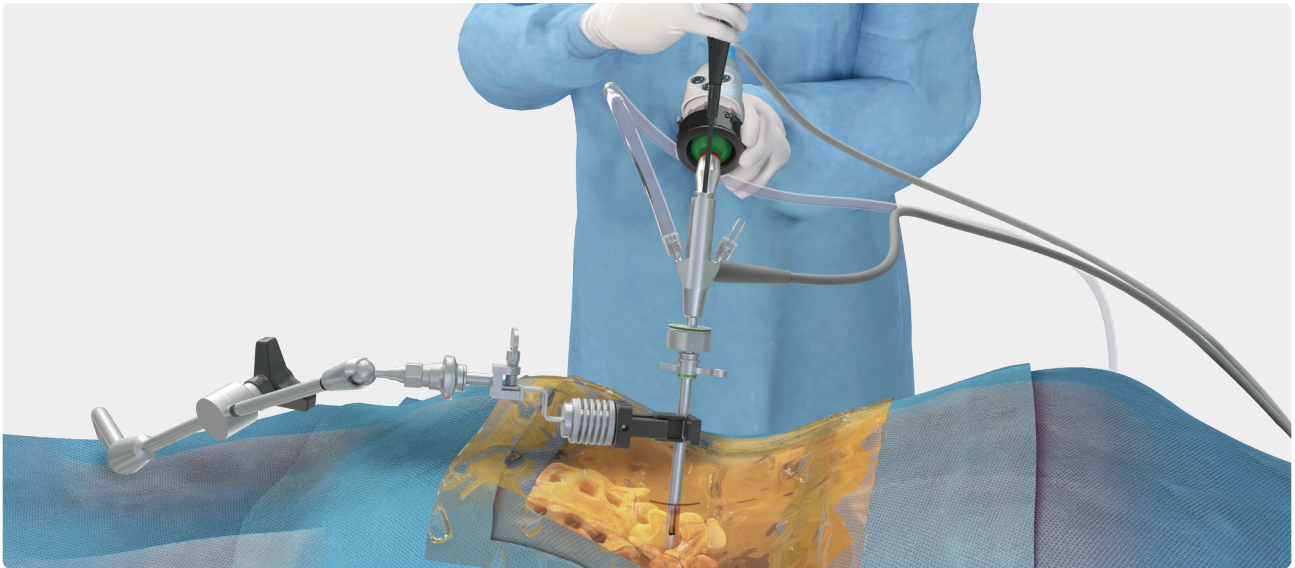
5

### Set Up and Insert Endoscope

Attach the light cord camera, irrigation, and depth stop to the endoscope. Following removal of the switching stick, insert the endoscope light cord, camera into the cannula.



## Cleaning the Trampoline

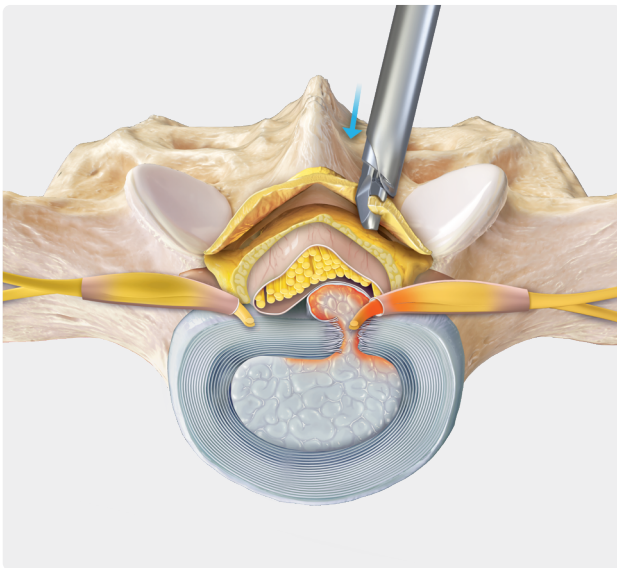


6

### Dissect Tissue and Visualize

After inserting the endoscope, insert a series of grasping instruments and the FlexTip probe through the endoscope's working channel. Remove excess tissue and coagulate blood vessels to identify anatomical landmarks and expose the ligamentum flavum.

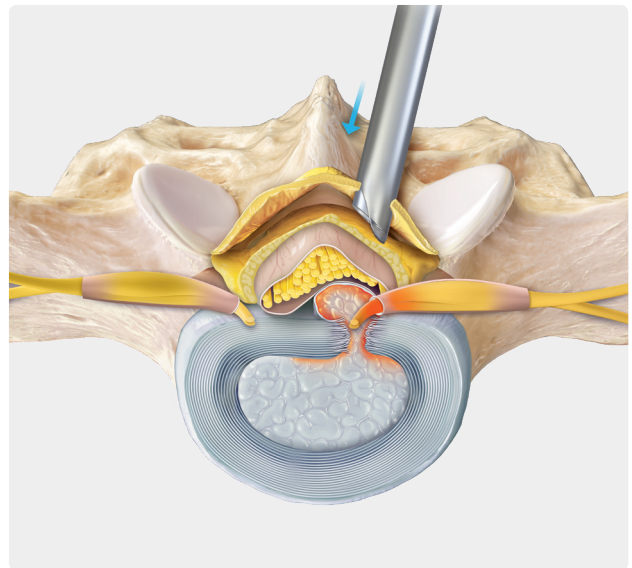
## The Black Hole



7

### Access Spinal Canal

Use both straight and angled scissor punches to resect the ligamentum flavum and gain access to the spinal canal. Maintain visibility of the working end of the instruments while incising and resecting the ligament. Orient the scissor punches with the longer, nonactuated end of the instrument medial while creating the black hole and incising through the final ligament fibers.



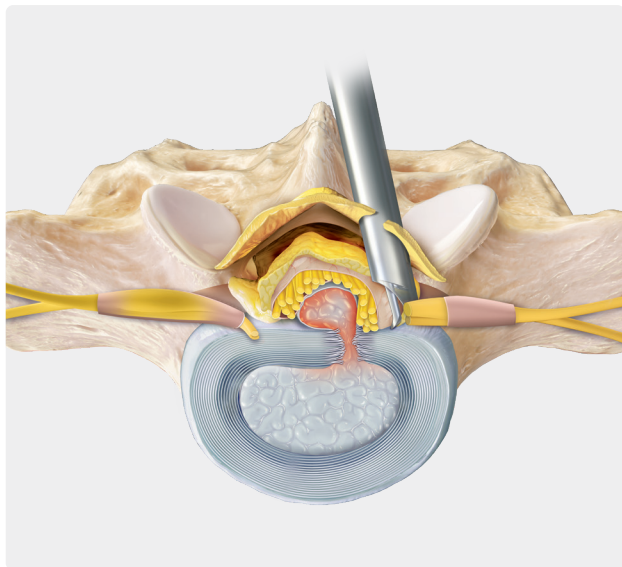
8

### Scissor Punches

After transecting the ligament and entering the canal, pause to let the irrigation and positive pressure help create space between the ligament and the dura. Widen the ligament access by using a combination of scissor punches, Kerrison rongeurs, and downward pressure with cannula rotation to stretch and separate the ligament fibers. While accessing the canal with the cannula, maintain the orientation of the cannula so the bevel faces medial.



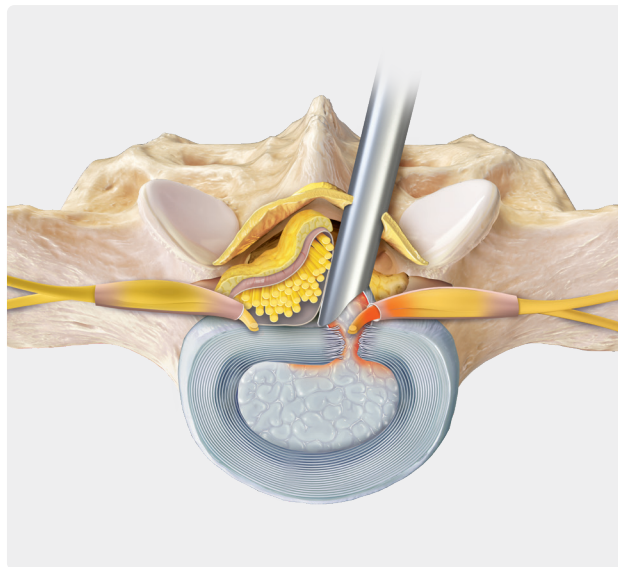
## Identify the Edge of the Nerve Root



9

### Mobilize the Nerve Root

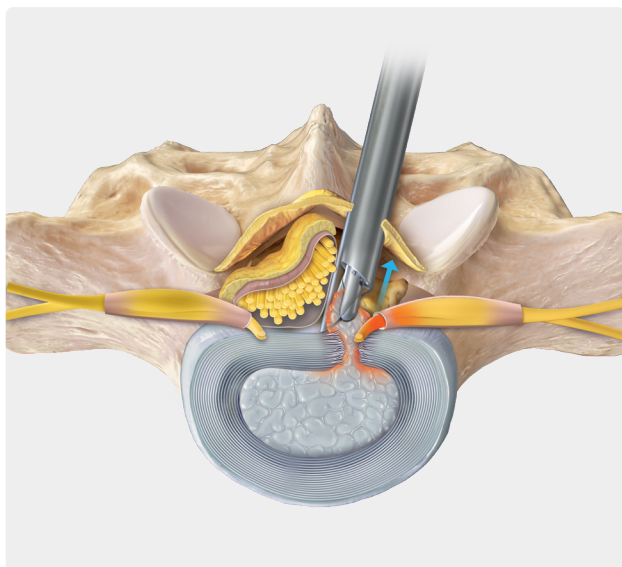
Use instruments such as the blunt dissector, nerve hook, and articulating probe to release any adhesions that may be adhered to the dura. Continue to work and visualize the lateral margin of the nerve root. If necessary, rotate the camera 180° to use the scope lens angle to gain a more lateral view of the anatomy.



10

After mobilizing the nerve root, advance and rotate the cannula to retract and protect the nerve root. With the nerve root protected, use a blunt instrument to apply pressure on the annulus, releasing the nucleus pulposus.

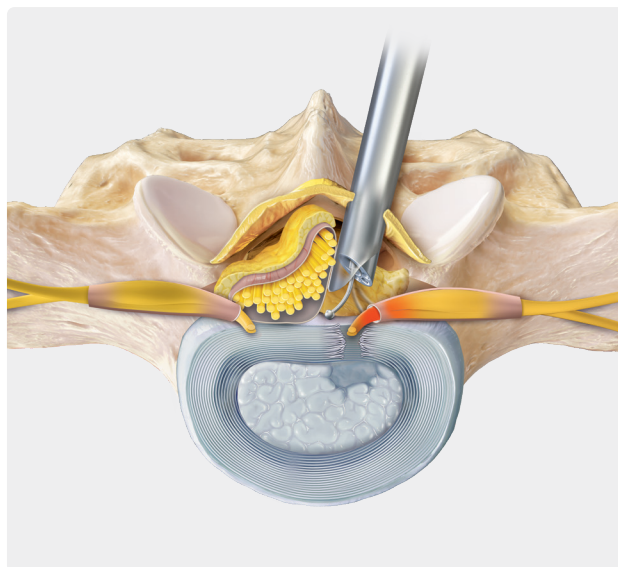
## Retract and Protect



11

### Resect

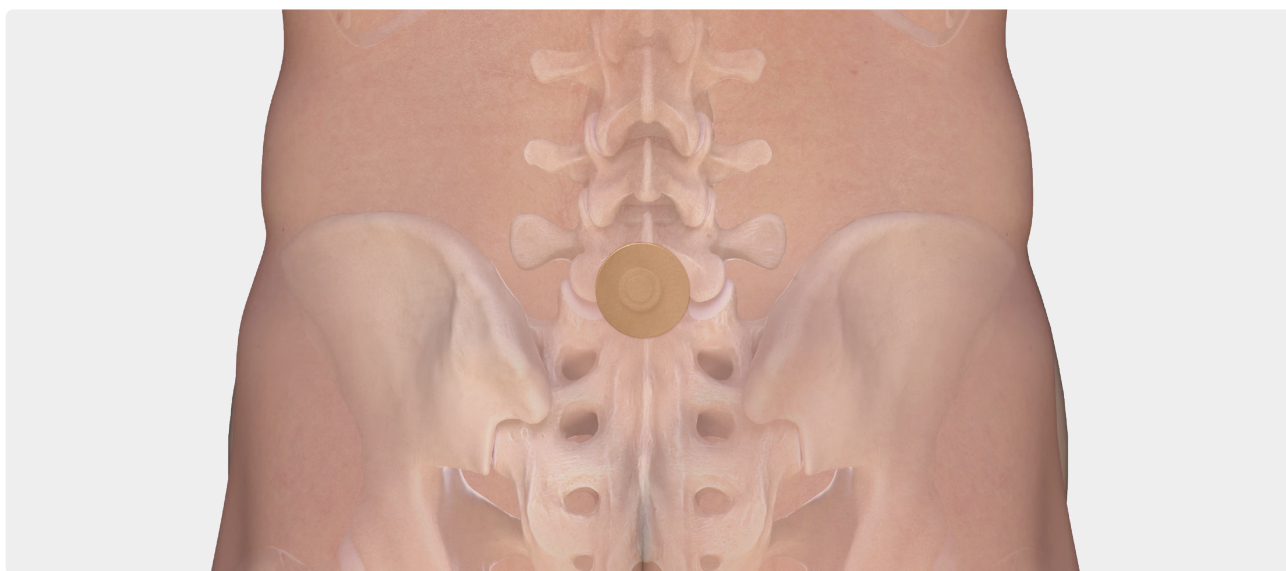Use grasping forceps to extract the exposed nuclear material. Use the electrosurgery probe to ablate nuclear material and minimize the annular defect.



12

### Assess

Use visualization and the ball tip probe to assess the mobility of the nerve root and ensure adequate decompression.

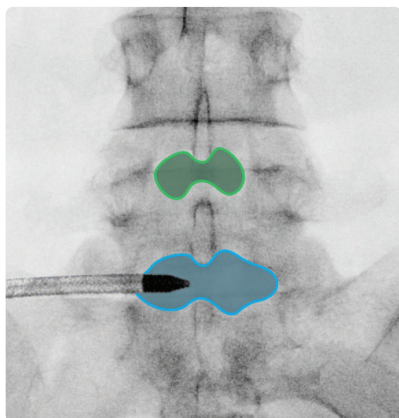


13

### Complete Procedure

Remove the endoscope and cannula, close the incision, and apply JumpStart antimicrobial wound dressing over the incision site.

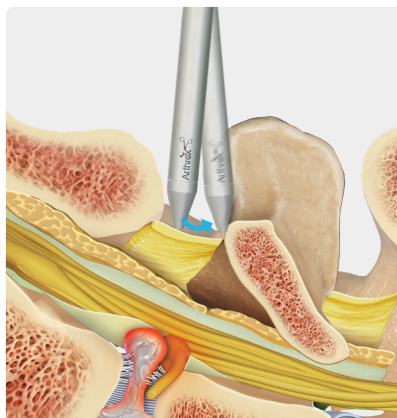## 6-Step Method Quick Reference



1

### Target the Bullseye

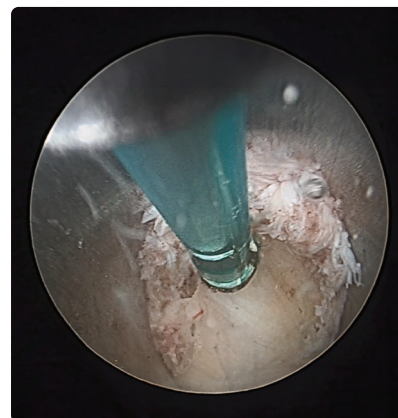
- › Place a switching stick in the middle of the ipsilateral interlaminar window.
- › Use a #11 or #15 blade to create an incision <1 cm in length through the skin and lumbar fascia.
- › Use fluoroscopy to confirm positioning.



2

### The Click

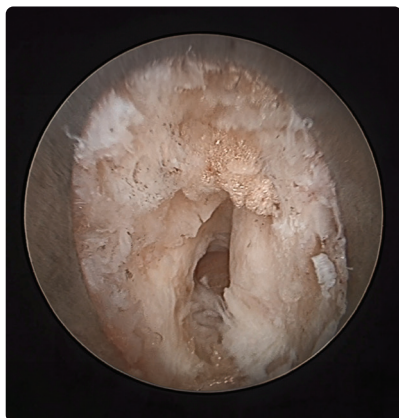
- › Dock the switching stick vertically on the trailing edge of the L5 lamina (for L5-S1 discectomy).
- › Use the switching stick to “click” between the caudal edge of the lamina and the ligamentum flavum (LF).
- › Use tactile feedback to feel the “bounce” of the LF and confirm your location in the interlaminar window.



3

### Clean the Trampoline

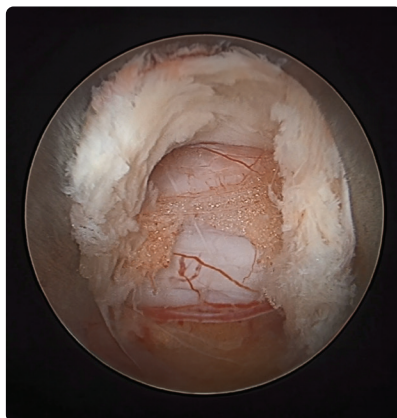
- › Cauterize 360° around the cannula.
- › Use a pituitary rongeur and FlexTip probe to remove tissue on top of the LF.



4

### Create and Identify the Black Hole

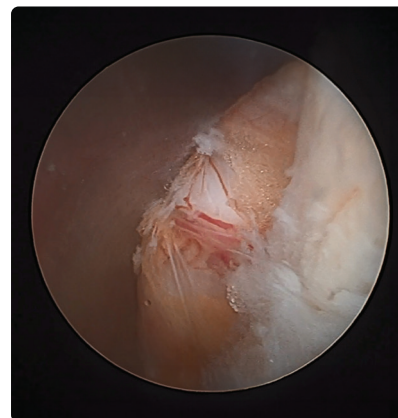- › Rotate the cannula, using its tip to tension the remaining LF fibers.
- › Use endoscopic scissors to incise through the LF.
- › After encountering the black hole, pause to allow fluid to fill the space, ensuring protection of the dura.



5

### Identify the Edge

- › Rotate the endoscope to view the lateral edge, looking for the white stripe against the epidural fat, which is the edge of the nerve root.
- › Use the tissue dissector to palpate and define the edge of the nerve by dissecting the adhesions.



6

### Retract and Protect

- › Inside the spinal canal, wand the cannula from lateral to medial to free up adhesions to the disc herniation.
- › Rotate the opening of the cannula so it faces lateral, protecting the nerve root medially and delivering the herniation into the cannula.



## Ordering Information

Spine endoscope case	AR-S1000-C3
Spine endoscope case, large	AR-S1000-C1
Blunt dissector, 2.5 mm × 310 mm	AR-S1342-025-310
Switching stick, 7 mm × 225 mm	AR-S3020-070-225
Spine endoscope, 7 mm × 130 mm, 15°	AR-S3350-7015-130
Cannula w/ elevator tip, 8 mm × 125 mm	AR-S3420-080-125ET
Guidewire, nitinol, 0.8 mm × 400 mm	AR-S4000-008-400
Cup forceps, up angle, 2.5 mm × 330 mm, WB	AR-S7110-025U-330W
Cup forceps, 3 mm × 330 mm, WB	AR-S7110-030-330W
Cup forceps, 2.5 mm × 330 mm, WB	AR-S7110-025-330W
Scissor punch, 2.5 mm × 330 mm, WB	AR-S7116-025-330W
Scissor punch, up angle, 2.5 mm × 330 mm, WB	AR-S7116-025U-330W
Kerrison/ball tip probe, handle, WB	AR-S7400-000-000W
Kerrison, 3.5 mm × 260 mm, 40°	AR-S7440-035-260
Kerrison, 4 mm × 260 mm, 40°	AR-S7440-040-260
Kerrison, 4 mm × 260 mm, 90°	AR-S7490-040-260
Ball tip probe, shaft, flexible, 1.8 mm × 330 mm	AR-S7405-018-330
Dilator Holder	ML-0057
FlexTip RF probe, 28 cm	AR-S9805-010-0028
Spine Access Kit, disposable	AR-S4000K-S

See product catalog for full product listings. Instruments dependent on surgeon preferences and pathology.

TRIMANO is a registered trademark of Maquet GmbH.

This description of technique is provided as an educational tool and clinical aid to assist properly licensed medical professionals in the usage of specific Arthrex products. As part of this professional usage, the medical professional must use their professional judgment in making any final determinations in product usage and technique. In doing so, the medical professional should rely on their own training and experience and should conduct a thorough review of pertinent medical literature and the product's directions for use. Postoperative management is patient-specific and dependent on the treating professional's assessment. Individual results will vary and not all patients will experience the same postoperative activity level or outcomes.



Arthrex manufacturer, authorized representative, and importer information (Arthrex eIFUs)



US patent information