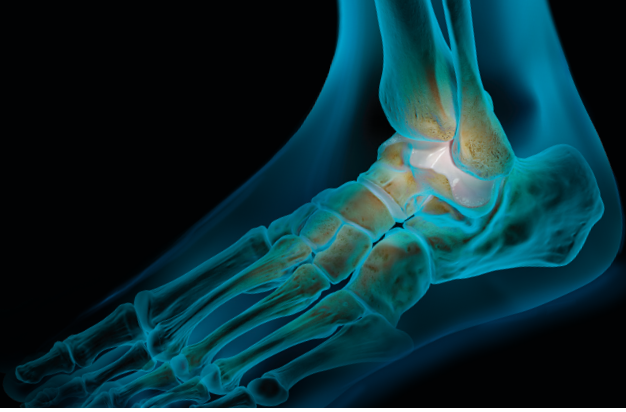

Arthrex Presents:

Breakthroughs in Foot and Ankle Technology

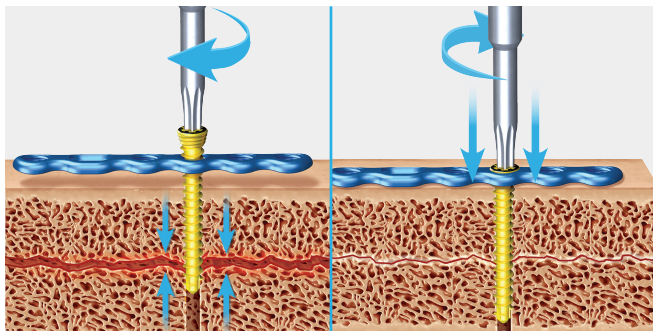
Fall 2021

Welcome to the AOFAS Annual Meeting. Arthrex remains committed to servicing all of your metal, soft-tissue, arthroscopic, and trauma solutions for foot and ankle pathologies. Following what has been an unexpected year for all, we look forward to seeing you back at the booth to meet our staff of product managers and engineers who are all here to help you experience what we can offer in support of our mission of Helping Surgeons Treat Their Patients Better™. Take special note of our recent innovations in trauma technology with the launches of our KreuLock™ locking compression screws as well as our Primary Pilon Fusion Plating System to address complex, high-energy pilon fractures. Information on courses is listed on our website, and we hope to see you all in Naples soon. Stay safe and have a great meeting!

Pete Denove

Senior Director, Product Management
Distal Extremities and Trauma

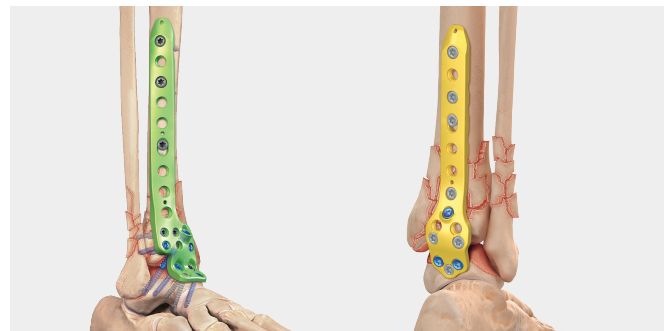KreuLock Locking Compression Screws



The KreuLock locking compression screws combine the proven technology of the Headless Compression FT screws with a locking screw head to provide compression along the screw for treatment of fractures or fusions. They will also bring the plate to the bone.

- Variable-Stepped Thread Pitch—the screw tip's wider thread pitch enters the bone faster than trailing threads, gradually compressing the fragments as the screw is advanced
- Locking Head—mates with existing plates
- Individual screw and instrument modules for each screw family
- Available in titanium and stainless steel

Primary Pilon Fusion Plating System



The Arthrex Primary Pilon Fusion System was designed for treatment of distal tibia fractures that require not only fracture reduction but also primary ankle arthrodesis. Severe damage to the tibiotalar (TT) joint results in posttraumatic arthritis, pain, stiffness, and the need for secondary surgeries. The Primary Pilon Fusion System provides another option to address these severe fracture patterns with primary TT arthrodesis of the articular surface to avoid secondary surgery and chronic pain. Additionally, the anterolateral and posterior plating options can be utilized for complex primary and revision ankle fusions where more fixation options and longer bridging techniques may be necessary.

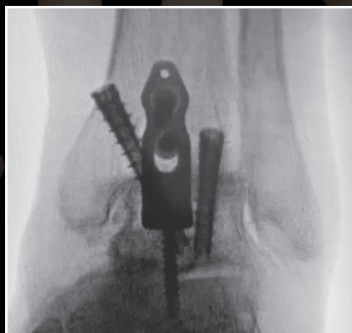

Minimally Invasive Arthrex Ankle Fusion Plate

Small Footprint, Huge Impact

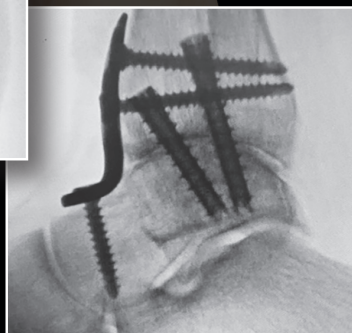Compared to the standard 3-screw fusion construct, the addition of an anterior plate increases construct rigidity and decreases micromotion at the ankle fusion interface without the need for an extensile incision.¹

- Arthroscopic approach/reduced skin incision
- Plate acts as a tension band to resist plantar flexion
- Increased construct rigidity compared to a 3-screw fusion¹



AP View

X-rays courtesy of David Dalstrom, MD (San Diego, CA)



Lateral View



Osteotome Angled Up, 5.5 mm



Osteotome Angled Up, 12 mm



Osteotome Straight 5.5 mm



Osteotome Straight 12 mm



Cup Curette Straight, 6 mm



Cup Curette Curved, 6 mm



Reference

1. Tarkin IS, Mormino MA, Clare MP, Haider H, Walling AK, Sanders RW. Anterior plate supplementation increases ankle arthrodesis construct rigidity. *Foot Ankle Int.* 2007;28(2):219–223. doi:10.3113/FAI.2007.0219

Arthrex
Ad.Arthrex.com/MIAP

New Product Highlight

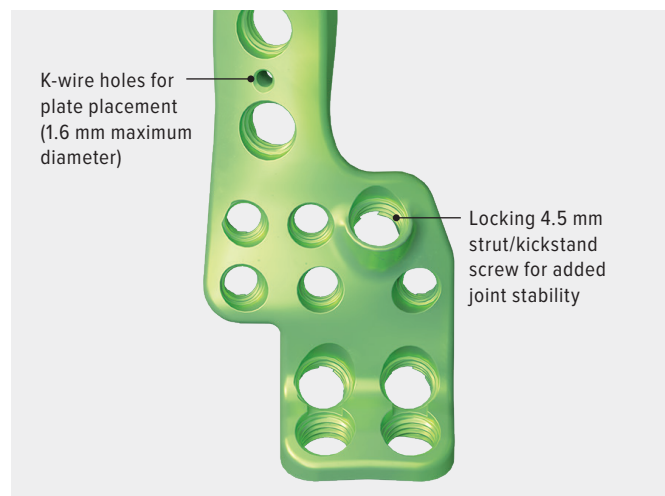
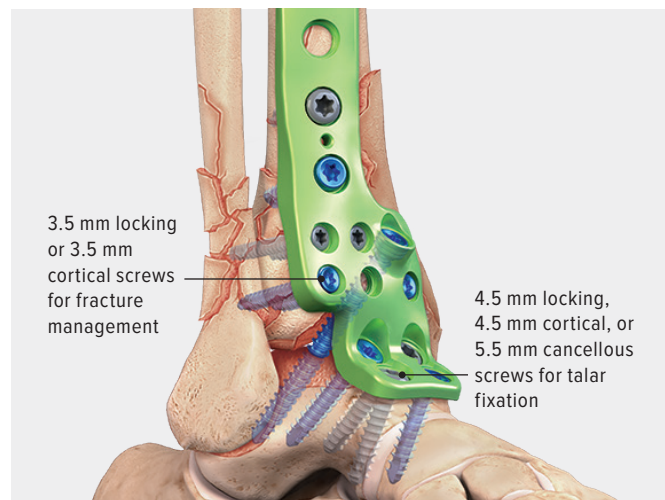
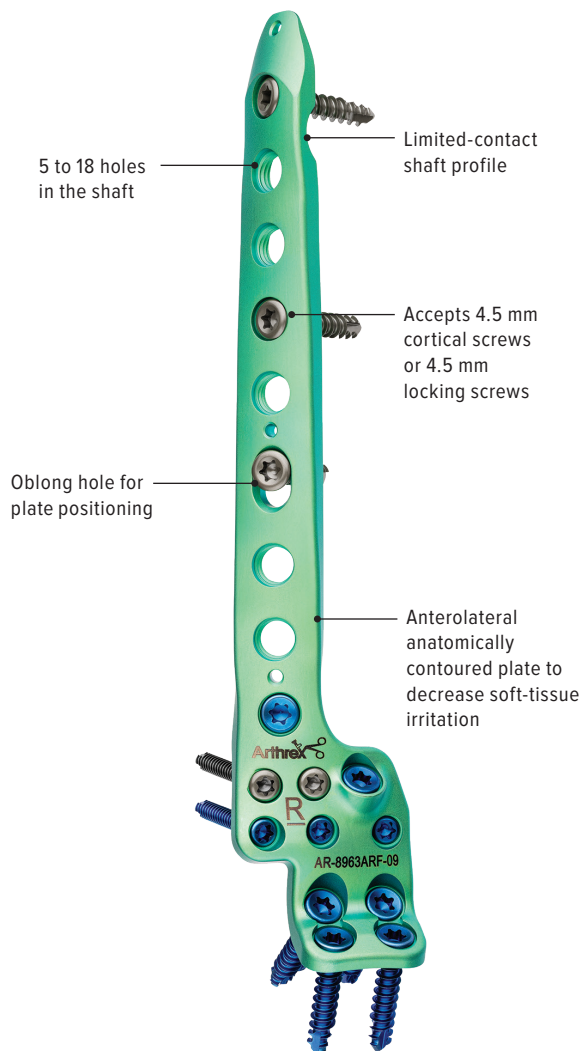
Primary Pilon Fusion Plating System

Anterolateral Pilon/Tibiotalar Fusion Plate Design

The anterolateral plate has two rows of distal 3.5 mm locking or 3.5 mm cortical screws to address complex, high-energy pilon fractures. The use of 3.5 mm screws distally allows for a high density of screw fixation and additional options for fracture reduction. The tibial shaft and talus fixation points can use a combination of 4.5 mm locking, 4.5 mm cortical, and 5.5 mm cancellous screws for increased strength across the ankle joint. An oblong slot and K-wire/BB-Tak holes facilitate proper plate placement and provisional fixation.

The anatomic distal contour allows for robust fixation across the ankle joint while providing the maximum number of fixation points for a successful fusion.

- Plate lengths: 5-hole (112 mm), 7-hole (137 mm), 9-hole (163 mm), and 12-hole (201 mm)
- Sterile options: 15-hole (239 mm) and 18-hole (277 mm)



New Product Highlight

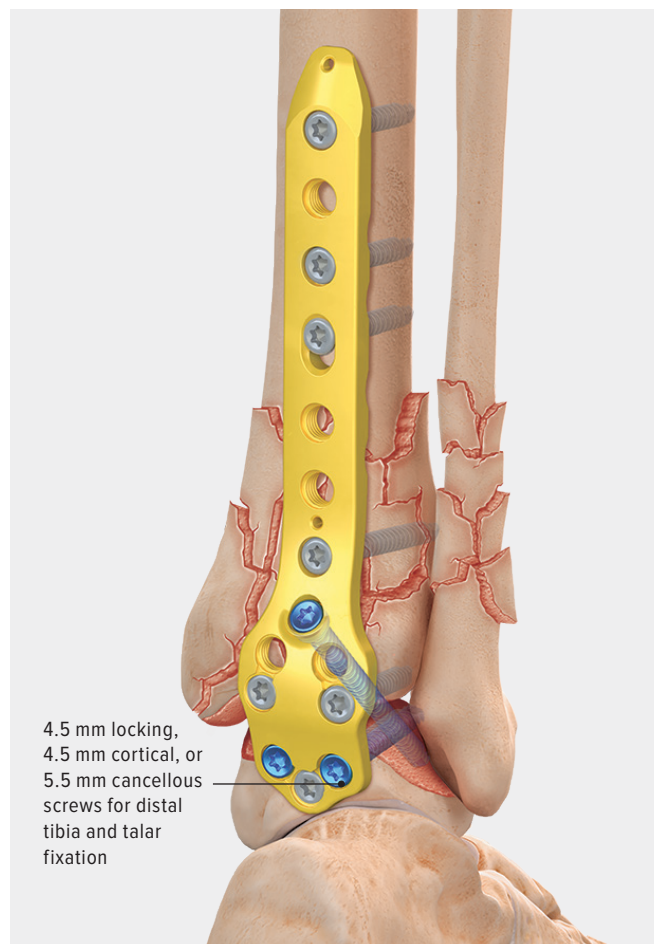
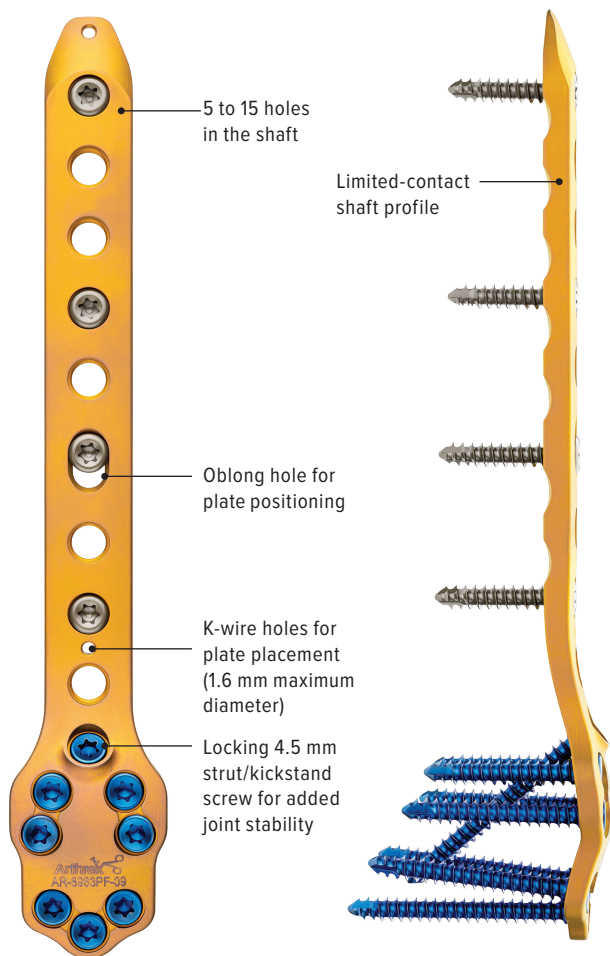
Primary Pilon Fusion Plating System (Cont.)

Posterior Pilon/Tibiotalar Fusion Plate Design

The posterior plate has two rows of distal 4.5 mm locking or 4.5 mm nonlocking cortical screws to address complex, high-energy pilon fractures for a successful fusion. With three points of fixation in the talus, along with the locking kickstand screw across the ankle joint, the posterior plate provides a robust buttress effect for addressing fracture reduction while providing the spatial arrangement and stability needed to maintain talus positioning for tibiotalar arthrodesis.

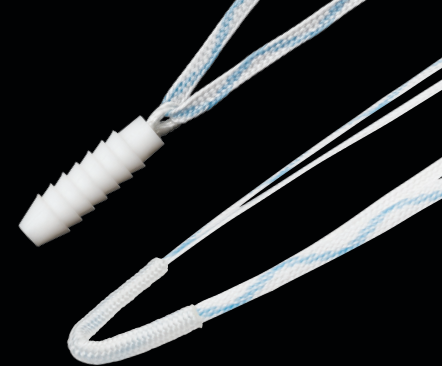An oblong slot and K-wire/BB-Tak holes facilitate proper plate placement and provisional fixation. The anatomic distal contour allows for robust fixation across the ankle joint while providing the maximal number of fixation points.

- Plate lengths: 5-hole (119 mm), 7-hole (145 mm), 9-hole (170 mm), 12-hole (208 mm)
- Sterile options: 15-hole (246 mm)



New Product Highlight

3.0 mm BioComposite SutureTak® Anchor With SutureTape and DX FiberTak® Anchor Double-Loaded With 0.9 mm SutureTape



3.0 mm BioComposite SutureTak Anchor With SutureTape

- Single-loaded with 1.3 mm SutureTape
- Double-loaded with 0.9 mm SutureTape
- Needles attached
- Step drill, 2.4 mm (recommended)
- Drill depth, 20 mm

AR-8934BCST – BioComposite SutureTak Anchor with 1.3 mm SutureTape

AR-8934BCST-2 – BioComposite SutureTak Anchor double-loaded with 0.9 mm SutureTape

Key Features and Benefits

- **Excellent Cortical Purchase** with ridges along their entire length, these anchors provide exceptional pull-out in harder cortical bone¹
- **Minimized Suture Abrasion**—SutureTape-on-suture eyelet interface avoids the type of wear that can occur between an anchor and suture
- **Preloaded** with tapered needles and SutureTape, providing excellent strength in a smaller size¹
- **Straightforward Technique** with a simple, shorter instrumentation and technique creates a reliable and quick procedure
- **Proven Material** where the BioComposite SutureTak is manufactured from PLDLA and β -TCP (beta-tricalcium phosphate)

DX FiberTak Anchor Double-Loaded With 0.9 mm SutureTape

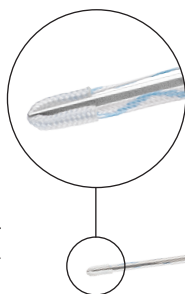
- Anchor sheath
- Double-loaded with 0.9 mm SutureTape
- Needles attached
- K-wire drill, 1.35 mm (recommended)
- K-wire drill, 1.6 mm (hard bone)
- Drill depth, 15 mm

Key Features and Benefits

- **Minimal Bone Removal**—Creating more room for *InternalBrace*™ ligament repair for lateral ankle ligament instability.
- **Tremendous Pull-Out Strength**—Equivalent to 3.0 mm BioComposite SutureTak anchor.²⁻⁴ Surgeons can be confident in the ability of this anchor.

Pull-Out Strength⁵:

- 1.35 mm: 48 lbf
- 1.6 mm: 33 lbf



AR-8990ST-2



References

1. Arthrex, Inc. Data on file (APT-05066). Naples, FL; 2021.
2. Arthrex, Inc. Data on file (APT-03508). Naples, FL; 2018.
3. Arthrex, Inc. Data on file (APT-03296). Naples, FL; 2017.
4. Arthrex, Inc. Data on file (APT-05068). Naples, FL; 2021.
5. Arthrex, Inc. Data on file (APT-05303). Naples, FL; 2021.

Case Report

Titanium Posterolateral Fibula Locking Plate



Andrew J. Rosenbaum, MD

Case 1: 58 y/o female s/p twisting injury to right ankle while walking her dog

PMHx: Hypertension, hyperlipidemia, osteopenia

Allergies: Nickel

Injury: Displaced lateral malleolus fracture with subtle medial clear space widening

Physical Exam: Mild swelling, pain on palpation of lateral malleolus and deltoid ligament complex, neurovascularly intact

Assessment: Displaced lateral malleolus fracture with subtle medial clear space widening

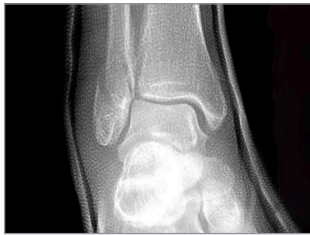

Figure 1a

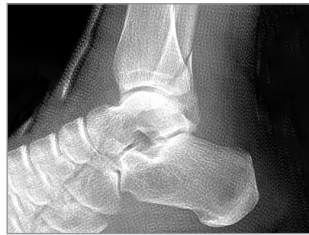

Figure 1b

Plan: Open reduction and internal fixation

Considerations: Locking screw options preferable given osteopenia history; possible need for syndesmotic fixation, titanium implants due to nickel allergy

Definitive Fixation: I chose the titanium posterolateral fibula plate because of patient's underlying comorbidities and nickel allergy.

Technique

- I make an incision over the posterior third of the fibula, as this allows for visualization of the incisura as well if needed for syndesmotic reduction
- Subperiosteal dissection continues, removing interposed soft tissue at fracture site. **This is a critical step to ensure an anatomic reduction!**
- Lobster clamps preferred as pointed resection clamps can cause further comminution, especially in osteopenic bone
- 3.5 mm cortical lag screw placed next (3.0 mm low-profile screw can be used if smaller diameter lag screw needed; is available in titanium ankle fracture set)

Technique (Cont.)

- Posterolateral distal fibula plate than placed to neutralize fracture
- I try for a minimum of 4 cortices of proximal fixation when syndesmosis is concurrently addressed, and 6 cortices when fracture fixed in isolation
- Distal lateral malleolus fixation with 3.0 mm variable-angle locking screws due to osteopenic bone
- Cotton testing and external rotation stress testing performed once I confirm anatomic reduction of fibula fracture
- Syndesmosis addressed with dynamic TightRope® XP fixation (Figures 1c and 1d)

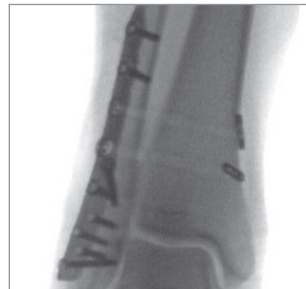

Figure 1c

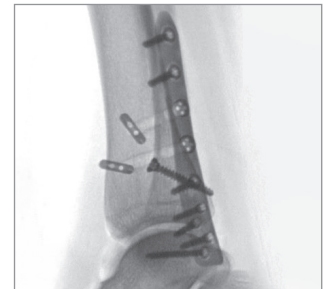

Figure 1d

Post-Op Protocol

- NWB in Jones splint × 2 weeks
- WBAT in CAM boot from weeks 2-6
- Physical therapy begins after 6 weeks, with ability to transition into shoes as tolerated

The titanium posterolateral distal fibula plate provides another great option within the Arthrex Ankle Fracture System, particularly in those patients with nickel allergies. It creates less soft-tissue irritation compared to standard lateral distal fibular locking plates, while also minimizing impingement on the peroneal tendons, as seen with other posterior plating. The ability to incorporate 3.0 mm variable-angle locking screws ensures excellent fixation in osteoporotic or comminuted fractures. The plate can be easily applied to the posterolateral fibula via a standard lateral exposure, which most surgeons are comfortable with.

Case Report

Titanium Medial Hook Plate



Andrew J. Rosenbaum, MD

Case 2: Young male s/p twisting injury to left ankle after slipping in bathroom (7 weeks s/p flatfoot reconstruction)

PMHx: None

PSHx: Staged flatfoot reconstruction (left side performed 7 weeks prior)

Injury: Transitional distal tibia fracture with impaction through distal tibial physis

Physical Exam: Difficulty tolerating long leg cast initially placed in ED, neurovascularly intact

Assessment: Displaced transitional distal tibia fracture with intra-articular extension

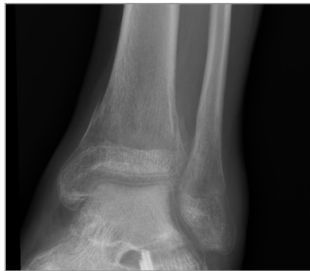

Figure 2a

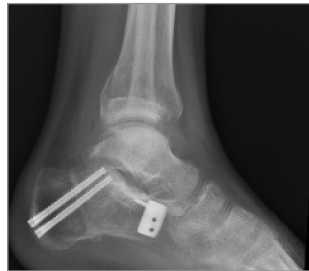

Figure 2b

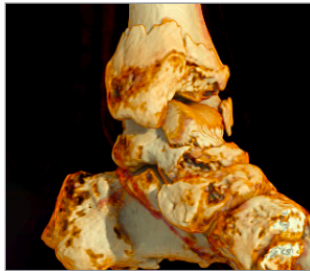


Figure 2c

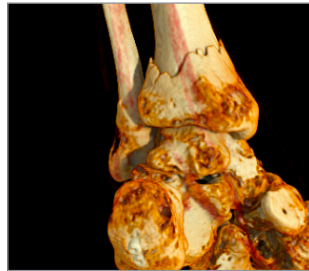

Figure 2d

Considerations: Mild displacement, intra-articular extension, difficulty tolerating long leg cast, recent ipsilateral flatfoot reconstruction (recent prolonged immobilization)

Plan: ORIF to facilitate improved reduction, earlier range of motion, and due to difficulty tolerating long leg cast. I chose the medial titanium hook plate as I felt distal tibia plates would be too large for patient. I planned to supplement with titanium 2.4 mm Mini Comprehensive Fixation System (Mini CFS) if further fracture-specific fixation needed.

Technique

- Medial approach to distal tibia along subcutaneous border
- Structures at risk: Saphenous vein and nerve directly in field! Can be retracted either anteriorly or posteriorly
- Reduction with gentle traction and rotation
- Provisional stability achieved with K-wire fixation
- Medial hook plate applied to stabilize medial column
- 3.5 mm screws in tibia and 3.0 VAL and nonlocking placed in medial malleolus
- Additional posteromedial and anteromedial fractures identified and reduced and stabilized with 2.4 mm Mini CFS plates (Figures 2f and 2g)

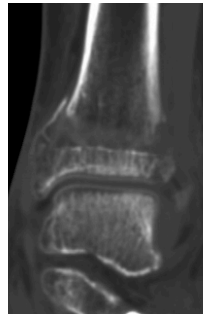

Figure 2e

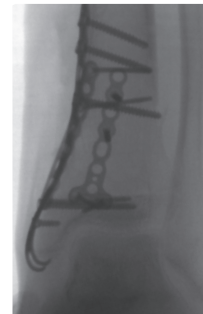

Figure 2f

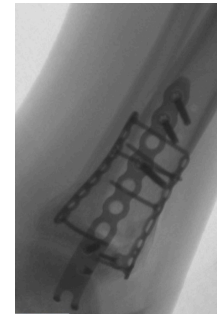

Figure 2g

Post-Op Protocol

- NWB for 2 weeks in splint
- NWB in CAM boot × 4 weeks with AROM allowed
- Protected WB in CAM × 2-4 weeks with PT helping to transition into shoes over that time

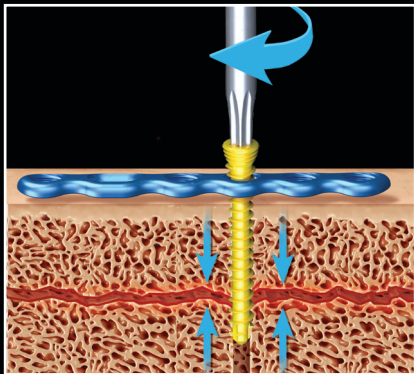
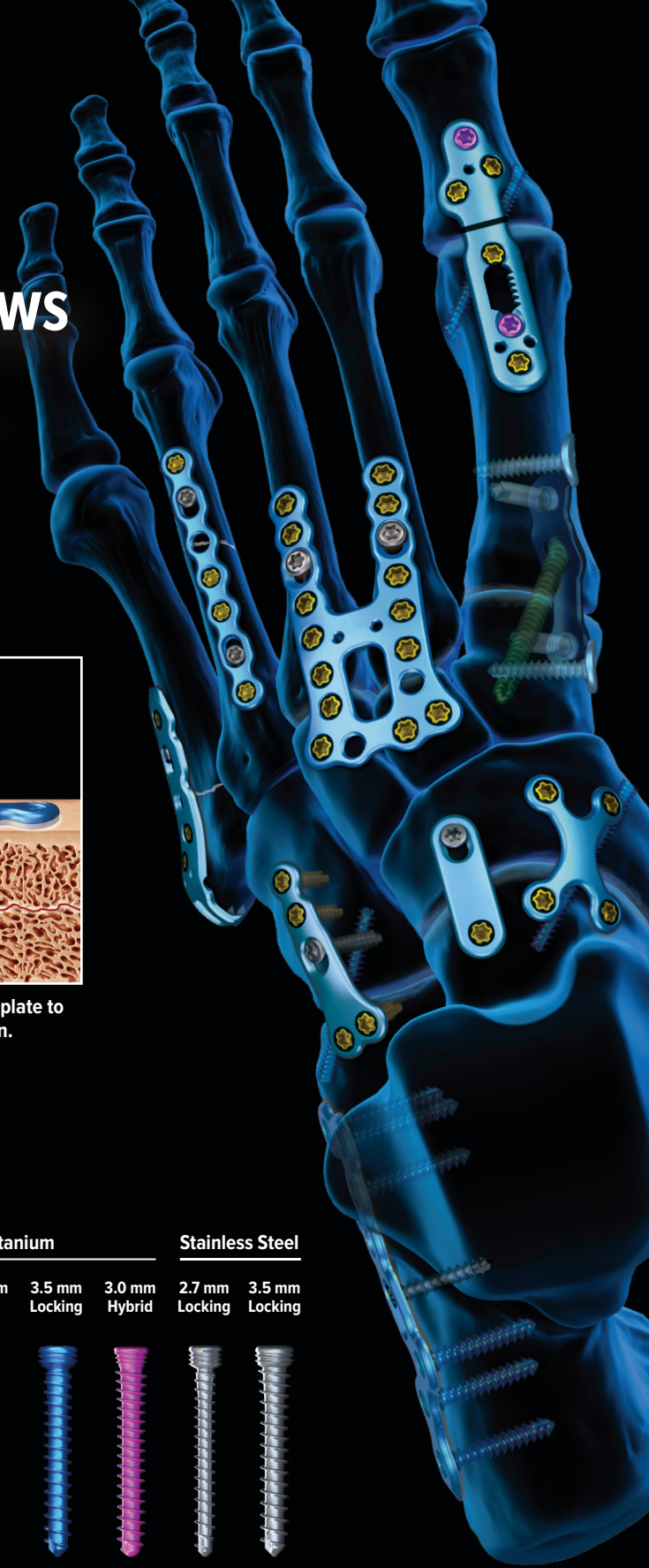
The titanium medial distal tibia hook plate is the perfect complement to its stainless counterpart. It is particularly useful in nickel-sensitive patients presenting with smaller or more complex medial malleolar fractures necessitating plate fixation. It additionally complements the titanium 2.4 mm Mini CFS plates, which I also routinely use for fracture fragment-specific fixation.

KreuLock™

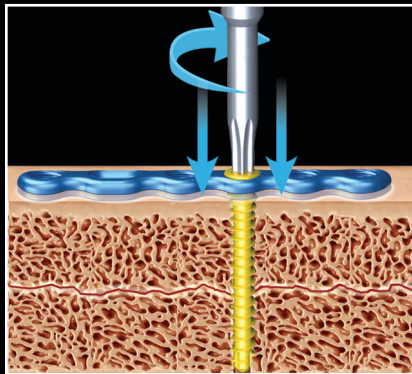
Locking Compression Screws

Arthrex is the first company to **combine locking and compression screw technology** together in one revolutionary screw design that **compresses bone fragments and the plate to bone during insertion.**

Multiple screw sizes and materials are compatible with the full range of low-profile, anatomic Arthrex titanium and stainless steel plates for every fracture and fusion indication.




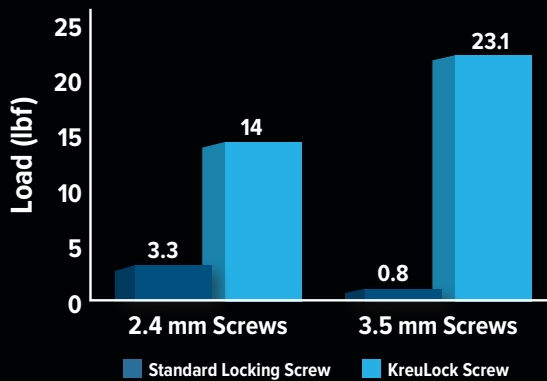
The thread pitch of the screw compresses bone fragments during insertion.



The screw also compresses the plate to bone during final insertion.

Up to 22+ lb of Additional Compression Compared to Regular Locking Screws

Maximum Compressive Strength^{1,2}



References

1. Arthrex, Inc. Data on file (APT-04100). Naples, FL; 2020.
2. Arthrex, Inc. Data on file (APT-04120). Naples, FL; 2020.

Case Report

MaxForce™ MTP Plates and KreuLock™ Locking Compression Screws



Christopher D. Kreulen, MD

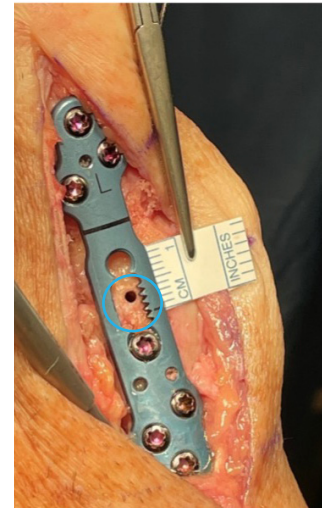Patient: 62-year-old male, type 2 diabetes and peripheral neuropathy.

Diagnosis: Arthritic bunion and 2nd hammertoe

Plan: 1st MTP fusion with MaxForce plate and KreuLock screws, calcaneus bone graft, 2nd hammertoe correction with DynaNite® FlexWire

Technique:

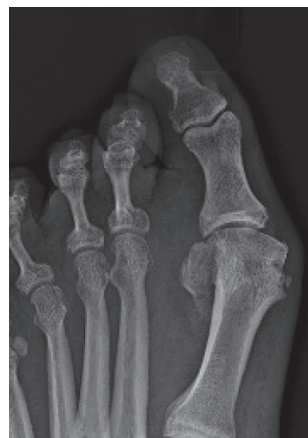- After standard soft-tissue release and joint prep, a bone graft is placed in the joint. To gain some length in the first ray, I stack two to three cores of calcaneus bone graft from the calcaneus bone graft harvester within the MTP joint prior to placing the pin and compressing.
- Place a 1.1 mm guide pin across the joint in position for placement of independent lag screw. Typical placement is medial proximal phalanx across joint to lateral metatarsal head.
- Align the plate using the joint line, insert BB-Taks, and confirm position on fluoroscopy. Place KreuLock screws distally to compress the MaxForce plate to the proximal phalanx. I recommend the 3 mm VAL Hybrid KreuLock screws for added screw purchase in the proximal phalanx. Next, drill for the compression device using the drill guide. Using two-finger tightness, turn the compression device clockwise, pulling the proximal phalanx to the metatarsal head. Insert a BB-Tak to hold the desired level of compression. Leave the compression driver in place and remove the handle. Then drill eccentrically in the oblong hole for further compression.
- **C.D.K. Pearl:** I use a KreuLock screw in the oblong hole. It will do an excellent job of engaging the plate and providing further compression of the joint and compress the plate to the bone to stabilize.
- Place 3 mm VAL Hybrid KreuLock screws in remaining holes to further stabilize the plate to the bone.



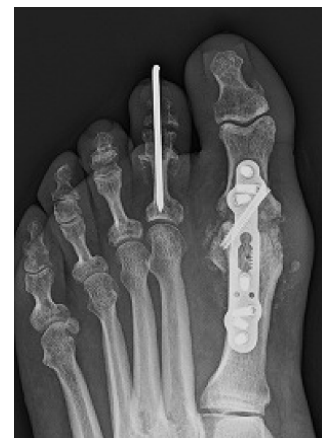3 mm-4 mm of travel with the compression device

Insights/Advantages:

The 3 mm VAL Hybrid KreuLock screws offer a 3 mm head with a 3.5 mm shaft screw for great bone purchase. The variable-angle locking head allows acute adjustments to optimize screw direction at each hole. KreuLock screws make the construct stronger since the plate is closer to the bone. KreuLock screws maximize the stability of the plate construct in concert with the MaxForce compression device to help maintain the compression achieved at the joint.



Pre-op



Post-op

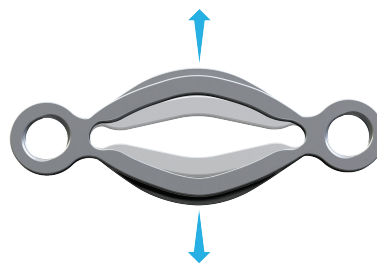
New Product Highlight

DynaNite® System: A Complete Portfolio of Continuous Compression


- **DynaNite Nitinol Staples**—Fast fixation and continuous compression¹



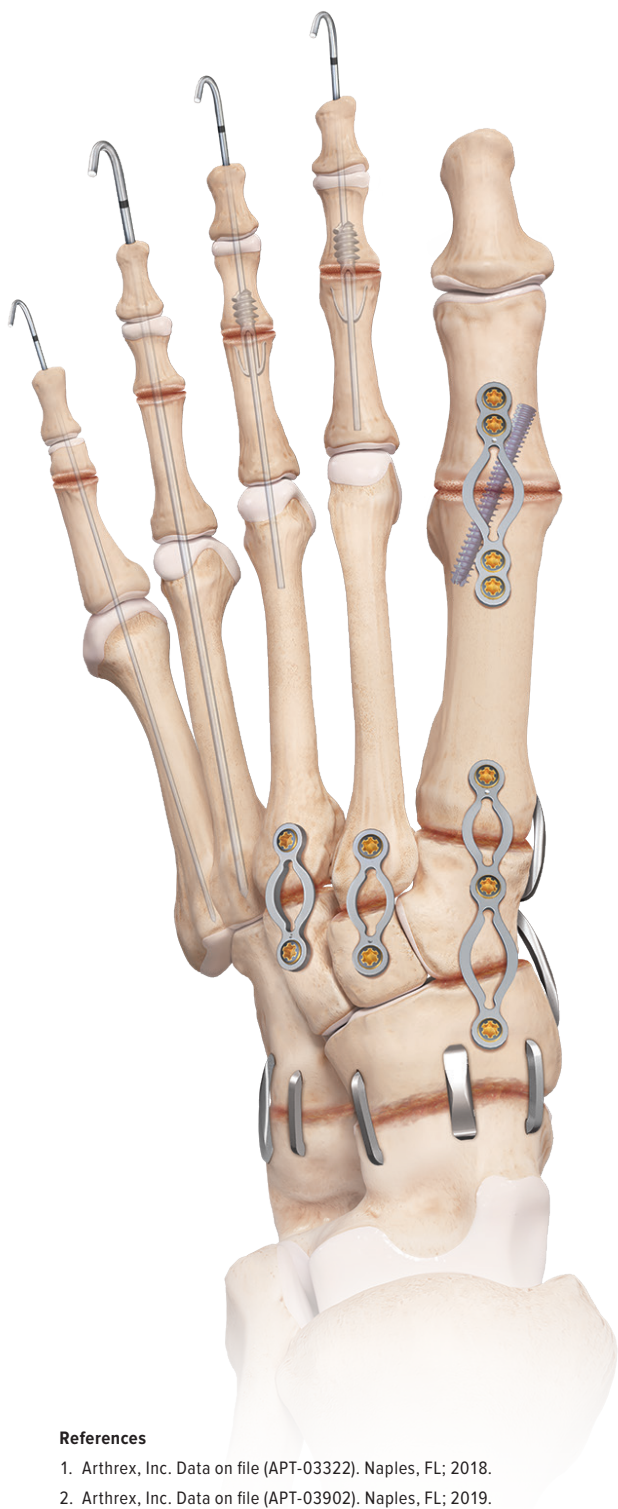
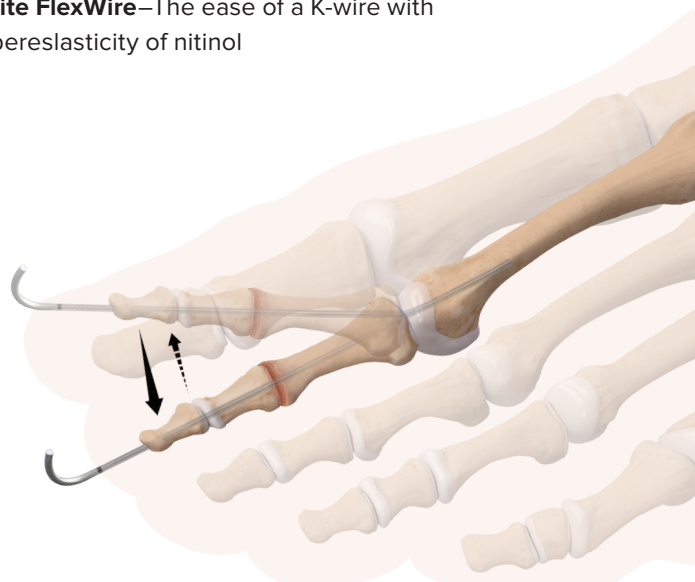
- **DynaNite Compression Plates**—Continuous compression of nitinol with stability of a plate²



- **DynaNite PIP**—The only threaded, cannulated, nitinol hammertoe implant



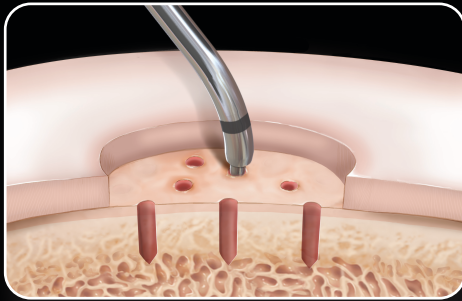
- **DynaNite FlexWire**—The ease of a K-wire with the superelasticity of nitinol



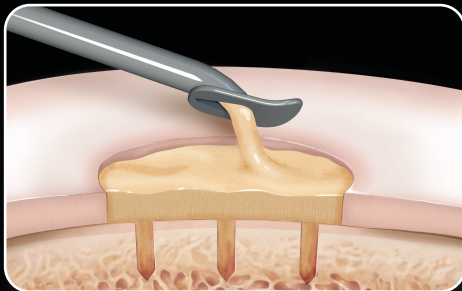
References

1. Arthrex, Inc. Data on file (APT-03322). Naples, FL; 2018.
2. Arthrex, Inc. Data on file (APT-03902). Naples, FL; 2019.

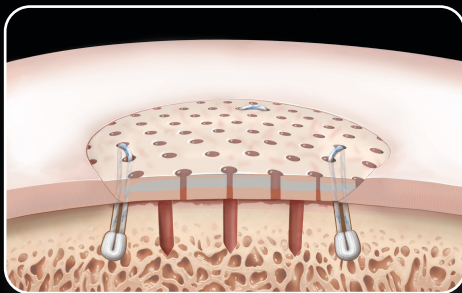
When You Treat Osteochondral Lesions . . . Think Arthrex.



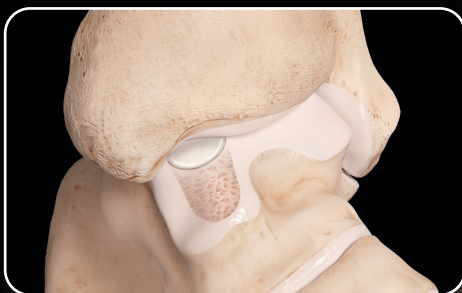PowerPick™ Device



BioCartilage® Extracellular Matrix



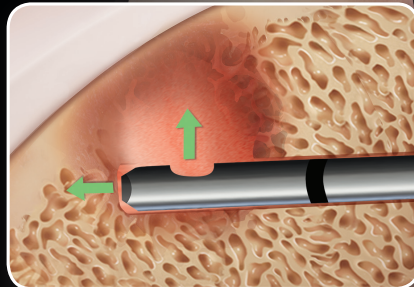
Cartiform® Viable Osteochondral Allograft



OATS® Kit and Fresh Precut OCA Cores

IntraOsseous BioPlasty® (IOBP) Surgical Technique

The IOBP® procedure is the biologic treatment for subchondral bone marrow lesions.



Arthrex®

Ad.Arthrex.com/IOBP

© 2019 Arthrex, Inc. All rights reserved.
AD1-000060-en-US_B

*Cartiform is a registered trademark of Osiris Therapeutics, Inc.

What's in My Bag?

Minimally Invasive Surgery

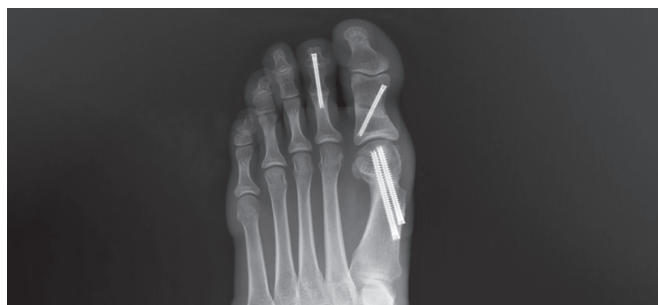

Jorge I. Acevedo, MD

How has adopting MIS techniques changed your practice?

Overall MIS bunion correction has been a complete game changer in terms of Improved patient satisfaction. I have patients coming in daily requesting smaller incision MIS bunion correction with shortened recovery times instead of the larger Lapiplasty®* incisions prolonging their return to regular footwear.

MIS has significantly changed my post-op protocol by allowing patients almost immediate weightbearing and quicker return to regular footwear.



What would you say to critics that advocate for Lapidus procedures in cases of hypermobility opposed to a distal osteotomy like in MIS bunion correction?

I believe MIS bunion surgery, like other well-studied open procedures, is equally effective when addressing the mild-to-moderate hypermobile joint. Prior to MIS, I performed roughly 30% Lapidus procedures, while today I do less than 10% in my practice. I reserve the Lapidus procedure mainly for very severe IM angles.

The triplanar correction achieved with the MIS transverse osteotomy deals with the fact that as the metatarsal head shifts medially in the transverse plane; it also rotates in the coronal plane, thus repositioning the metatarsal head over the sesamoids. This rectifies the musculo-ligamentous forces and lessens the propensity for recurrence.

*Lapiplasty is a registered trademark of Treace Medical Concepts, Inc.

References

1. Coughlin MJ, Jones CP. Hallux valgus and first ray mobility. A prospective study. *J Bone Joint Surg Am.* 2007;89(9):1887-1898. doi:10.2106/JBJS.F.01139
2. Coughlin MJ, Jones CP, Viladot R, et al. Hallux valgus and first ray mobility: a cadaveric study. *Foot Ankle Int.* 2004;25(8):537-44. doi:10.1177/107110070402500805

Have you had patients with a fusion on one foot and MIS on the other, and, if so, how do they compare?

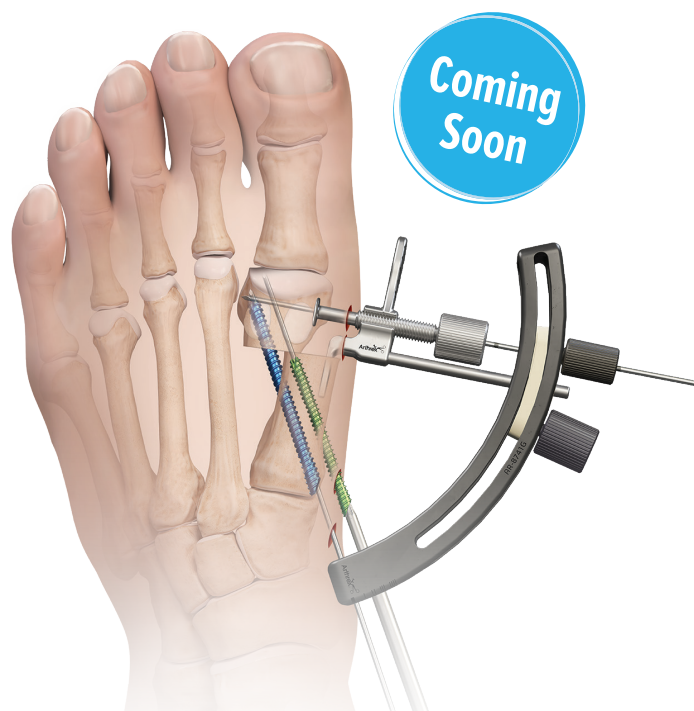Patients with contralateral fusions are far more dissatisfied with their lack of MTP mobility and restriction of footwear specifically when they have a contralateral MIS bunion correction to compare. Many women want to retain their motion when performing certain sports activities that require kneeling or demi-pointe positioning of the foot. They also prefer to not be limited to low (¾-inch) heels often required after a fusion. My happiest patients are those that have had a prior traditional open bunion on the contralateral side.

Have you had to do any revision cases with MIS? How are your results in revision cases using MIS?

MIS is ideal for revision surgery since incisional complications are minimized and existing hardware may not have to be removed. Patient satisfaction is drastically improved when these large incisions are avoided.

What's coming in the future?

Arthrex is launching an all-in-one guide that allows precision-controlled translation of the metatarsal head and optimal targeting of screws. The new beveled headless screws allow for minimal compression, avoiding over-correction once the metatarsal head is translated.



Navigate Tight Joint Spaces Like Never Before

NanoScope™ Operative Arthroscopy System

The smaller the joint space,
the greater the advantages.
The 2.2 mm NanoScope imaging
system replaces the traditional rod
lens arthroscope as the future of
less invasive operative arthroscopy.

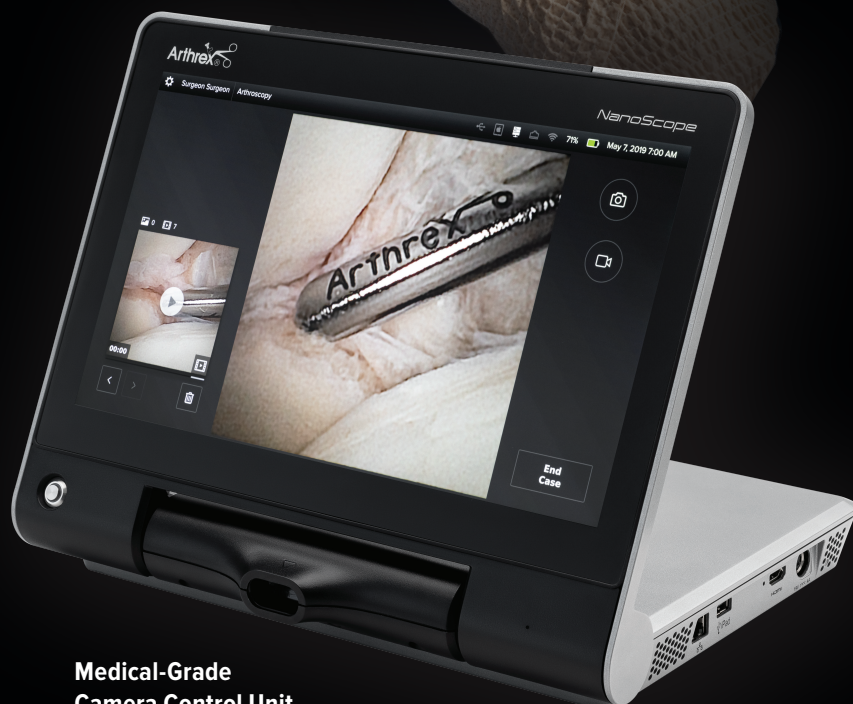Nano Arthroscopy
Shaver Handpiece

2.2 mm
NanoScope
Camera

2.7 mm Diameter
NanoCannula

2 mm Diameter NanoBiter Punch

Retractable NanoProbe



Medical-Grade
Camera Control Unit

Arthrex®

Revolutionizingarthroscopy.arthrex.com

Case Report

Comprehensive Minimally Invasive Treatment of a Distal Tibia Fracture With ArthroFx® External Fixation, FibuLock® Fibular Nail, Distal Tibia Plates, NanoScope™ System, and Orthobiologics



Christopher Hodgkins, MD

Distal tibia and pilon fractures are high-energy fractures and are frequently accompanied by complex fibular shaft fractures.

The goal of definitive treatment should be anatomic reductions, with stable, biomechanically appropriate fixation achieved with biology-respecting approaches using minimally invasive and arthroscopic techniques where appropriate. Even with well-intended and well-executed treatment, these injuries can still be associated with complications including wound healing issues and nonunions. Such devastating complications may be mitigated by considering the use of biologic products.

We present a case illustrating the use of our catalog of extensive and unique trauma and foot and ankle products allowing the comprehensive minimally invasive treatment of these highly complex injuries.

Case Presentation: A 50-year-old female patient was involved in a motor vehicle accident on a west coast vacation and sustained a closed displaced distal tibia and fibula fracture (Figure 1). She was initially closed reduced and stabilized in an ArthroFx external fixator (Figure 2) and transported back to the east coast for definitive treatment.

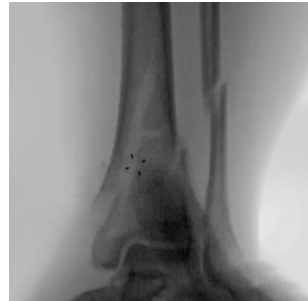

Figure 2

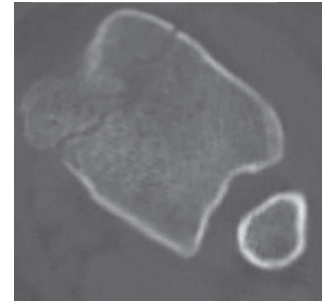


Figure 3

Surgical Planning and the Mini Open Fibula Nail:

A CT scan (Figure 3) of the external fixator was obtained to examine intra-articular involvement and to plan definitive fixation. The initial fracture mechanism, displacement, and pattern dictated that an anterolateral tibia plate would be the most biomechanically appropriate device. Such an approach often prohibits an extensile approach for fibula plate fixation; however, our preference to always perform minimally invasive fibula fixation with the FibuLock nail allows us free choice of surgical approach for the tibia (Figure 4). We will frequently place the minimally invasive fibula nail at the same time we place the ArthroFx device.

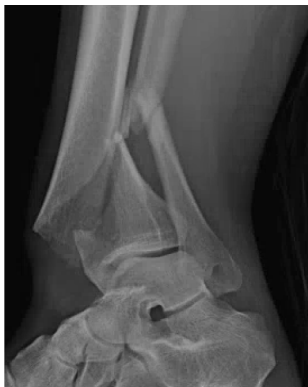

Figure 1

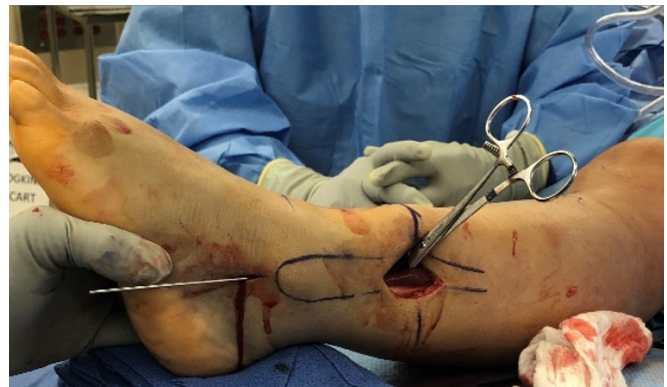
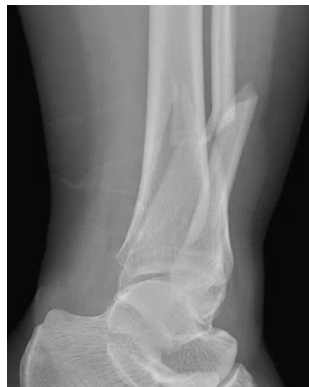
Figure 4

Case Report

Comprehensive Minimally Invasive Treatment of a Distal Tibia Fracture with ArthroFx® External Fixation, FibuLock® Fibular Nail, Distal Tibia Plates, NanoScope™ System, and Orthobiologics (Cont.)

Plate-Assisted Fibula Nailing: Reduction and stabilization of complex comminuted fibula shaft fractures can be very difficult using a plate or nail technique, particularly when there is no direct "clampable" anatomic key between the two main fragments. We have employed a plate-assisted technique that simplifies this process. We initially advance the guidewire across the comminution to engage and grossly reduce and align the main proximal and distal fragments of the fibula. A 2 mm Mini CFS plate is then applied to one of the two fragments with a unicortical locking screw. The reduction is manipulated and fine-tuned using the comminuted pieces to gauge length and rotation reduction. Once this is confirmed and held, an assistant can secure the other end of the plate with another unicortical screw (Figure 5). The anatomic reduction is now held securely throughout the rest of the nail procedure. We often leave this plate in situ. It is important to note that this plate can still be placed through the same mini incision.

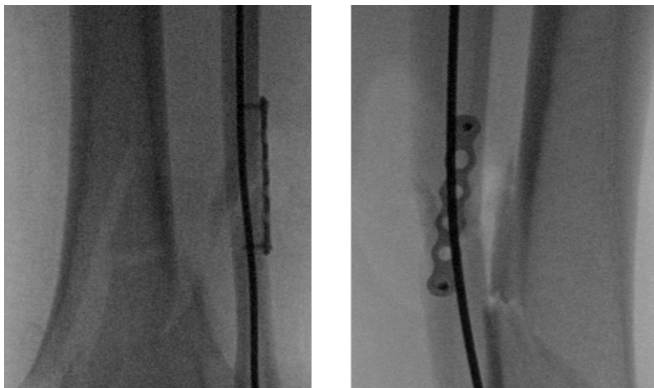


Figure 5

Tibial Fixation, NanoScope System, and TightRope® XP Fixation: The tibia plate was also placed through a mini open approach as you can see from the intraoperative pictures (Figure 6). There was minimal intra-articular involvement in this case; however, we used the NanoScope visualization system (Figure 7). We employ this system liberally in the treatment of more complex intra-articular fractures to aid in and confirm reduction and to document articular damage. We also stabilized the syndesmotomic injury with a TightRope XP construct.

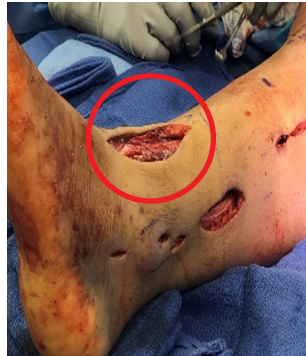

Figure 6

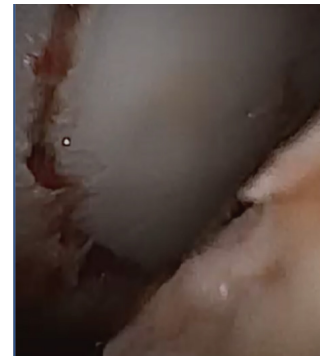


Figure 7

Add Orthobiologics to Decrease Complications: We are continually frustrated by the potential for delayed or nonunion in these complex injuries and therefore we employ the use of ArthroCell™ bone grafts in an attempt to fill bone voids and stimulate healing at the primary fracture line. Anatomic reductions mean little in the setting of a nonunion; thus, given the devastating consequences of these complications, we have a very low threshold to add a biologic advantage. We also use the JumpStart® antimicrobial wound dressing to assist with wound healing.

Final Result: Postoperative radiographs (Figure 8) demonstrate the comprehensive but minimally invasive management of these complex injuries using unique products and techniques with the addition of orthobiologics to treat these injuries better.

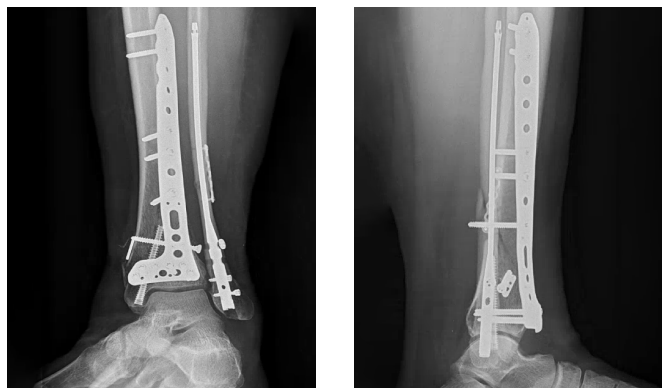


Figure 8

What's in My Bag?

Collagen-Coating Difference Using the *Internal/Brace*™ Surgical Technique



Anish R. Kadakia, MD

You have been using *Internal/Brace* surgical technique to support your primary ligament repairs for 5+ years; can you see the differences in your clinic and patient results before and since using the technology?

The difference in the clinical outcome is distinct before and after using the *Internal/Brace* procedure. Prior to this technique, the outcome following a standard Brostrom reconstruction was unpredictable, with many patients having recurrent mechanical instability and, although moderately clinically improved with improvement in ADLs, many had to modify athletic activity to avoid instability.

I routinely employed the use of allograft and non-anatomic reconstruction for difficult cases and revision cases. Since the use of augmentation with the *Internal/Brace* technique, that I initially used only for revision, the clinical reproducibility with regards to the mechanical stability has led me to consider this the standard for my reconstructions. My patients universally note the improvement in the stability of the ankle and most are able to return to high-level sport without the use of a brace. My failure rate has decreased significantly, and I have been able to successfully reconstruct patients with a known history of Ehlers-Danlos syndrome without the need for graft; that was not possible prior to this technology.

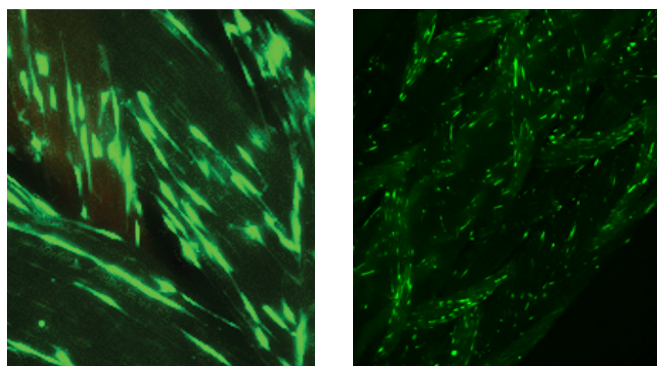


Figure 1. LIVE/DEAD-stained tenocytes adhered to collagen-coated FiberTape® suture. Living cells appear green while dead cells appear red.

How has *Internal/Brace* surgical technique changed the way you treat soft-tissue injuries?

Initially, when introduced to the *Internal/Brace* surgical technique, the thought was this technology was primarily useful for reconstruction in chronic lateral ankle and spring ligament injuries. The excellent clinical results, both in the stability and reproducibility of the outcome, have led to me to understand that the *Internal/Brace* surgical technique allows for superior soft-tissue healing without elongation. I have used this technique for acute turf toe, hallux varus, revision hallux valgus, 1st TMT acute Lisfranc stabilization, and 2nd metatarsal to medial cuneiform Lisfranc stabilization, with a high success rate with regards to patient satisfaction and radiographic outcomes. I have been able to treat patients with motion-sparing reconstructions that prior to the use of the *Internal/Brace* surgical technique required an arthrodesis or had a high failure rate and recurrence of deformity. This technology has truly allowed me to achieve outcomes that were not possible previously and has been a tremendous boon for my patients.

The *Internal/Brace* surgical technique is intended only to support the primary repair/reconstruction and is not intended as a replacement. The *Internal/Brace* surgical technique is intended only for soft tissue-to-bone fixation and is not cleared for bone-to-bone fixation.

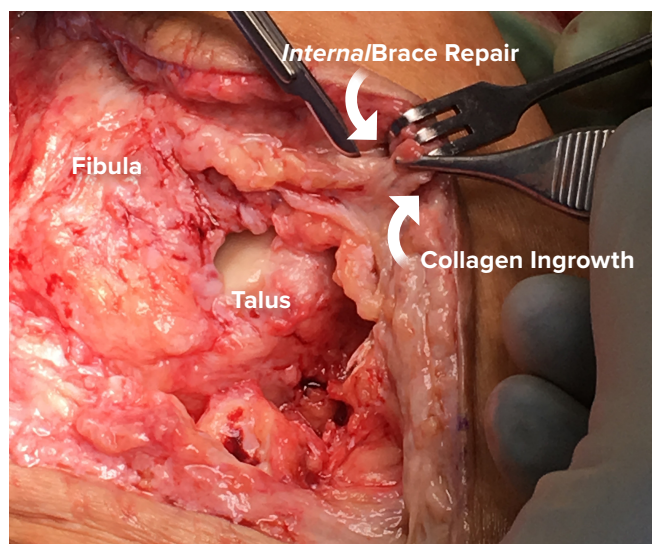
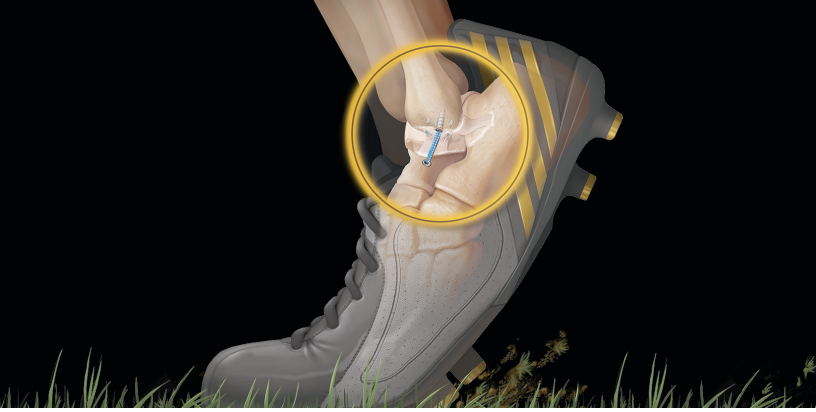

Figure 2. Collagen ingrowth.

What's in My Bag?

Collagen-Coating Difference Using the *Internal/Brace*™ Surgical Technique (Cont.)



Where have you applied *Internal/Brace* and can you provide anything you have learned?

Lateral ligament repair is perhaps the most common use of the *Internal/Brace* surgical technique, that seems straightforward on paper; however, I have learned some tips to facilitate the execution of the procedure. Use of electrocautery to mark out the placement of the FiberTak® anchors and the 3.5 mm SwiveLock® anchor for the fibula minimizes the risk of having the tunnels intersect and lose fixation. Tensioning in all cases for me is easiest when the joint is held in a position where the ligament should be taut. For the ATFL, I hold the ankle in 15° of plantar flexion and tension the FiberTape® sutures at that position. This technique has led to reproducible stability without any resultant loss of physiologic plantar flexion. The cannulated system that is now available has minimized the risk of errant drill or tap placement and has made the technique much easier. The added time of using a K-wire is minimal compared to an inappropriately placed drill tunnel and I would recommend using the cannulated system when initially performing this technique or when the bone is convex or covered in soft tissue.

Reference

1. Arthrex, Inc. Data on file (APT-05060). Naples, FL; 2021.

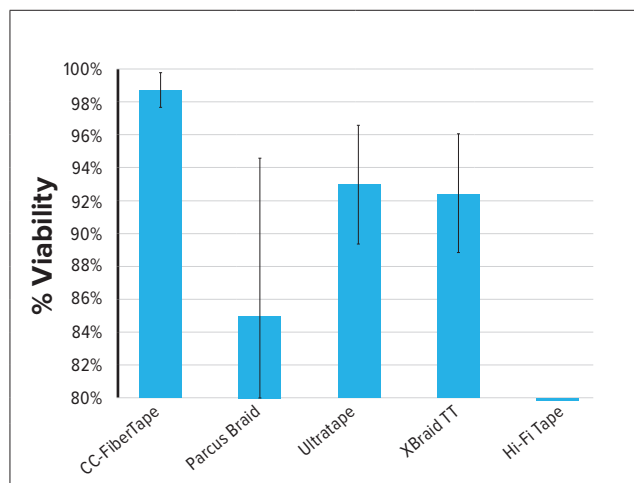


Figure 3. Viability of adhered human tenocytes.¹

Can you discuss the benefits of collagen-coated FiberTape® for your patients?

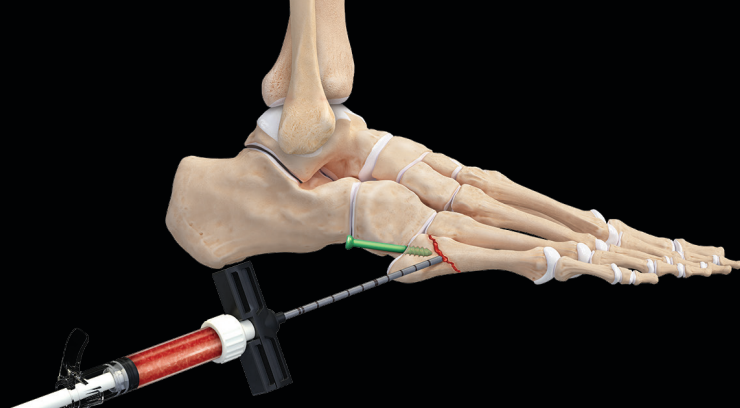
Having experience with revision surgery, I would state with confidence that other nonabsorbable tissue does not integrate into the native soft tissue. We all have the experience of seeing a knot from a prior reconstruction and pulling on it resulting in the length of the suture pulling out through the tissue. When I have had to revise an *Internal/Brace* repair, rare as that may be, the entire area of the repair is covered in collagen and does not separate from the soft tissue. This has been the experience of other surgeons as well. The reconstruction not only allows the native tissue to heal, but the collagen coating also acts as a scaffold to guide healing of the new tissue both in volume and length. Other materials don't encourage collagen growth and, in some cases, even result in an inflammatory reaction and inhibit collagen formation that may compromise the strength of the ultimate repair.

What were your findings in the R&D on commercially available "tapes"?

We performed an in vitro study to evaluate both the tenocyte adhesion in addition to the viability with *Internal/Brace* repair and the other competitive brands attempting to simulate the efficacy of the *Internal/Brace* repair. The data was clear that tenocyte adhesion was superior with the collagen-coated FiberTape suture, but more importantly, that tenocyte viability was highest when the cells were placed adjacent to the collagen-coated FiberTape suture. When taking this in vitro data and applying it to the clinical scenarios that we encounter, there is no question that the collagen-coated FiberTape suture allows for the best biologic environment for collagen formation for ligament reconstruction in addition to excellent mechanical stability. These are the dual components that are needed for soft-tissue reconstruction and are best achieved with the collagen-coated FiberTape suture.

New Product Highlight

Biologic Augmentation in Foot and Ankle



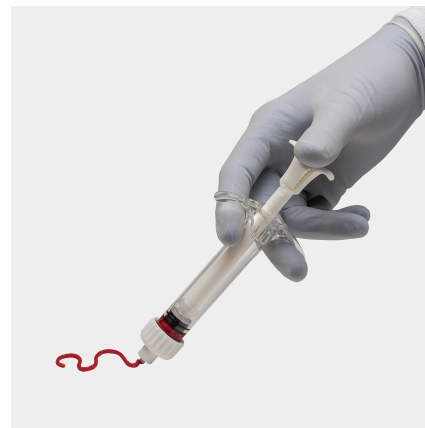
AlloSync™ Pure Demineralized Bone Matrix

AlloSync Pure is a dehydrated osteoinductive demineralized bone matrix (DBM) derived from 100% human allograft bone with no extrinsic carriers. Our proprietary demineralization process preserves native bone morphogenetic proteins (BMPs) and growth factors essential to osteoinductivity.

AlloSync Pure bone matrix resists irrigation and can be used in a fluid environment. The clinician can control the handling properties of AlloSync Pure bone matrix, which includes decreasing the viscosity for injectable applications or increasing the viscosity to create a moldable putty.

The proprietary rice-shape fiber technology used to process AlloSync Pure increases the osteoinduction and osteoconductive surface area to accelerate cellular ingrowth. AlloSync Pure may be hydrated with bone marrow concentrate (BMC), platelet-rich plasma (PRP), blood, saline, or other cellular components.

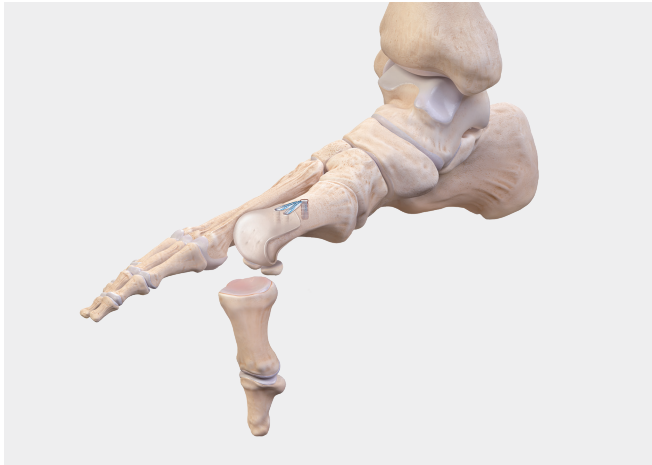AlloSync Pure is a great option that is provided in a ready-to-use mixing jar in four different sizes, sterilized to device-grade standards (10^{-6}) and stored at ambient temperatures. AlloSync Pure can be used in a variety of fracture and fusion cases in conjunction with our current fracture and fusion offerings. For more information, please reach out to your local agency's orthobiologics manager or specialist or refer to the Arthrex.com website to learn more about our biologic portfolio.



What's in My Bag?

Biologic Augmentation in Foot and Ankle

ArthroFLEX®* Dermal Allograft for 1st MTP Hallux Rigidus Arthroplasty



Osteoarthritis of the 1st metatarsophalangeal (MTP) joint is the most common arthritic condition in the foot, affecting 1 in 40 people over the age of 50.¹ Progression of great toe arthritis is associated with pain and loss of motion. ArthroFlex dermal allograft is a protective bioimplant that allows patients to retain the ability to move the MTP joint without the need for fusion.

Treatment options are limited for young and active patients with hallux rigidus of the 1st MTP joint, especially if they are seeking a motion-sparing procedure. Interpositional arthroplasty is a safe and effective alternative to fusion that uses ArthroFlex, a human acellular dermal tissue matrix, as a spacer.⁵⁻⁸ Because interpositional arthroplasty preserves more bone, joint motion and stability, as well as length, the overall function of the 1st MTP joint is conserved.²

Why use ArthroFLEX dermal allograft?

- ArthroFlex is a biohospitable acellular dermal extracellular matrix intended for supplemental support and covering of soft-tissue repair
- The graft can be stored at room temperature fully hydrated with a 3-year shelf life
- Biomechanical testing has shown that ArthroFlex dermal allograft provides high ultimate load and suture retention strength³
- ArthroFlex dermal allograft has demonstrated the ability to remodel and integrate with host tissue after implantation⁴


*ArthroFLEX is a registered trademark of LifeNet Health.

References

1. Lam A, Chan JJ, Surace MF, Vulcano E. Hallux rigidus: How do I approach it? *World J Orthop.* 2017 May 18;8(5):364-371. doi: 10.5312/wjo.v8.i5.364. PMID: 28567339; PMCID: PMC5434342.
2. Aynardi MC, Atwater L, Dein EJ, et al. Outcomes after interpositional arthroplasty of the first metatarsophalangeal joint. *Foot Ankle Int.* 2017;38(5):514-518. doi:10.1177/1071100716687366
3. Arthrex, Inc. Data on file. Biomechanical properties of tendon augmentation material. LA0822-EN, TR-4926. Naples, FL; 2011
4. Hartzler RU, Softic D, Qin X, et al. The histology of a healed superior capsular reconstruction dermal allograft: a case report. *Arthroscopy.* 2019;35(10):2950-2958. doi:10.1016/j.arthro.2019.06.024
5. Vulcano E, Chang AL, Solomon D, Myerson M. Long-term follow-up of capsular interposition arthroplasty for hallux rigidus. *Foot Ankle Int.* 2018;39(1):1-5. doi:10.1177/1071100717732124
6. Patel HA, Kalra R, Johnson JL, et al. Is interposition arthroplasty a viable option for treatment of moderate to severe hallux rigidus? - A systematic review and meta-analysis. *Foot Ankle Surg.* 201;25(5):571-579. doi:10.1016/j.fas.2018.07.006
7. Hyer CF, Granata JD, Berlet GC, Lee TH. Interpositional arthroplasty of the first metatarsophalangeal joint using a regenerative tissue matrix for the treatment of advanced hallux rigidus: 5-year case series follow-up. *Foot Ankle Spec.* 2012;5(4):249-252. doi:10.1177/1938640012443285
8. Mackey RB, Thomson AB, Kwon O, Mueller MJ, Johnson E. The modified oblique keller capsular interpositional arthroplasty for hallux rigidus. *J Bone Joint Surg Am.* 2010;92(10):1938-46. doi: 0.2106/JBJS.1.00412

What's in My Bag?

Plantar Plate Repair



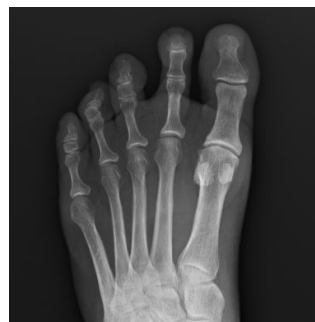David Macias, MD

Since its release in 2012, the CPR™ system continues to be the industry-leading direct plantar plate repair system addressing crossover toe and floating toe pathology. How has it changed your practice and patient outcomes?

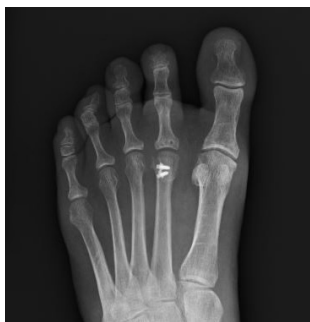I think that the Arthrex CPR system has been a game changer in terms of treatment of forefoot pathology. Frequently, patients will come to me for a second opinion after being treated for a Morton's neuroma or being diagnosed with metatarsalgia, when they really have instability of the lesser MTP joints. Being able to address the cause of that instability directly, I believe, has led to better outcomes for my patients. Repairing the plantar plate has been shown to give superior results to Weil osteotomy alone, even for low-grade tears.¹ If patients fail conservative treatment for plantar plate tears, my procedure of choice is the plantar plate repair regardless of the grade of the tear.

Indirect repair of plantar plate via a metatarsal head osteotomy and pin fixation across the MTP is considered an alternative for treating plantar plate injuries. Why do you continue to choose to directly repair the tissue with the CPR system?

Multiple studies have shown that the plantar plate is crucial to the stability of the lesser MTP joints.¹⁻⁷ Isolated Weil osteotomy and pin fixation does not address the cause of instability and can often lead to dorsal contracture.² How can you restore stability if you do not address the cause? Direct repair of the plantar plate using the CPR system allows me to restore stability to the lesser MTP joint, thus preventing some of the known complications of isolated Weil osteotomies such as the floating toe and transfer metatarsalgia.



Pre-op



Post-op

Plantar plate injury can range from attenuated tissue, to a partial tear off the phalanx, up to completely unhealthy tissue. How do you address this range of pathology?

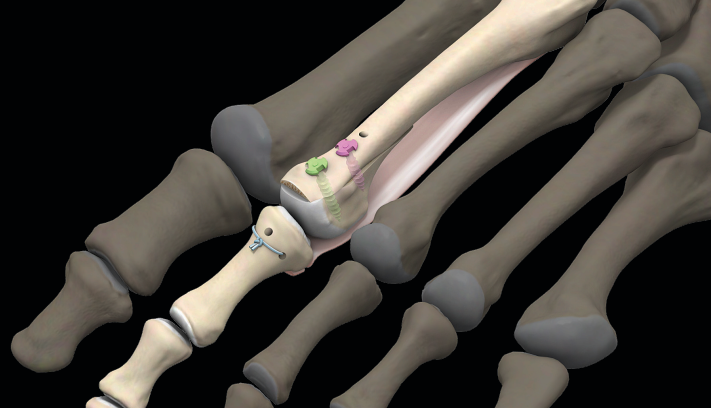
For patients with a painful drawer of the lesser MTP joint but no instability, I start with conservative treatments of offloading the joint, anti-inflammatory medications, taping the toe, and plantar flexion exercises. If patients fail conservative treatment, then I think they are candidates for plantar plate repair. The Arthrex CPR system has multiple different passers for getting the sutures through the plantar plate, including the Scorpion™, Viper™, and pig-tail passers. Having these options allows me to place my sutures in healthy tissue regardless of the nature of the tear or the working space in the joint. I will often use more than one type of passer for the same plantar plate repair. Using this system, I have only rarely been unable to get enough healthy tissue for repair. In these instances where there is simply no tissue available (usually from multiple joint injections or inflammatory arthropathies), a non-anatomic reconstruction such as with SutureTape per the *Internal/Brace*™ technique is indicated.

There is an underlying perception in forefoot surgery that some patients are unsatisfied after undergoing a plantar plate repair. What has your experience been?

I would say that if anything my experience has been the opposite—my patients who undergo plantar plate repair are very satisfied after the procedure. As with all surgeries, making sure that your goals are aligned with the patient's goals is of utmost importance. My objectives for plantar plate repairs are to decrease pain, improve toe purchase into the ground, and improve function. I have been using the CPR system for almost 6 years now and found that on average I have been able to achieve those goals. Directly repairing the plantar plate restores the normal stability of the lesser MTP joint, which cannot be achieved by pinning the joint alone. Recently, it has been shown that Weil osteotomy combined with direct repair of the plantar plate leads to improved outcomes when compared to Weil osteotomy alone for treatment of metatarsalgia.¹

What's in My Bag?

Plantar Plate Repair (Cont.)



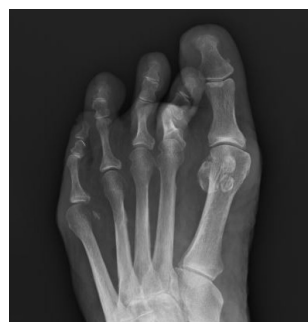Lack of working space is a challenge and at times a source of frustration in plantar plate repair. Are there any strategies you have found helpful since starting the use of the CPR™ system?

Achieving good suture position into the plantar plate can certainly be challenging, but with the tools provided in the CPR system, it can be quite smooth. I think the number one thing is to be familiar with all three passers in order to use the one that best fits the anatomy. I may use two different passers on the same suture, just depending on where I'm trying to place it. When using the Scorpion™ suture passer, make sure that once you have your bite, you rotate your hand prior to deploying the needle. This maneuver will help avoid being blocked by the metatarsal head or getting the needle caught in the soft tissue. I perform a Weil osteotomy for the majority of my plantar plate repairs, which increases the working space as well. You can shift the metatarsal head back quite a bit while performing the repair and then bring it back into a more anatomic position prior to fixation in order to better visualize the plantar plate.

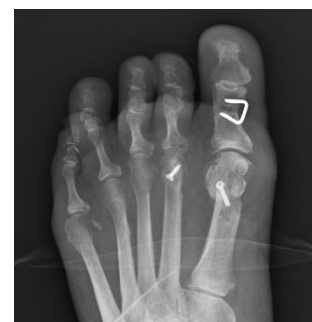Higher recurrence rates are often quoted in forefoot surgery in comparison to other foot procedures. Could you describe your post-op protocol and provide any tips/pearls that can help lead to more satisfactory patient outcomes and long-term success?

Numerous studies have shown that direct repair of the plantar plate has led to significantly improved outcomes and decreased pain at 1 year,^{4,5} and I have found similar results in my patients. When I tie my knots, it is very important to make sure I have all the slack out first, as often the suture can be caught at the entrance to the bone tunnel. I take my time to make sure my assistant is holding the MTP joint reduced, and plantar flexed 20 to 30 degrees in order to ensure toe purchase into the ground. These two steps are crucial to avoid a floating toe. For my Weil osteotomy, I do like to take a small dorsal wedge to better realign the center of rotation of the metatarsal head. When using the McGlamry elevator, I only release as much of the plantar plate as necessary to pass my sutures. I avoid releasing it completely as I did in the past, and I think this has led to less scarring and stiffness.

The postoperative protocol is crucial to success for these patients. I get these patients moving as soon as possible with passive and active range of motion exercises at home. At 3 weeks, all my patients begin physical therapy to focus on plantar flexion strengthening. I protect them with a hard-soled shoe and taping or a commercial toe splint for 6 weeks, and then transition them to supportive tennis shoes. I believe moving these joints early results in less stiffness and better results, and I'm confident in doing so because of the quality of my repair using the CPR system.



Pre-op



Post-op

References

1. Fleischer AE, Klein EE, Bowen M, McConn TP, Sorensen MD, Weil L Jr. Comparison of combination Weil metatarsal osteotomy and direct plantar plate repair versus Weil metatarsal osteotomy alone for forefoot metatarsalgia. *J Foot Ankle Surg.* 2020;59(2):303-306. doi: 10.1053/j.jfas.2019.08.023
2. Trnka HJ, Nyska M, Parks BG, Myerson MS. Dorsiflexion contracture after the Weil osteotomy: results of cadaver study and three-dimensional analysis. *Foot Ankle Int.* 2001;22(1):47-50. doi:10.1177/107110070102200107
3. Johnston RB 3rd, Smith J, Daniels T. The plantar plate of the lesser toes: an anatomical study in human cadavers. *Foot Ankle Int.* 1994;15(5):276-282. doi:10.1177/107110079401500508
4. Flint WW, Macias DM, Jastifer JR, et al. Plantar plate repair for lesser metatarsophalangeal joint instability. *Foot Ankle Int.* 2017;38(3):234-242. doi:10.1177/1071100716679110
5. Nery C, Coughlin MJ, Baumfeld D, Mann TS. Lesser metatarsophalangeal joint instability: prospective evaluation and repair of plantar plate and capsular insufficiency. *Foot Ankle Int.* 2012;33(4):301-311. doi:10.3113/FAI.2012.0301
6. Doty JF, Coughlin MJ. Metatarsophalangeal joint instability of the lesser toes and plantar plate deficiency. *J Am Acad Orthop Surg.* 2014;22(4):235-245. doi:10.5435/JAAOS-22-04-235
7. Deland JT, Lee KT, Sobel M, DiCarlo EF. Anatomy of the plantar plate and its attachments in the lesser metatarsal phalangeal joint. *Foot Ankle Int.* 1995;16(8):480-486. doi:10.1177/107110079501600804

Distal Extremities Medical Education

Course Schedule

Upcoming Medical Education Events

Date	Course Name	Location
2021		
August 20-21	Controversies in Foot and Ankle Surgery	Naples, FL
August 23	Foot and Ankle Minimally Invasive Surgery Course	Naples, FL
October 15-16	Foot and Ankle Orthopedic Technology and Innovation Forum	Naples, FL
November 8	Foot and Ankle Minimally Invasive Surgery Course	Naples, FL
2022		
January 28-29	East Coast Foot and Ankle Summit	Naples, FL
January 31	Foot and Ankle Minimally Invasive Surgery Course	Naples, FL
March 12	Foot and Ankle Minimally Invasive Surgery Course	Naples, FL
May 16	Foot and Ankle Minimally Invasive Surgery Course	Naples, FL



Foot and Ankle MIS Course



East Coast Foot and Ankle Summit

This is not medical advice and Arthrex recommends that surgeons be trained in the use of any particular product before using it in surgery. A surgeon must always rely on their own professional judgment when deciding whether to use a particular product when treating a particular patient. A surgeon must always refer to the package insert, product label, and/or directions for use before using any Arthrex product. Products may not be available in all markets because product availability is subject to the regulatory and medical practices in individual markets. Please contact your Arthrex representative if you have questions about the availability of products in your area.

arthrex.com

© 2021 Arthrex, Inc. All rights reserved. LN1-000355-en-US_A